

A New Attempt to Treat Compound Atrophic Acne Scars

Jie Lin*, Dan Wang

Department of Medical Cosmetology, Hebei General Hospital, Shijiazhuang, China

DESCRIPTION

Atrophic acne scars are divided into three types: Rolling, boxcar and ice-pick subtypes. Most patients have two or three types at the same time. There are many ways to treat atrophic acne scars, and the effect has its own merits. Laser treatment has become the standard for atrophic acne scar treatment [1]. Single laser mode cannot satisfy the treatment of compound atrophic acne scars, as a result, the disease treatment presents the characteristics of many times, long cycle and expensive. Then in the laser treatment of compound atrophic acne scars, can we have a new attempt? Our center combined use of CO₂ laser artificial fractional mode +2940 nm erbium laser single spot mode +2940 nm erbium laser fractional mode treatment of compound atrophic acne scars achieved satisfactory results. Then we will show how we solve the problem of multiple atrophic acne scars through two clinical studies and a three-step treatment video combining multiple laser modalities (Figures 1 and 2).

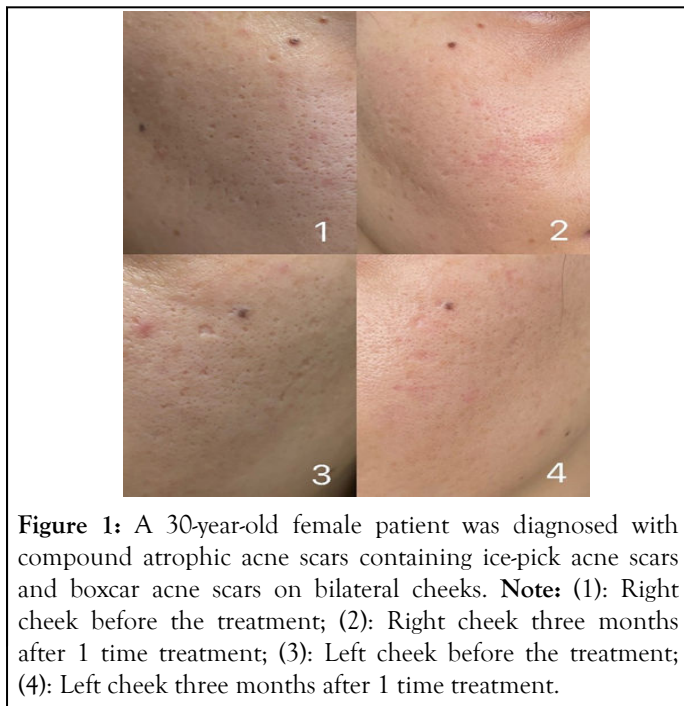


Figure 1: A 30-year-old female patient was diagnosed with compound atrophic acne scars containing ice-pick acne scars and boxcar acne scars on bilateral cheeks. **Note:** (1): Right cheek before the treatment; (2): Right cheek three months after 1 time treatment; (3): Left cheek before the treatment; (4): Left cheek three months after 1 time treatment.

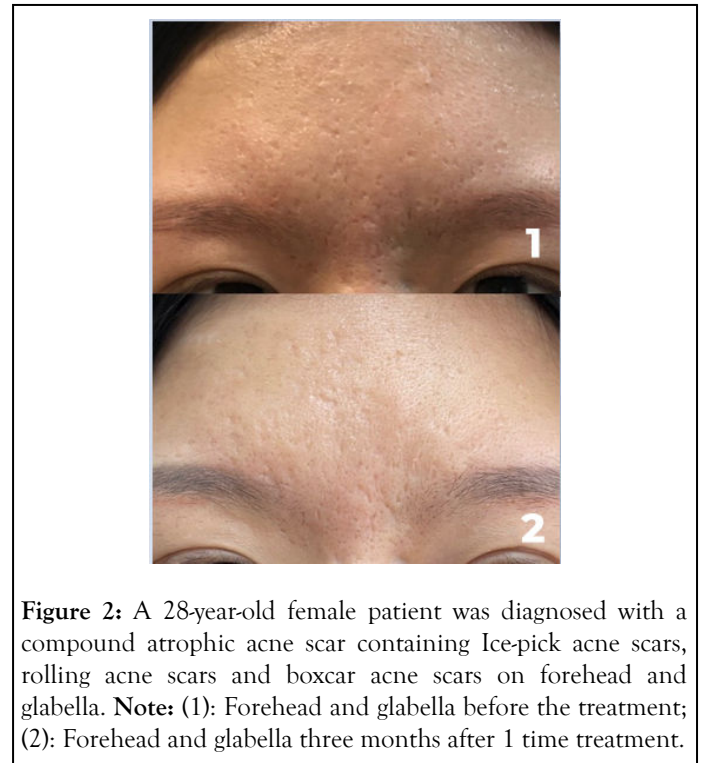


Figure 2: A 28-year-old female patient was diagnosed with a compound atrophic acne scar containing Ice-pick acne scars, rolling acne scars and boxcar acne scars on forehead and glabella. **Note:** (1): Forehead and glabella before the treatment; (2): Forehead and glabella three months after 1 time treatment.

Both patients felt that acne scars affected social interaction and life, and they had urgent desire for treatment. A single laser mode cannot achieve a better treatment effect at one time, and the combination treatment of multiple laser types and multiple laser output modes can significantly improve the one-time treatment effect. 5% compound lidocaine cream was externally applied to the treatment site of the two patients, and wrapped with plastic wrap for 30 minutes. Before treatment, the lidocaine cream was removed, alcohol was disinfected twice, and dry and clean cotton swab was wiped once.

In the first step, SPLB-200A CO₂ laser of Jingyu Laser Company of China was used. The treatment parameters were wavelength 10600 nm, output mode: Pulse mode, output energy: 60-89 mJ, spot diameter 1 mm, frequency 20-29 Hz, artificial lattice density: Hole spacing \geq 1.5 mm [2]. The setting of each specific parameter

Correspondence to: Jie Lin, Department of Medical Cosmetology, Hebei General Hospital, Shijiazhuang, China, E-mail: linjie_lynn@163.com

Received: 28-Oct-2024, Manuscript No. JCEDR-24-32966; **Editor assigned:** 30-Oct-2024, PreQC No. JCEDR-24-32966 (PQ); **Reviewed:** 13-Nov-2024, QC No. JCEDR-24-32966; **Revised:** 20-Nov-2024, Manuscript No. JCEDR-24-32966 (R); **Published:** 27-Nov-2024, DOI: 10.35841/2155-9554.24.15.677.

Citation: Lin J, Wang D (2024) A New Attempt to Treat Compound Atrophic Acne Scars. J Clin Exp Dermatol Res. 15:677.

Copyright: © 2024 Lin J, et al. This is an open-access article distributed under the terms of the Creative Commons Attribution License, which permits unrestricted use, distribution, and reproduction in any medium, provided the original author and source are credited

is adjusted according to the scar depth and color. Small and deep ice-pick acne scars were treated with single-hole artificial lattice at the center, rolling acne scars and boxcar acne scars were treated with multi-hole artificial lattice at the depressed parts.

In the second step, the erbium laser microablation mode (Single Spot™) of profile super platform multifunctional laser treatment system produced by Sciton company in the United States of America is adopted, the wavelength is 2940 nm, the output mode is pulse mode, the energy density is 20-25 J/cm², the spot diameter is 2 mm, and the frequency is 3-4 Hz [3]. During the treatment, the spot shape was round, the diameter of the spot was 2-3 mm, and the edge of the acne scar was disk-shaped ground until smooth.

The third step uses erbium laser lattice mode (Fractional Resurfacing™), wavelength 2940 nm, output mode: Lattice mode, energy density: 150-200 J/cm², lattice coverage 5%, spot size 5-7 aim, treatment speed 1 Hz. Treatment area: plain scan of all acne scar areas. Medical recombinant collagen excipient (Kefumei) was applied immediately after surgery for ice application for 30 min, and then Recombinant bovine basic Fibroblast Growth Factor (Rb-bFGF) gel was applied externally twice a day for 1 week [4]; medical recombinant collagen excipient (Kefumei) was continuously applied once a day for 3 days after laser surgery; the patient was instructed not to touch raw water for 5 days, Wait for the natural scab to fall off, and pay attention to moisturizing and sun protection.

CONCLUSION

CO₂ artificial fractional laser can reach bottom and steep edges of scars due to its strong penetrating ability, especially for ice-pick acne scars, which are small and deep and refractory. 2940 nm erbium laser single spot mode +2940 nm erbium laser fractional mode is effective for both box and roller models. The combination of the three treatment methods covers the requirements of three types of complex acne scars, improves the one-time treatment effect, shortens the treatment cycle, reduces the treatment pain of patients and reduces the treatment cost. In conclusion, we believe that this laser combination therapy has a potential future.

REFERENCES

1. You HJ, Kim DW, Yoon ES, Park SH. Comparison of four different lasers for acne scars: Resurfacing and fractional lasers. *J Plast Reconstr Aesthet Surg*. 2016;69(4):e87-e95.
2. Sharma Y, Jain P, Gottam SB, Sarkar A, Prasad N. Prospective evaluation of fractional carbon dioxide laser treatment of mature burn scars, post-traumatic scars, and post-acne scars. *Cureus*. 2024;16(4).
3. Firooz A, Rajabi-Estarabadi A, Nassiri-Kashani MH. Treatment of atrophic facial acne scars with fractional Er: YAG laser in skin phototype III-IV: A pilot study. *J Cosmet Laser Ther*. 2016;18(4): 204-207.
4. Husein-ElAhmed H, Steinhoff M. Comparative appraisal with meta-analysis of erbium vs. CO₂ lasers for atrophic acne scars. *J Dtsch Dermatol Ges*. 2021;19(11):1559-1568.