

Zygomatic Implants for Partial Maxillary Rehabilitation

Azevedo ACS^{1*}, Soares MM², Merli L¹ and Caminero C³

¹Implantodontist and Oral and Maxillofacial surgeon, Federal University of Sao Paulo, Brazil

²Chairman of Osteogenesis Research Institute and SENAC trainee program on Oral & Maxillofacial surgery, Federal University of Sao Paulo, Brazil

³Prosthodontist, Federal University of Sao Paulo, Brazil

Abstract

Osseo integrated implants are the most effective tool in the rehabilitation of totally or partially edentulous patients. However, bone atrophy is an obstacle to the use of such implants. Severe maxillary resorption limits the installation of conventional implants and necessitates alveolar reconstructive procedures that use autogenous bone grafts harvested from the ilium or from intra oral donor sites. Such procedures increase the morbidity and cost of treatment. In 1984, as an alternative to the use of large bone reconstruction, Branemark proposed that the zygoma be used as an anchorage point for long implant-supported prostheses. Such zygomatic implants are now the most effective bone graft option in the rehabilitation of edentulous patients with severely resorbed maxilla. However, among partially edentulous patients, zygomatic implants are only indicated in hemi-maxillectomized patients. The aims of this clinical report were to present the cases of four patients, each of whom was rehabilitated using a single zygomatic implant on one side of the maxilla; evaluate the success of implant stabilization. The present report shows the feasibility of zygomatic implants in the treatment of partial maxillary edentulism. Despite the good results achieved in this report, more case studies involving a larger number of patients.

Keywords: Oral implants; Zygomatic implant; Rehabilitation

Introduction

Maxillary atrophy following partial edentulism can impede treatment using conventional osseointegrated implants. Originally, zygomatic implants were developed to treat patients with atrophic maxilla or total edentulism [1-3], they were also used as an alternative treatment for hemimaxillectomized patients [4]. To treat partially atrophied maxillae, clinicians can use zygomatic implants alone or in combination with other implants [5]. This approach to treatment can reduce the morbidity and time associated with rehabilitation.

Rehabilitation of atrophic maxilla using osseointegrated implants is a challenge for oral and maxillofacial surgeons. Reduction of the alveolar bone compromises the stability of primary implants. Despite the successes of sinus grafts, bone loss [6] around implants, comorbidities, and the long duration of treatment are problems to consider [7].

Zygomatic implants are a good alternative to bone grafts; they provide early or immediate function for patients, are safe and predictable, and reduce the duration, morbidity, and cost of atrophic maxilla treatment [8]. Zygomatic implants are rarely indicated in cases of full arch rehabilitation. Nonetheless, they have been widely used as an anchorage for prostheses in patients undergoing hemi maxillary ablative surgeries. To ensure stability and oronasal separation, rehabilitative prostheses generally require anchors in cases of partially resected maxillae [9-11].

In this paper, we reported the cases of five patients with hemimaxilla who were treated using unilateral zygomatic implants. The implants were all installed at a position similar to those used in edentulous patients, providing a favorable anchorage for the prosthesis abutments and showing that the mathematical data provided by the analyses is reproducible. Therefore, the unilateral use of zygomatic implants is a viable alternative to sinus augmentation to treat atrophic maxilla.

Materials and Methods

In this series, five patients with posterior class V and VI maxillary alveolar bone atrophy, as described by Cawood and Howell [12], were selected. The patients had an average age of 57.3 years (range: 43–72

years). Three of the patients had unilateral edentulism, while two had bilateral posterior edentulism. All patients had a history of failed graft procedures, and one had used a subperiosteal implant for 10 years. This implant had been removed 1 year prior to the zygomatic implant surgery, and the patient displayed intense fibrous tissue within the posterior maxillary soft tissues. One of the patients presented an oro-sinus fistula that had been closed by the senior author one year prior to the zygomatic surgery (Figure 1 and Table 1).

Patients were anesthetized by endovenous sedation using midazolam and dormonid [13]. All zygomatic implants were inserted via the extra maxillary route (Figure 2). The zygomatic bone was approached by making an incision in the jugal mucosa and creating a tunnel from the alveolar crest into the body of the zygomatic bone. The drilling sequence was conducted in accordance with the manufacturer's

Patient	Sex	Age	Indication	Implants	Load	Follow-up	Complications
SL	M	54	Sinus failure	Two zygomatics	4 months	50 months	None
RF	M	56	Oral fistula	One zygomatic, one conventional	3 months	42 months	Prosthesis
GY	M	74	Fistula, sinus failure	One zygomatic	6 months	48 months	Prosthesis adjustment
TB	M	61	Graft failure	One zygomatic	Immediate	36 months	None

Table 1: One of the patients presented an oro-sinus fistula that had been closed by the senior author one year prior to the zygomatic surgery.

***Corresponding author:** Azevedo ACS, Implantodontist and Oral and Maxillofacial surgeon, Federal University of Sao Paulo, Brazil, Tel: + 551155764000; E-mail: andreacastilhosa@gmail.com

Received: June 02, 2018; **Accepted:** June 12, 2018; **Published:** June 15, 2018

Citation: Azevedo ACS, Soares MM, Merli L, Caminero C (2018) Zygomatic Implants for Partial Maxillary Rehabilitation. J Odontol 2: 109.

Copyright: © 2018 Azevedo ACS, et al. This is an open-access article distributed under the terms of the Creative Commons Attribution License, which permits unrestricted use, distribution, and reproduction in any medium, provided the original author and source are credited.

instructions, and the zygomatic implants were installed using a manual key. All implants were inserted with a minimum of 55 N (Figures 3 and 4).

All patients were treated using a fixed-bridge prosthesis. In three patients, osseointegration was observed within 4 months. In one patient, bilateral alveolar atrophy occurred, and an immediate loading protocol was adopted. In all patients, rigid, bridged-tree prostheses were used. Among these, five zygomatic implants were connected to conventional implants. In one patient, the zygomatic implant was connected to a tooth through a mobile connector (Figures 5-10).

Result

The average follow-up period was 36 months (range: 4–52 months). Patients underwent panoramic radiography 1 week and 4 months after the initial surgery, and then on a yearly basis. After 1 year, all the

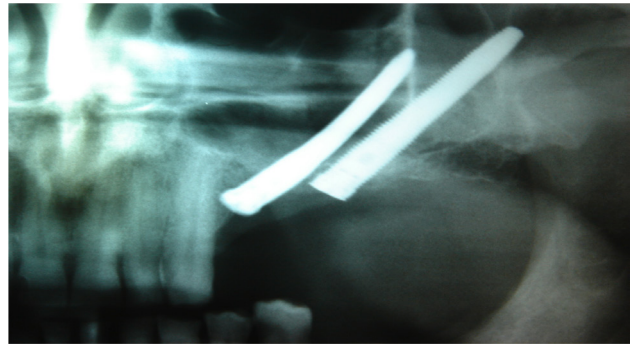


Figure 4: Unilateral zygomatic implant.

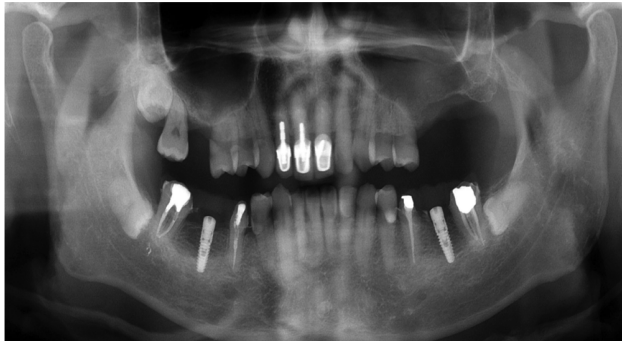

Figure 1: Oro-sinusal fistula closed by the senior author one year prior to the zygomatic surgery.

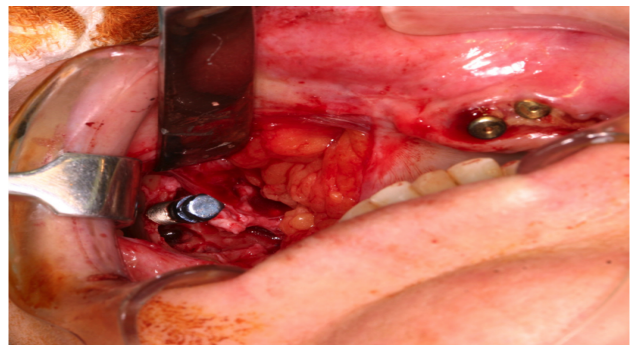


Figure 5: Zygomatic implant connection.

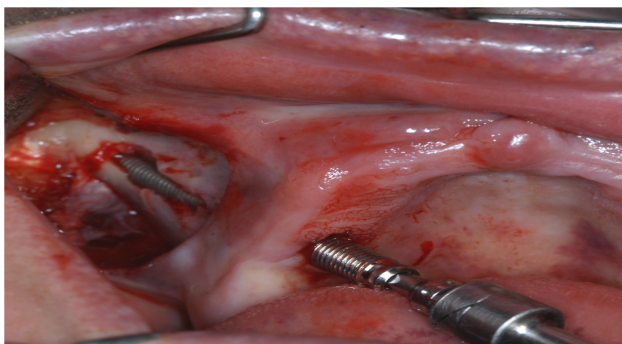


Figure 2: External access to the maxillary sinus.

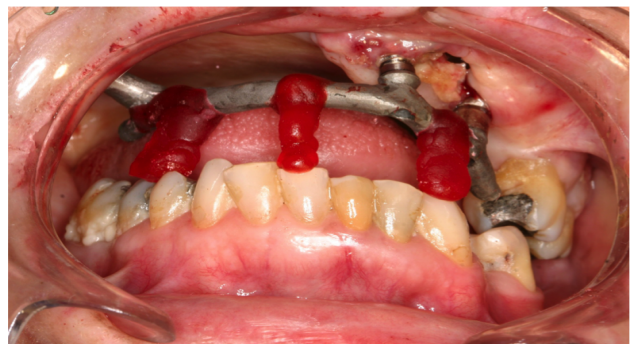


Figure 6: Bar proof.

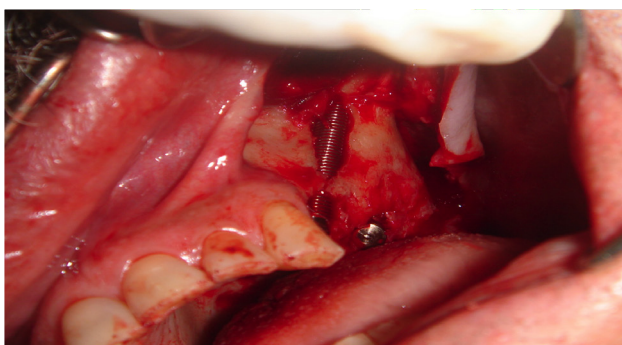


Figure 3: Insertion of zygomatic implant.

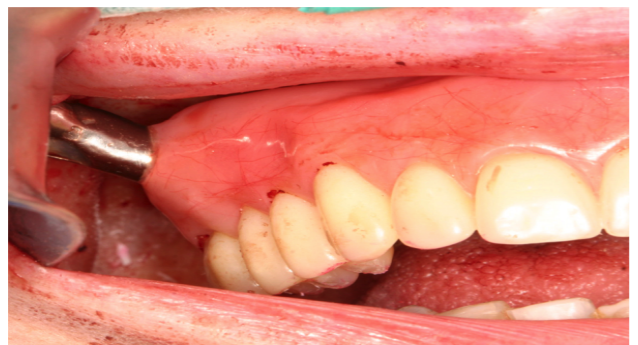

Figure 7: Implant and prosthesis connection.

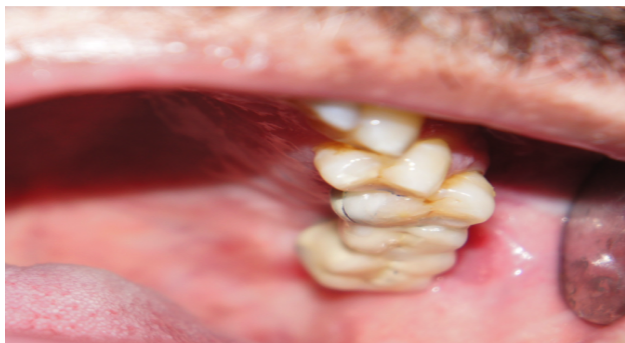

Figure 8: Occlusal view.

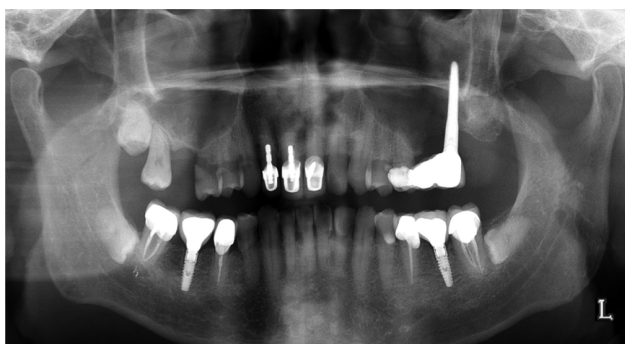

Figure 9: An implant attached to the tooth by means of a fixed prosthesis.

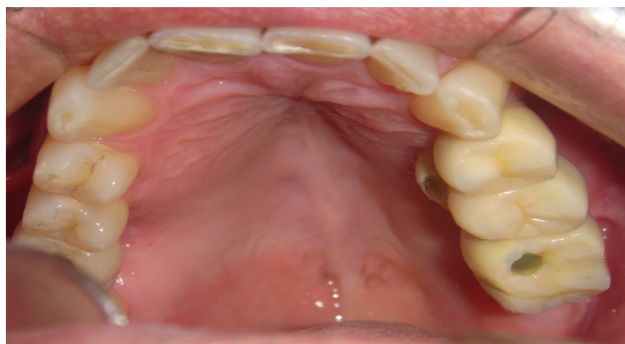

Figure 10: All implants were positioned on the alveolar crest and were in a good position for prosthetic rehabilitation.

implants were submitted to a 6-monthly follow-up control protocol. At the time this report was submitted, all the implants remained functional, with proper occlusal balance. No signs of peri-implantitis were observed, and no clinical infection or exudates occurred. The maxillary sinus remained clean in all cases, with no signs of sinusitis. One patient required early revision of the torque of the prosthetic screw 5 months after the prosthesis installation. However, the patient only returned for semestral follow-ups subsequently.

Discussion

The zygomatic implant surgery offers an interesting alternative for moderately to severely reabsorbed rehabilitation of the maxilla. The zygomatic bone is a solid for anchoring the implant and later for placement of a fixed prosthesis [14].

In this regard, the zygomatic implant has shown excellent results, with a high survival rate during treatment. Indeed, several studies have confirmed that zygomatic implants are an excellent alternative treatment in patients with atrophic maxilla. For instance, Yade [10] reported an 86% success rate among 43 zygomatic implants installed in severely atrophic maxillae, and Malevez [11] reported a survival rate of 100% after 36 months when immediate loading was not used. In a 2009 clinical retrospective analysis involving a follow-up that ranged from 9 months to 5 years, Balshi et al. [12] showed a 96% survival rate among zygomatic implants that had been immediately loaded. Our report points to a survival rate of 99.5% for follow-up of up to 48 months, which is in accordance with other published studies [15-19].

On a related note, Chrcanovic [13] reviewed the various techniques used to place zygomatic implants, as well as the types of maxillary reabsorption that are associated with each method. He concluded that the outward technique is less invasive and faster, and that it is thus the most suitable method in the treatment of maxillae that present a higher rate of reabsorption and have large sinus cavities. The slot technique [20,21], which was used in the present cases, permits a minimally invasive approach, reducing swelling and soft tissue changes around the abutments. In the present study, we employed an extra sinus implant and used a minimally invasive approach to all zygomatic implants. In this way, we achieved a good prosthodontic position, as well as healthy soft tissues around the implants.

Among the complications we reported maxillary sinusitis [15], implant loss [22] and orosinus communication [23-25]. As an alternative to reduce the risk of maxillary sinusitis, we propose the externalized technique developed by Malavez, where we avoid implantation of the implant inside the maxillary sinus, reducing the chance of sinusitis. [11,17].

The zygomatic implant, unlike conventional implants, tends to cause an imbalance in axial occlusal forces. To stabilize these forces, an implant on the opposite site is required; this cancels the torsion forces and prevents micromovements, which destabilize the implant. Indeed, the opposite implant is fundamental to balancing the maxillary arch, reducing micromovements, and ensuring implant longevity [26,27]. Despite the success of rehabilitation using a combination of zygomatic implants and contralateral implants, no studies have yet shown that treatment is unfeasible without these techniques.

Furthermore, titanium intraoral implants can provide additional restraint and prevent excessive mechanical stress exerted by anchoring elements in the residual maxilla. In this regard, a finite element analysis revealed that the success of these implants is directly related to the biomechanical stability of the bone. That is, if the load distribution is concentrated, the bone will regenerate; if it is not, bone reabsorption will occur. It follows that stress is distributed throughout the body of the implant, suggesting that it provides good stabilization without causing bone defects at its base. The studies mentioned all focused on full-arch rehabilitation. However, these constructs have also been used for hemi-arch treatment, suggesting that rehabilitation is feasible without opposite side implants [28].

Within the proposed in this study, the most complicated is to plan a mechanic that supports a unilateral implant without the force dissipated on this one is factor of loss of the implant early. Thus, we propose the use of the externalized technique associated with the prosthesis connected to another implant or dental element canceling out the forces of mastication, such as shearing.

Conclusion

The present report shows the feasibility of zygomatic implants in

the treatment of partial maxillary edentulism. Despite the good results achieved in this report, more case studies involving a larger number of patients, as well as clinical trials comparing zygomatic implants with bone augmentation, will be necessary to provide more information about this treatment approach.

References

1. Gonzalez GR, Naval GL, Munoz GMF, Sastre PJ, Rodríguez CFJ, et al. (2005) Preprosthetic and implant surgery in patients with severe maxillary atrophy. *Oral Med Oral Pathol Oral Radiol* 10: 343-354.
2. Pistilli R, Felice P, Piatelli M, Nisii A, Barausse C, et al. (2014) Blocks of autogenous bone versus xenografts for the rehabilitation of atrophic jaws with dental implants: Preliminary data from a pilot randomised controlled trial. *Eur J Oral Implantol* 7: 153-171.
3. Dawood A, Collier J, Darwood A, Tanner S (2015) The reverse zygomatic implant: A new implant for maxillofacial reconstruction. *Int J Oral Maxillofac Implants* 30: 1405-1408.
4. Brånemark PI, Adell R, Albrektsson T, Lekholm U, Lindström J, et al. (1984) An experimental and clinical study of osseointegrated implants penetrating the nasal cavity and maxillary sinus. *J Oral Maxillofac Surg* 42: 497-505.
5. Ying T, Dong-Mei W, Cheng-Tao W, Yi-Qun W, Zhi-Yuan Z (2006) Biomechanical evaluation of unilateral maxillary defect restoration based on modularized finite element model of normal human skull. In *engineering in medicine and biology society. 27th Annual International Conference* pp: 6184-6187.
6. Cawood JI, Howell RA (1988) A classification of the edentulous jaws. *Int J Oral Maxillofac Surg* 17: 232-236.
7. Physical Status Classification System (2012) In: *ASA relative value guide: A guide for anesthesia values*. Park Ridge, IL: American Society of Anesthesiologists p: 123.
8. Nyström E, Ahlqvist J, Legrell PE, Kahnberg KE (2002) Bone graft remodelling and implant success rate in the treatment of the severely resorbed maxilla: A 5-year longitudinal study. *Int J Oral Maxillofac Surg* 31: 158-164.
9. Aloy-Prósper A, Maestre-Ferrin L, Peñarrocha-Oltra D, Peñarrocha-Diago M (2011) Bone regeneration using particulate grafts: An update. *Med Oral Patol Oral Cir Bucal* 16: e210-214.
10. Yates JM, Brook IM, Patel RR, Wragg PF, Atkins SA, et al. (2014) Treatment of the edentulous atrophic maxilla using zygomatic implants: Evaluation of survival rates over 5–10 years. *Int J Oral Maxillofac Surg* 43: 237-242.
11. Malevez C, Daelemans P, Adriaenssens P, Durdu F (2003) Use of zygomatic implants to deal with resorbed posterior maxillae. *Periodontol* 33: 82-89.
12. Balshi SF, Wolfinger GJ, Balshi TJ (2009) A retrospective analysis of 110 zygomatic implants in a single-stage immediate loading protocol. *Int J Oral Maxillofac Implants* 24: 335-341.
13. Chrcanovic BR, Abreu MH (2013) Survival and complications of zygomatic implants: A systematic review. *J Oral Maxillofac Surg* 17: 81-93.
14. Malo P, Rangert B, Nobre M (2003) All-on-Four: Immediate function concept with Brånemark System® implants for completely edentulous mandibles: A retrospective clinical study. *Clin Implant Dent Relat Res* 5: 2-9.
15. Bedrossian E (2010) Rehabilitation of the edentulous maxilla with the zygoma concept: A 7-year prospective study. *Int J Oral Maxillofac Implants* 25: 1213-1221.
16. Davó R (2009) Zygomatic implants placed with a 2-stage procedure: A 5-year retrospective study. *Eur J Oral Implantol* 2: 115.
17. Malevez C, Abarca M, Durdu F, Daelemans P (2004) Clinical outcome of 103 consecutive zygomatic implants: A 6–48 months follow-up study. *Clin Oral Implants Res* 15: 18-22.
18. Brånemark PI, Gröndahl K, Öhrnell LO, Nilsson P, Petruson B, et al. (2004) Zygoma fixture in the management of advanced atrophy of the maxilla: Technique and long-term results. *Scand J Plast Reconstr Surg Hand Surg* 38: 70-85.
19. Hirsch JM, Öhrnell LO, Henry PJ, Andreasson L, Brånemark PI, et al. (2004) A clinical evaluation of the Zygoma fixture: One year of follow-up at 16 clinics. *J Oral Maxillofac Surg* 62:22-29.
20. Stella JP, Warner MR (2000) Sinus slot technique for simplification and improved orientation of zygomatic dental implants: A technical note. *Int J Oral Maxillofac Implants* 15: 889-893.
21. Peñarrocha M, Uribe R, García B, Martí E (2005) Zygomatic implants using the sinus slot technique: Clinical report of a patient series. *Int J Oral Maxillofac Implants* 20: 788-792.
22. Aparicio C, Ouazzani W, Garcia R, Arevalo X, Muela R, et al. (2006) A Prospective clinical study on titanium implants in the zygomatic arch for prosthetic rehabilitation of the atrophic edentulous maxilla with a follow-up of 6 months to 5 years. *Clin Implant Dent Relat Res* 8: 114-122.
23. Bothur S, Garsten M (2010) Initial speech problems in patients treated with multiple zygomatic implants. *Int J Oral Maxillofac Implants* 25: 379.
24. Stiévenart M, Malevez C (2010) Rehabilitation of totally atrophied maxilla by means of four zygomatic implants and fixed prosthesis: A 6–40-month follow-up. *Int J Oral Maxillofac Surg* 39: 358-363.
25. Pellegrino G, Tarsitano A, Basile F, Pizzigallo A, Marchetti C (2015) Computer-aided rehabilitation of maxillary oncological defects using zygomatic implants: A defect-based classification. *J Oral Maxillofac Surg* 73: 2446-e1.
26. Brunski JB (1988) Biomechanics of oral implants: Future research directions. *J Dent Educ* 52: 775-787.
27. Meredith N (1998) Assessment of implant stability as a prognostic determinant. *Int J Prosthodont* 11: 491-501.
28. Rossi M, Duarte LR, Mendonça R, Fernandes A (2008) Anatomical bases for the insertion of zygomatic implants. *Clin Implant Dent Relat Res* 10: 271-275.