

Safety and Efficacy of Topical 0.1% And 0.05% Cyclosporine A in an Aqueous Solution in Steroid-Dependent Vernal Keratoconjunctivitis in a Population of Mexican Children

Leopoldo M Baiza-Duran^{1*}, Ana C González-Villegas¹, Yusselt Contreras-Rubio¹, Juan C Juarez-Echenique², Iris V Vizuett-Lopez², Raul Suarez-Sanchez³, Concepcion Santacruz-Valdes³, Jose F Alaniz-de-la-O⁴ and Laura R Saucedo-Rodriguez⁴

¹Clinical Research Department, Laboratorios Sophia, Guadalajara, Mexico

²Instituto Nacional de Pediatría, Mexico City, Mexico

³Instituto Oftalmológico Fundación Conde de Valenciana, Mexico City, Mexico

⁴Hospital Civil de Guadalajara, Guadalajara, Mexico

Abstract

Purpose: Evaluate safety, efficacy and tolerability of 0.1% and 0.05% Cyclosporine A eye drops in Mexican children with Steroid Dependent Vernal Keratoconjunctivitis.

Methods: This was a multicenter, prospective, randomized and double masked clinical trial where the effects of 0.1 and 0.05% cyclosporine A (aqueous solution) eyedrops were evaluated in children with steroid dependent Vernal Keratoconjunctivitis. Patient evaluation was done at baseline, 2, 7, 14, 30, 60, 90, 120, 150, and 180 days. Conjunctival discharge, conjunctival papillae size, conjunctival chemosis, tearing, itching, burning sensation, photophobia and conjunctival hyperemia were the primary endpoints.

Results: 112 patients (224 eyes) with Vernal Keratoconjunctivitis were included (mean age= 10.25 ± 3.83 years). 56 patients received 0.1% Cyclosporine eye drops, and another 56 patients got 0.05% Cyclosporine. Both treatments decreased the severity of all symptoms and clinical signs after 6 months (p<0.05). Treatment with ocular steroids was suspended during the study. There were no adverse events reported.

Conclusions: Cyclosporine A in aqueous solution was safe and effective in both concentrations. Topical 0.1% Cyclosporine was better than topical 0.05% Cyclosporine for improving signs and symptoms of Vernal Keratoconjunctivitis patients. Tolerability was equal for both groups. Cyclosporine treatment also allowed the cessation of topical steroid treatment.

Keywords: Topical Cyclosporine; Vernal Keratoconjunctivitis; Aqueous solution; Allergic conjunctivitis

Abbreviations: VKC: Vernal Kerato Conjunctivitis; CsA: Cyclosporine A

Introduction

Allergic conjunctivitis is a local allergic condition centered mainly in the ocular area, although sometimes it is also associated with rhinitis. The disease ranges in severity from mild to severe forms. Mild can still interfere significantly with quality of life, while severe cases are characterized by potential impairment of visual function, especially if the cornea is involved [1]. Vernal Keratoconjunctivitis (VKC) is one severe chronic form of seasonally exacerbated allergic conjunctivitis. It is more common in children and young adults having an atopic background. Aside from being one of the most severe forms of ocular allergy, VKC can be considered the childhood form of allergic conjunctivitis due to the fact that the condition affects mainly children in their first decade of life and young adults [1-3]. In Mexico we have a significant incidence of VKC in children [4]. This ocular allergy is characterized by bilateral inflammation of the palpebral conjunctiva, itching, conjunctival hyperemia and chemosis among others signs and symptoms. This disorder is usually triggered by allergens in the air, especially plant pollen, leading to seasonal exacerbations during the spring and summer months [5]. Conventionally, VKC pathogenesis has been considered as a type 1 hypersensitivity reaction, which means that it is driven primarily by IgE-mediated mast cell activation. However, recent studies have broadened the knowledge about the pathophysiology of this disease and indicate that VKC is more complex than a mere type 1

hypersensitivity disease, as very complex inflammatory processes have been shown to occur on the ocular surface [2,6]. By itself, the IgE-mast cell mediated process does not explain the entirety of the clinical and histopathological changes associated with VKC; there are other mediators and cells involved in the initiation and perpetuation of the ocular allergic inflammation [2].

Therapeutic measures are required to control signs and symptoms of VKC and to avoid the initiation of longstanding permanent inflammatory sequela that may lead to fibro vascular reaction, new collagen deposition, tissue remodeling and permanent visual damage. There are a variety of drugs currently used to treat VKC, including anti-histamines, mast-cell stabilizers, dual acting agents, corticosteroids and immunomodulators or immunosuppressants, but none have been shown to be sufficient to treat all aspects of the complex pathophysiology of VKC [1,7].

***Corresponding author:** Leopoldo Baiza-Duran, Av. Paseo del Norte No. 5255, Fracc. Guadalajara Technology Park, Zapopan, Jalisco, Mexico C.P. 45010, Tel: 523330014200; Fax: 523330014271; E-mail: lbaiza@sophia.com.mx

Received October 28, 2010; **Accepted** December 03, 2010; **Published** December 04, 2010

Citation: Baiza-Duran LM, González-Villegas AC, Contreras-Rubio Y, Juarez-Echenique JC, Vizuett-Lopez IV, et al. (2010) Safety and Efficacy of Topical 0.1% And 0.05% Cyclosporine A in an Aqueous Solution in Steroid-Dependent Vernal Keratoconjunctivitis in a Population of Mexican Children. J Clin Exp Ophthalmol 1:115. doi:10.4172/2155-9570.1000115

Copyright: © 2010 Baiza-Duran LM, et al. This is an open-access article distributed under the terms of the Creative Commons Attribution License, which permits unrestricted use, distribution, and reproduction in any medium, provided the original author and source are credited.



Topical steroids are the conventional treatment for practically all severe kind of allergic conjunctivitis. They are also the most effective drugs to control the signs and symptoms of VKC [1,8]. However, the long term use of steroids has clinical limitations due to their side effects and may result in severe complications such as ocular hypertension, glaucoma, cataract and secondary infections [7]. Additionally, there is a subset of VKC patients that become refractory to the corticosteroids treatment over time. Consequently, the development of agents that could be used effective and chronically without serious adverse effects is very important, for the management of chronic ocular disorders such as VKC [1]. This is where immunomodulatory agents such as Cyclosporine A (CsA) may be important.

CsA inhibits T cells proliferation and prevents the release of pro-inflammatory cytokines by blocking the activity of calcineurin, a ubiquitous enzyme found in cell cytoplasm that is implicated in the control of replication of the genes for IL-2 and other pro-inflammatory cytokines.

There is a body of evidence supporting the use of CsA as a treatment for VKC. Several basic and clinical trials have demonstrated that CsA in oleic emulsion decreases the signs and the symptoms of this allergic disease [9,10]. Topical CsA treatment also has an advantage in that it lacks the serious adverse ocular effects often seen with topical corticosteroids [11].

Nonetheless, currently available systems using oils to deliver CsA are poorly tolerated and provide low bioavailability of the drug. Patients treated using these formulations of CsA have reported moderated to intense stinging, tearing, redness and swelling of lids after drop instillation [7]. CsA is a lipophilic molecule that it must be regularly dissolved in an alcohol-oil base, which causes the ocular irritation mentioned above [12,13]. However, these difficulties may be overcome through formulations aimed at improving the water solubility of CsA, facilitating tissue drug penetration, or by using penetration colloidal carriers (micelles) [14].

In the present study, we evaluated the safety, efficacy and tolerability of two different concentrations of a topical aqueous solution CsA in Mexican children with steroid-dependent VKC. We used a CsA aqueous solution with "Sophisen", a patented drug carrier developed by Laboratorios Sophia. This CsA-carrier association creates a monodisperse, stable, micelle solution, which is free of benzalkonium chloride [15].

Patients and Methods

This was a double-masked, comparative, prospective, multicenter clinical study. It was reviewed and approved by the Ethics Committee of each center. The study was conducted in accordance with the

ethical principles of the Declaration of Helsinki. Written informed consent was obtained from each volunteer's parent.

Patients with moderate to severe steroid dependent VKC who met the inclusion criteria according to previously established definitions were included in the study (Table 1).

VKC was diagnosed based on the presence of itching, mucus discharge, papillae on the superior tarsal conjunctiva and changes in the limbal area. At the time of inclusion in the study, all the patients were disease positive in an active stage and they were under treatment with topical steroids (loteprednol etabonate, prednisolone or dexamethasone), and in about 5% of cases, the disease had remained refractory to treatment with steroids for more than two weeks. The eligibility approval for all the subjects was determined after concluding the clinical evaluation in the basal visit. A complete washout period was then initiated for all study participants, which consisted in the use of only physical measures during 1 week. For all the patients the use of topical steroids was discontinued during the washout; after this period topical steroid use was not re-initiated. After the washout each subject was randomly assigned to one of the two groups where they received one of the two CsA treatments exclusively.

All the study drugs were labeled with a non-sequential number code generated randomly by computer. The clinical assessment was carried out by an evaluator who was denominated "Evaluation Researcher" who during the length of the study was blinded with respect to which drugs corresponded to each random label. The therapeutic scheme assignment for each of both groups was conducted randomly by just one researcher, named "Assign Researcher," who was the only one that knew the corresponding therapy for each number code.

The patients were organized randomly in two groups: Group A received the CsA 0.1% aqueous ophthalmic solution (Modusik-A Ofteno®, Laboratorios Sophia S.A. de C.V., Guadalajara, Jalisco, Mexico), in a dosage of one drop every 12 hours in both eyes (8:00 h and 20:00 h \pm 1 hour) during the 180 days of the study. Patients of group B received the CsA 0.05% aqueous ophthalmic solution (Elaborated by Laboratories Sophia S.A de C.V. for this study) with the same dosage and duration as in group A, during the 180 days of the study.

All patients were evaluated by the same investigator in the screening period, as well as in the subsequent programmed follow-up visits (days 2, 7, 14, 30, 60, 90, 120, 150 y 180). Consequently, on each follow-up visit, a tolerance questionnaire was applied using a verbal analog scale starting from 0 to 3 with increasing intensity of symptoms (Table 2).

INCLUSION CRITERIA
Patients with a clinical diagnosis of Steroid-Dependent Vernal Keratoconjunctivitis (Steroid-Dependent VKC: VKC Patients whose signs and symptoms only responded to topical corticosteroids and not to other medications).
Patients of either gender, 5 years or older.
EXCLUSION CRITERIA
Patients with one blind eye.
Patients with visual acuity of 20/40 or worst in any of both eyes without a justifying cause.
Patients who are in an active stage of any other ocular inflammatory disease besides of VKC.
Patients receiving medication through topical ocular route of administration or any other that can in a very determinant way interfere in the results of the study, up to 48 hours prior to day 1 of study or until a period of time in which there are still residual effects. Such medication as systemic NSAIDs, systemic steroidal anti inflammatory drugs, systemic immunosuppressants and ocular topical lubricants.
Patients with history of hypersensitivity or any medical situation that contraindicates or makes risky the use of any of the study articles or their compounds under any route of administration as well as any drug or formulation derived from them or related to them.
Contact lenses users.
Patients enrolled in any medical trial out of Laboratorios Sophia, S.A. de C.V. sponsorship under the last 90 days prior to this trial.
Patients who cannot comply with the medical appointments or with all the protocol requirements.
Patients who disagree to participate in this clinical trial.

Table 1: Eligibility criteria for VKC patients.

SYMPTOMS	0	1	2	3
Itching	No desire to rub or stretch the eye	Occasional desire to rub or stretch the eye	Frequent need to rub or stretch the eye	Constant need to rub or stretch the eye
Tearing	Normal tear production	Positive sensation of fullness of the conjunctival sac without tears spilling over the lid margin	Intermittent, infrequent spilling of tears over the lid margin	Constant, or nearly constant, spilling of tears over the lid margin
Foreign body sensation	Absent	Mild, similar to fine dust sensation	Moderate, similar to sand sensation, with mild tearing and blinking	Severe, similar to big foreign body sensation, with constant tearing and blepharospasm
Photophobia	No difficulty experienced	Mild difficulty with light causing squinting	Moderate difficulty, necessitating dark glasses	Extreme photophobia causing the patient to stay indoors; cannot stand natural light even with dark glasses
Stinging	Absent	Mild	Moderate	Severe
Red eye	Absent	Mild, he/she cannot observe his red eye but is told he/she has it	Moderate, he/she can observe his red eye from 30 cms in a mirror	Severe, he/she can observe his red eye from more than 30 cms in a mirror
SIGNS	0	1	2	3
Conjunctival hyperemia	Absent	Mild, in an area less than 25% of total conjunctival surface, including tarsal and bulbar	Moderate	Severe, with hyperemia in all conjunctival surface
Conjunctival discharge	Absent	Small amount of translucent or whitish discharge in the lower cul-de-sac	Moderate amount of like yellow or green-yellowish discharge in the lower cul-de-sac and in the marginal tear strip	Severe, with blood traces in the lower cul-de-sac and in the marginal tear strip
Tarsal conjunctival papillary hypertrophy	No evidence of papillary formation	Mild papillary hyperemia	Moderate papillary hypertrophy with edema of the palpebral conjunctiva and hazy view of the deep tarsal vessel	Severe papillary hypertrophy obscuring the visualization of the deep tarsal vessels
Chemosis	Absent	Mild, in an area less than 25% of total conjunctival surface, including tarsal and bulbar	Moderate	Severe, with volume augmentation in all conjunctival surface

Table 2: Grading Scale for Ocular Signs and Symptoms in VKC study.

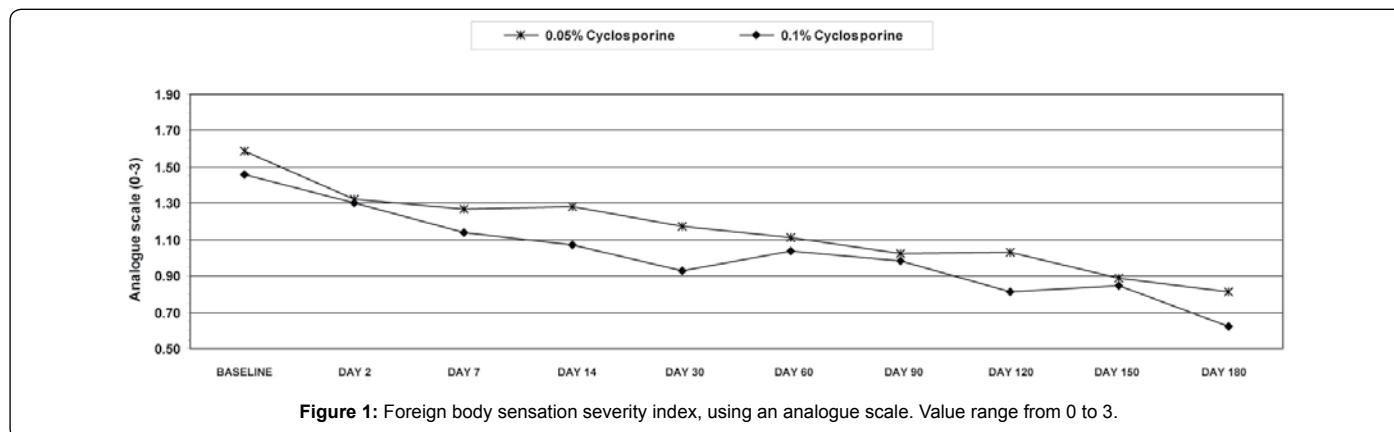


Figure 1: Foreign body sensation severity index, using an analogue scale. Value range from 0 to 3.

For the purpose of this study, six symptoms (ocular itching, red eye, burning sensation, photophobia, tearing, and ocular foreign body sensation) were evaluated and also eight clinical signs (conjunctival hyperemia, ocular surface condition, conjunctival discharge, chemosis, Bengal rose staining, fluorescein staining, papillae and follicles) were charted. These signs are directly related to the presence and severity of vernal conjunctivitis. Other variables (anterior segment condition, posterior segment condition) that are related to ocular health were also evaluated. The investigators at each center used identical forms to evaluate and measure these variables (referred in Table 2).

Basal examination

The basal examination (day 0 of the study) was carried out 7 days previous to the day 1 of the study. In this visit, the patient and their parents were asked to sign the informed consent. Demographic information, clinical history and specific symptoms were obtained. A complete ophthalmic examination including visual acuity determination (Snellen chart), biomicroscopy, intraocular pressure (IOP) measurement (Goldmann aplanation tonometer) and funduscopy under pupillary dilation was conducted. Patients meeting eligibility criteria during the basal visit were included in the study.

Follow-up visits on days 1, 2, 7, 14, 30, 60, 90, 120, 150 and 180

On each follow-up visit, visual acuity, biomicroscopy, and IOP were obtained. Funduscopy under pupillary dilation was performed only on days 90 and 180.

Statistical analysis

The collected data were logged into Excel 2000 software (Microsoft Corporation, Redmond, WA) and analyzed with SPSS statistical program (SPSS Inc., Chicago, IL, 2002, v. 10.0). Simple correlations and linear regressions were made between both eyes to establish the validity of the information from either eye. The following analyses were employed to compare differences between and within groups: bifactorial variance of Friedman, ANOVA with Bonferroni's post-hoc method, repeated measurements ANOVA for continuous variables, and Wilcoxon and Kruskal-Wallis tests for categorical variables. A p value < 0.05 was considered statistically significant.

Results

Demographics

The mean age of the 112 VKC patients (224 eyes) was 10.25 ±

3.83 years. 72 (64.3 %) were male and 35.5% were female children. All of them were Mexican nationals. Half of the patients (56) received a 0.1% cyclosporine A (CsA) solution (group A) in both eyes, and the other half received the 0.05% CsA solution (group B), also in both eyes.

Due to high correlation values between eyes (0.75-0.89; $k=0.73-0.81$) the analysis of both eyes of each patient is presented in a cumulative manner. If eyes were individually analyzed, the results would not be changed significantly.

Efficacy

Using the Mann-Whitney test, 0.1% CsA eye drops as well as 0.05% CsA showed a statistically significant improvement in signs and symptoms compared to baseline ($p<0.05$). The improvement in all signs and symptoms compared with baseline was very clear starting from the first week of treatment and continued improvement was

seen during the six months of the study. All the mean scores for signs and symptoms significantly decreased from month 1 to 6 of treatment in these VKC patients.

Comparing both CsA concentrations, the improvement level was better for group A (CsA 0.1%) compared with group B with regard to the following variables: foreign body sensation ($p<0.05$ at days 14, 30 and 120) (Figure 1); conjunctival chemosis -from day 14 until the end of treatment ($p<0.05$) (Figure 2); and conjunctival discharge during days 14, 30 and 60 ($p<0.05$). After day 60 both CsA concentrations behaved similarly with no statistical differences (Figure 5).

There were no differences between both groups in the following variables: Conjunctival papillae (Figure 3); conjunctival hyperemia (Figure 4) and itching. No clinical or statistically significant changes occurred with respect to the ocular health and safety variables evaluated (Bengal rose and fluorescein staining).

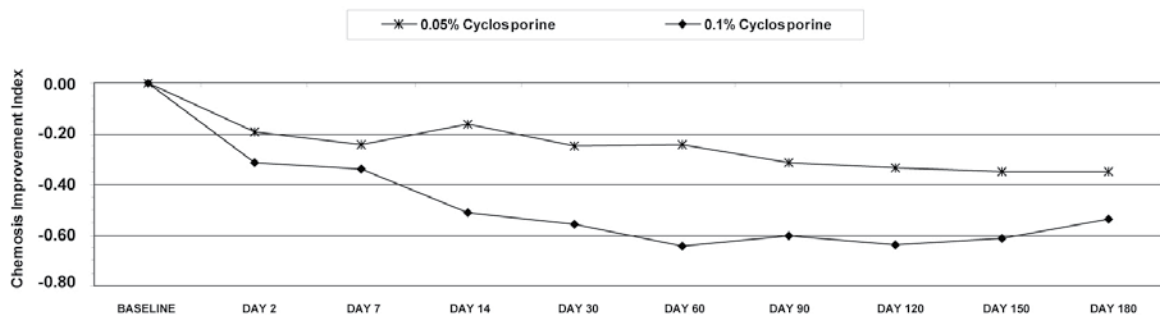


Figure 2: Chemosis improvement index. Value range from 0 to 3.

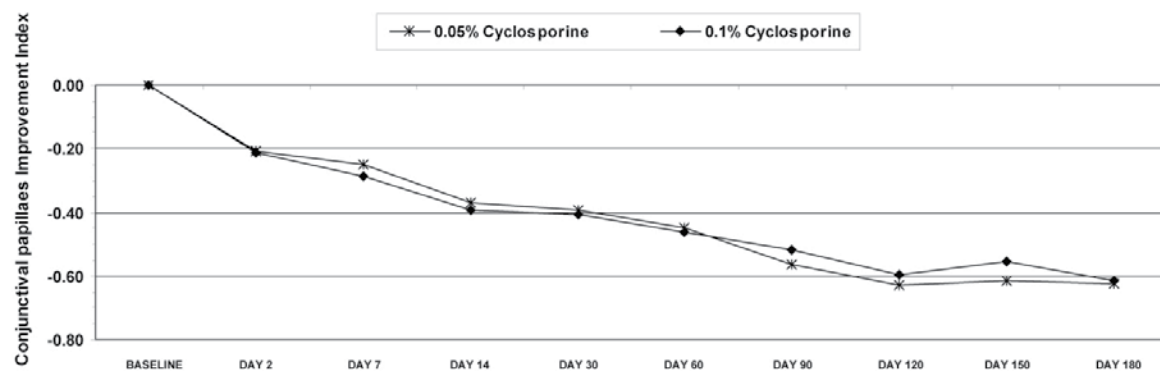


Figure 3: Conjunctival papillae improvement index. Value range from 0 to 3.

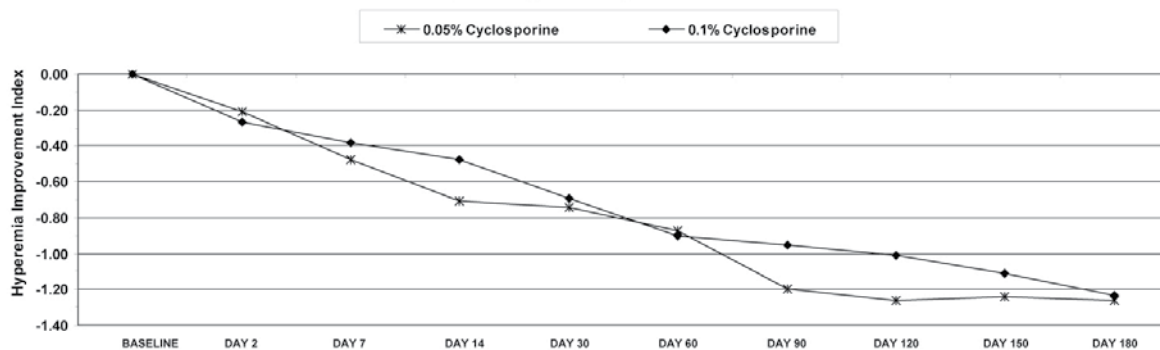
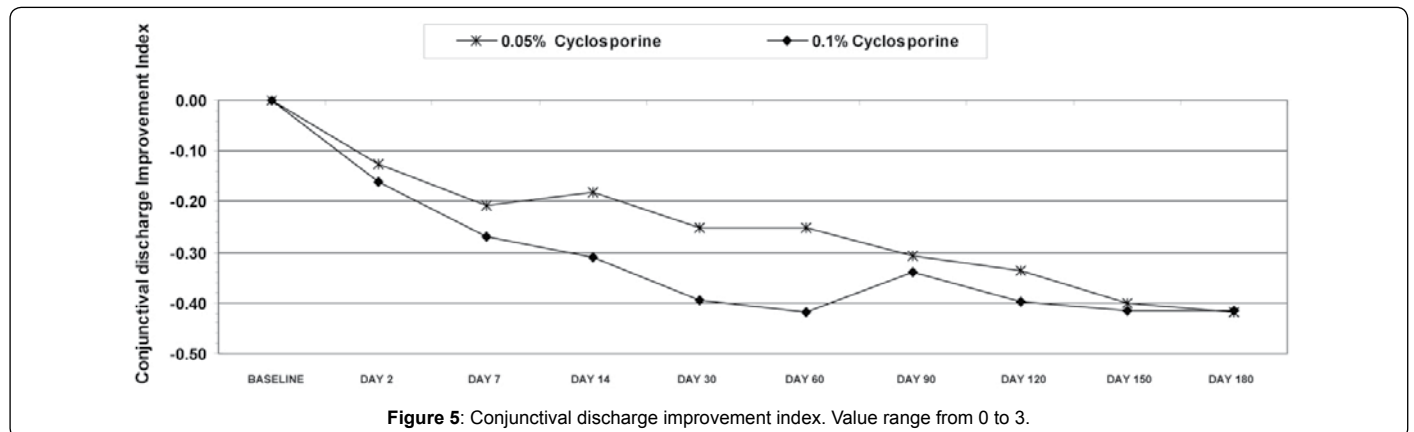


Figure 4: Hyperemia improvement index. Value range from 0 to 3.





No serious adverse effects were reported in either of the groups during the follow-up period. In the case report forms we did not find reports of corneal involving, nor before starting or during the clinical trial.

Discussion

An effective and safe therapy for VKC is needed to improve signs and symptoms and to prevent ocular complications. Long-term use of steroids has effective results, but steroids should be carefully administered, and only for brief periods, to avoid their well-known adverse effects, mainly the secondary development of glaucoma [16].

The results of the present study confirm the beneficial effect of topical CsA 0.1% aqueous solution in improving the symptoms and clinical manifestations of moderate to severe allergic conjunctivitis type VKC. This is the first report of such an effect with this agent that has been formally demonstrated in a population of Mexican children with VKC. Further, in previous clinical studies for the topical use of CsA for allergic conjunctivitis, the drug had been administered as an oil base emulsion, while the present study used a monodisperse, stable, micelle aqueous solution, previously characterized by Quintana-Hau et al. [15]. This aqueous CsA formulation was also able to improve tolerance and compliance to the treatment.

It has been demonstrated by the abundance of Th2 cytokines in tears and serum of VKC patients that T helper type 2 cells (Th2), and their cytokines, contribute in a very crucial way to the onset and perpetuation of this disease. An altered balance between T helper type 1 (Th1) and Th2 cells and between Th1-Th2-types of cytokines is thought to be responsible of the development of ocular allergic diseases. Furthermore, conjunctival mast cells, eosinophils and macrophages, along with a wide range of cytokines, chemokines, proteases and various growth factors, play an important role in the pathogenesis of the disease [17,18]. Th2 cytokines are responsible for both hyperproduction of IgE (IL-4) and for differentiation and activation of mast cells (IL-3) and eosinophils (IL-5) [12]. The mast cells are a key cellular component and play a pivotal role in initiating the inflammatory cascade of events in allergic eye disease. Mast cells cytokines are also responsible for the initiation of this inflammation by promoting the eosinophil recruitment that infiltrate the conjunctiva and cornea in VKC. Two subtypes of mast cell have been recognized in humans based in their neutral protease content and T lymphocyte dependency. The T lymphocyte-dependent mast cell (MC_T), contains only tryptase in their granules which are characterized by lattice substructure. The other subtype is the mast cell that contains both enzymes tryptase and chymase (MC_{TC}). Patients with active VKC

have a significant increase in MC_T mast cells in the epithelial cells of conjunctival biopsy specimens, while normal patients have the majority of subtype MC_{TC} mast cells [16,17,18].

Cyclosporine A, more than merely a non-specific immunomodulator, is an immunosuppressive molecule with predominant inhibitory effects against Th2 lymphocyte proliferation that acts by blocking early activation of genes specifically related to cytokines, mainly IL-2. CsA interferes with mast cell and lymphocyte-mediated cytokine production and thus it has an inhibitory effect on the development of allergic disease. It is able to inhibit histamine release through a reduction in IL-5 production [9] Recently, it has been shown that CsA diminishes mast cell degranulation avoiding the release of pro-inflammatory molecules and also suppressing mast cell-white cell cytokine cascades [17,18,19]. The exact mechanism of action of CsA on mast cells is unknown, but it may be postulated that the drug modulates local IgE production by B cell by means of its effects on Th2 cells or possibly by influencing T-lymphocyte-dependent mast cells [12,13,17].

Although most studies reported in the literature have used high concentrations of CsA, up to 2% for example, we considered it beneficial to use an aqueous solution with a lower concentration. Based on our previous study (displayed in ARVO 2004), in which we compared the Corneal passive diffusion of Modusik-A Ofteno™ (0.05% and 0.1%) versus the Restasis™ (0.05% CsA in castor oil; Allergan, Irvine CA) and Modusik-A Ofteno™ (0.1%) versus 2.0% CsA in olive oil as vehicle [20], we believe that the present formulation used in this study could increase bioavailability and allow higher effective concentrations of the drug in the ocular tissue without having to raise the raw concentration. This work is not the first to show the efficacy of CsA in treating ocular disease. In fact, similar findings regarding efficacy have been reported with CsA eye drops but with different concentrations and vehicles [3,6,13,19,21-24]. The first studies from the years 1991 to 2002 show a certain consistency in using CsA 2%, the highest concentration for VKC treatment; however recently the concentration of CsA eye drops has been diminishing (to a current minimal of 0.05%). These data suggest a trend towards the lowering of the CsA concentration and to changes to other vehicles that are safer and better tolerated for VKC patient [25,26].

It is important to emphasize that, in the present study; we observed improvement in the clinical manifestations of vernal keratoconjunctivitis using both 0.05 % and 0.1% CsA concentrations. However, it was evident that the most statistically significant differences occurred most clearly in 0.1% CsA solution for a number of variables, and that these improvements were seen earlier than

in the group with the 0.05% treatment. This suggests that CsA has a positive effect which is dependent on the concentration used. It seems that the positive effect in VKC could be due to the suppression of T lymphocytes proliferation and also to the drug's effect on mast cells and eosinophils [18].

According to our results, both formulations of CsA were effective, safe and well tolerated; use of both concentrations led to improvements in the clinical manifestations of VKC and the cessation of the use of topical steroids.

We did not observe any complication in the administration of CsA in our patients during the clinical trial. However, the topical CsA 0.1% aqueous solution was better than CsA 0.05% for achieving improvement of the signs and symptoms of allergic conjunctivitis. Additionally, the fact that CsA has been formulated in an aqueous solution increases the bioavailability of the drug in the cornea and conjunctiva, as has been demonstrated in another of our studies by Quintana-Hau et al. [15].

In conclusion, topical application of a 0.1% CsA aqueous solution has been shown to be safe, effective and well tolerated in the treatment of patients with conventional and steroid-resistant VKC. Our results are consistent with the results that Ebihara found in VKC patients with a 0.1% CsA formulation with an aqueous vehicle [27]. This is the first study in Mexican VKC patients using the commercially available topical aqueous solution of 0.1% CsA. The use of cyclosporine 0.1% eyedrops in aqueous solution for treatment of VKC should be considered in order to prevent complications associated with the natural history of the disease and the long-term use of corticosteroids. Our study, in accordance with that Kosirukwongs, also suggests that CsA could be an important alternative medication in VKC patient's refractory to steroids treatment [28].

Funding

Laboratorios Sophia, S.A. de C.V.

Competing interests

Leopoldo M Baiza-Duran, Ana C González-Villegas and Yussett Contreras-Rubio are Laboratorios Sophia employees.

Ethics approval

Ethics approval was provided by the Ethics Committee of Instituto Nacional de Pediatría of Mexico City, Instituto Oftalmológico Fundación Conde de Valenciana of Mexico City, and Hospital Civil de Guadalajara.

Patient consent: Obtained.

References

- Leonardi A, Motterle L and Bortolotti M (2008) Allergy and the eye. *Clin Exp Immunol* 153: 17-21.
- Sunil Kumar (2009) Vernal keratoconjunctivitis: a major review. *Acta Ophthalmol* 87:133-147.
- Kiliç A, Gürler B (2006) Topical 2% cyclosporine A in preservative-free artificial tears for the treatment of vernal keratoconjunctivitis. *Can J Ophthalmol*. 41: 693-698.
- Zepeda-Ortega B, Rosas-vargas MA, Ito Tsuchiya FM (2007) Conjunctivitis alérgica en la infancia. *Revista Alergia México* 54: 41-53.
- Whitcup SM, Chan CC, Luyo DA, Bo P, Li Q (1996) Topical cyclosporine inhibits mast cell-mediate conjunctivitis. *Invest Ophthalmol Vis Sci* 37: 2686-2693.
- Bonini S, Coassin M, Aronni S, Lambiasi A (2004) Vernal keratoconjunctivitis. *Eye (Lond)* 18: 345-351.
- Hingorani M, Lightman S Therapeutics options in ocular allergic disease. (1995) *Drugs* 50: 208-211.
- Spadavecchia L, Fanelli P, Tesse R, Brunetti L, Cardinale F, et al. (2006) Efficacy of 1.25% and 1% topical cyclosporine in the treatment of severe vernal keratoconjunctivitis in childhood. *Pediatr Allergy Immunol* 17: 527-532.
- BenEzra D, Matamoros N, Cohen E (1988) Treatment of severe vernal keratoconjunctivitis with Cyclosporine A eyedrops. *Transplant Proc* 20: 644-649.
- Avunduk AM, Avunduk MC, Erdöl H, Kapicioglu Z, Akyol N (2001) Cyclosporine effects on clinical findings and impression cytology specimens in severe vernal keratoconjunctivitis. *Ophthalmologica* 215: 290-293.
- Leonardi A, Hall A (2010) Mechanisms of corneal allergic reaction: new options for treatment. *Expert Rev Ophthalmol* 5: 545-556.
- Belin MW, Bouchard CS, Phillips (1990) Update on topical cyclosporine A: Background, Immunology and Pharmacology. *Cornea* 9: 184-195.
- Ozcan AA, Ersoz TR, Dulger E (2007) Management of severe allergic conjunctivitis with topical cyclosporine a 0.05% eye drops. *Cornea* 26: 1035-1038.
- Lallemant F, Felt-Baeyens O, Besseghir K, Behar-Cohen F, Gurny R (2003) Cyclosporine A delivery to the eye: a pharmaceutical challenge. *Eur J pharm Biopharm* 56: 307-318.
- Quintana-Hau JD, Cruz-Olmos E, López-Sánchez MI, Sánchez-Castellanos V, Baiza-Durán L, et al. (2005) Characterization of the novel ophthalmic drug carrier sophisen in two of its derivatives: 3A Ofteno and Modusik-A Ofteno. *Drug Dev Ind Pharm* 31: 263-269.
- Hingorani M, Moodaley L, Calder VL, Buckley RJ, Lightman S (1998) A randomized placebo-controlled trial of topical cyclosporine A in steroid-dependent atopic dependent atopic keratoconjunctivitis. *Ophthalmology* 105: 1715-1720.
- BenEzra D, Mafzir G (1990) Ocular penetration of cyclosporine A. The rabbit eye. *Inv Ophthalmol Vis Sci* 31: 1362-1366.
- Niederhorn JY (2008) Immune regulatory mechanisms in allergic conjunctivitis: insights from mouse models. *Curr Opin Allergy Clin Immunol* 8: 472-476.
- Akpek EK, Dart JK, Watson S, Christen W, Dursun D, et al. (2004) A randomized trial of topical cyclosporine 0.05% in topical steroid-resistant atopic keratoconjunctivitis. *Ophthalmology* 111: 476-482.
- Quintana-Hau JD, Cruz-Olmos E, Lopez-Sanchez MI, Gonzalez JR, Baiza-Duran L, et al. (2004) In vitro study of corneal retention of Cyclosporine-A from different formulations. *Invest Ophthalmol Vis Sci* 45: E-Abstract 67.
- Bleik JH, Tabbara KF (1991) Topical cyclosporine in vernal keratoconjunctivitis. *Ophthalmology* 98: 1679-1684.
- Kekliki U, Soker SI, Sakalar YB, Unlu K, Ozekinci S, et al. (2008) Efficacy of topical cyclosporine A 0.05% in conjunctival impression cytology specimens and clinical findings of severe vernal keratoconjunctivitis in children. *Jpn J Ophthalmol* 52: 357-362.
- Pucci N, Novembre E, Cianferoni A, Lombardi E, Bernardini R, et al. (2002) Efficacy and safety of cyclosporine eye drops in vernal keratoconjunctivitis. *Ann Allergy Asthma Immunol* 89: 298-303.
- Tesse R, Spadavecchia L, Fanelli P, Rizzo G, Procoli U, et al. (2010) Treatment of severe vernal keratoconjunctivitis with 1% topical cyclosporine in an Italian cohort of 197 children. *Pediatr Allergy Immunol*. 21: 330-335.
- Mendicute J, Aranzasti C, Eder F (1997) Topical cyclosporine A 2% in the treatment of vernal keratoconjunctivitis. *Eye (Lond)* 11: 75-78.
- Tomida I, Schlote T, Bräuning J, Heide PE, Zierhut M (2002) Cyclosporine A 2% eye drops in therapy of atopic and vernal keratoconjunctivitis. *Ophthalmologie* 99: 761-776.
- Ebihara N, Ohashi Y, Uchio E, Okamoto S, Kumagai N, et al. (2009) A large prospective observational study of novel cyclosporine 0.1% aqueous ophthalmic solution in the treatment of severe allergic conjunctivitis. *J Ocul Pharmacol Ther* 25: 365-372.
- Kosirukwongs P, Vichyanond P, Wongsawad W (2003) Vernal keratoconjunctivitis in Thailand. *Asian Pac J Allergy Immunol* 21: 25-30.

