

Henoch-Schönlein Purpura Complicating Acute Osteomyelitis to *Staphylococcus aureus*

Salem Bouomrani^{1,2*} and Moez Ben Ayed^{2,3}

¹Department of Internal Medicine, Military Hospital of Gabes, Gabes, Tunisia

²University of Sfax, Sfax, Tunisia

³Department of Orthopedics, Regional Hospital of Gabes, Gabes, Tunisia

*Corresponding author: Salem Bouomrani, Department of Internal Medicine, Military Hospital of Gabes, Gabes 6000, Tunisia, Tel: +00216 98977555; E-mail: salembouomrani@yahoo.fr

Received date: February 13, 2019; Accepted date: February 21, 2019; Published date: February 28, 2019

Copyright: © 2019 Bouomrani S, et al. This is an open-access article distributed under the terms of the Creative Commons Attribution License; which permits unrestricted use; distribution; and reproduction in any medium; provided the original author and source are credited.

Abstract

Introduction: Henoch-Schönlein Purpura (HSP) is the most common systemic vasculitis in children. The etiology of HSP is still unknown; although various factors have been implicated in the precipitation of the disease such as viruses, group A streptococci, drugs, vaccines, and cancers. *Staphylococcus aureus* (SA) infections are exceptionally found at the origin of this angitis. We report an original case of HSP complicating acute osteomyelitis of the left femur to SA.

Case report: A 15-year-old child was hospitalized for vascular purpura of the lower and upper limbs, associated with diffuse abdominal pain and inflammatory polyarthritis, occurring four weeks after treatment of acute osteomyelitis to SA of the left femoral neck, complicated by coxofemoral arthritis and abscess of the left thigh. Biological, radiological, and histological investigations led to the diagnosis of HSP without renal involvement. The patient was treated with systemic corticosteroid therapy with a good outcome.

Conclusion: Staphylococcal infection is exceptionally found at the origin of HSP. To our knowledge, only two cases of HSP complicating SA osteomyelitis have been reported previously in the world literature.

Keywords: Henoch-Schönlein purpura; Osteomyelitis; *Staphylococcus aureus*; Infection; Vasculitis

Introduction

Henoch-Schönlein Purpura (HSP), better called IgA systemic vasculitis according to the new Chapel Hill consensus conference for vasculitis nomenclature/classification [1], is a primitive systemic angitis with circulating immune complexes of small vessels, which characterized by the presence of immune deposits made of immunoglobulin A (IgA) in the affected tissues (skin, kidneys, vessels, digestive tract,...). It is particularly common in children with a maximal frequency between 4 and 5 years [2,3], whereas it remains exceptional in the adult: the affection is 20 times rarer in the adult compared to the child [4].

It is the most common vasculitis of the child with an estimated incidence of 6.1-55.9/100,000 children according to series and populations [2,3,5]. In children, HSP is usually mild and spontaneously resolving disease; however, severe renal or gastrointestinal complications may occur and affect the prognosis of this angitis [2,3].

The recent terminology of IgA vasculitis seems more appropriate because the clinical spectrum of this entity is highly polymorphic, and purpura is not a constant sign [6,7].

The exact etiology of this disease is still undetermined [2,3,5]. Its etiopathogeny appears to be multifactorial, involving infectious, environmental, drug, and genetic predisposing factors [2,3,6]. Similarly, rare cases of paraneoplastic HSP have been reported [2,3].

Infectious factors, especially an upper respiratory tract infection, prior to HSP are often noted by the majority of authors [2,5,6]. *Staphylococcus aureus* (SA) is, however, only exceptionally reported as a possible etiopathogenic factor for HSP [5,8].

We report an original observation of HSP complicating acute osteomyelitis of the femoral neck to SA in a 15-year-old child.

Case Report

A 15-year-old child with no pathological medical history was treated one month ago for acute osteomyelitis of the left femur to SA with good progress.

The diagnosis of osteomyelitis was based on the following arguments: acute inflammatory pain in the left thigh associated with fever and limping, leukocytosis, marked inflammatory biological syndrome, left femoral neck defect on standard radiographs (Figures 1 and 2) with abscessing of the soft parts of the left thigh and effusion of the left coxofemoral joint (Figure 3), positive haemocultures with methicillin-sensitive *Staphylococcus aureus*, and histological appearance compatible with acute osteomyelitis on bone biopsies. The treatment consisted of methicillin-based anti-staphylococcal antibiotics, surgical drainage, and orthopedic immobilization. The evolution was favorable with apyrexia, the disappearance of the clinical complaints, and negation of the blood cultures. The patient was discharged from the hospital after three weeks of treatment.

He was again admitted after one week for petechial, sloping, infiltrated, and a tender rash of both lower limbs and forearms,

accompanied by fever, diffuse abdominal pain, and inflammatory polyarthritis.

Somatic examination noted fever at 39°C, vascular purpura of both lower limbs and both forearms (Figure 4), arthritis of the left elbow, 15° flexion of the left knee as sequelae of osteomyelitis, and diffuse abdominal tenderness on palpation. There was no evidence of visceromegaly, lymphadenopathy, or gastrointestinal bleeding.

Biology showed leukocytosis at 13,200/mm³, erythrocyte sedimentation rate at 89 mm/H1, thrombocytosis at 605,000/mm³, normochromic normocytic anemia at 9.2 g/dl, and polyclonal hypergammaglobulinemia at 19.9 g/l. The hemostasis tests were without abnormalities and the blood cultures were negative. Infectious, tumoral, and immunological investigations were negative: Rheumatoid factor, antinuclear antibodies, cryoglobulins, viral and bacterial serologies, tumor markers, chest X-ray, abdominal ultrasound, cardiac ultrasonography, and thoracoabdominopelvic computed tomography.

Skin biopsy confirmed the diagnosis of HSP with vasculitis of small vessels and IgA deposits in direct immunofluorescence. Thus the diagnosis of HSP without renal damage was retained (normal creatinine, negative 24h proteinuria, and no abnormalities of urinary sediment).

The patient was initially treated symptomatically, but because of the recrudescence of purpuric rashes and the non-regression of abdominal pain, a systemic corticosteroid treatment at the dose of 1 mg/kg/day was prescribed with a rapidly favorable evolution.

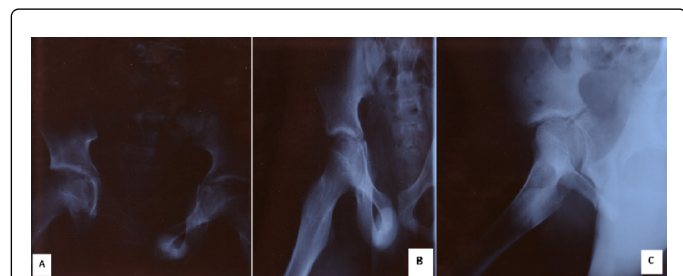

Figure 1: (A) X-ray pelvis of the face (B) Left frontal hip (C) Left ducroquet profile

Upper left femur (femoral neck) lacuna with enlargement of the left coxofemoral articula and the soft parts around the left femoral neck.

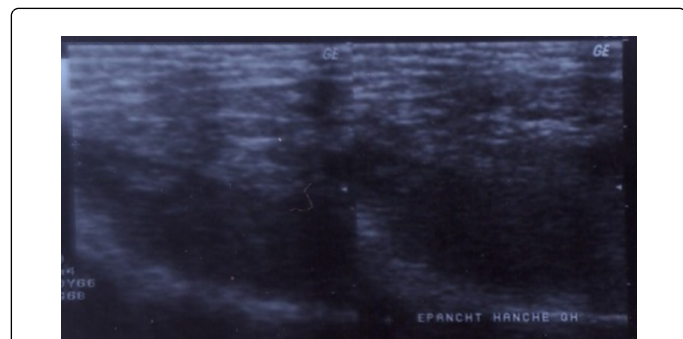


Figure 2: Ultrasound of the left hip- left coxofemoral joint effusion.

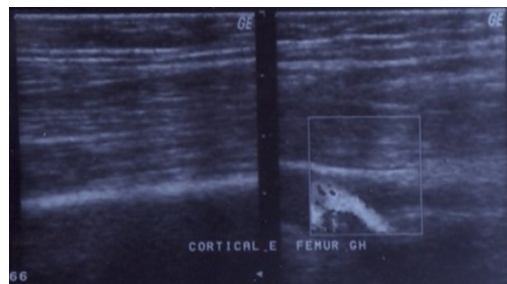


Figure 3: Ultrasonography and Doppler of the soft parts of the thigh- thickening of the cortical bone of the left femur.

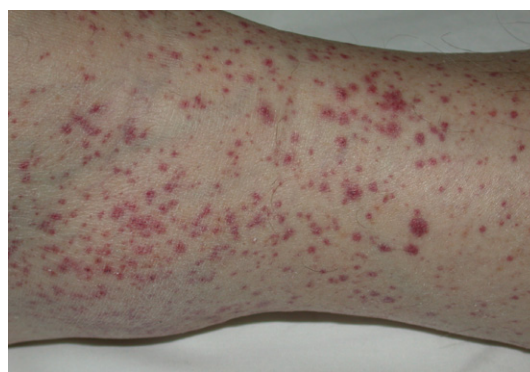

Figure 4: Purpuric rash of the lower left limb.

Discussion

The most incriminated infectious agents in the pathogenesis of this vasculitis are group A streptococcus and parainfluenza virus [2,6]. More rarely, it can be other infectious agents of different types: bacteria, viruses, or parasites [2,5,6].

IgA deposition and circulating immune complexes suggest that HSP is an IgA-mediated dysregulated immune response to an antigen (infectious?, toxic?, Cancer cells?) [2,3,6] in a subject with genetic predisposition and/or human leukocyte antigen haplotypes susceptibility [2,3].

SA is only exceptionally reported as a possible etiopathogenic factor of HSP; it could be both methicillin-resistant or methicillin-sensitive SA [5,8].

The first observation of HSP induced by SA infection was reported in 1987 by Montoliu J et al. [9]. Since then, only sporadic cases of HSP or IgA nephropathy have been reported in the course of SA infections [10,11]. The theory of "*Staphylococcus* superantigens", particularly *Staphylococcus* enterotoxin, was advanced to explain the development of HSP following these infections [10,11]. The good evolution of HSP associated to methicillin-resistant SA infection in the observation of Maliske SM et al., with anti-staphylococcal antibiotic therapy without the use of corticosteroids or immunosuppressants, once again confirms the imputability of this germ in the pathogenesis of this vasculitis [10].

It should also be noted that in adults, systemic infection with methicillin-resistant SA can be complicated by a clinical presentation

called "HSP-like" associating a cutaneous rash and IgA nephropathy (22% of cases in the series of Satoskar AA et al.) [12]. The distinction between the two entities is important to make because therapeutic and prognostic implications are not the same [12].

The association between HSP and osteomyelitis to SA has been reported only twice before [13]. These two cases can be likened to two other observations of IgA nephropathy (an isolated renal form of IgA vasculitis) occurred during the course of chronic osteomyelitis, including one with methicillin-resistant SA, and with a favorable outcome in both cases following adapted medico-surgical treatment of the osteomyelitis [14,15]. Indeed, the secondary evolution of an IgA nephropathy into Henoch-Schönlein purpura is possible [7].

Our observation is to our knowledge the third reporting the association of an HSP with osteomyelitis to SA. It is further characterized by its pediatric character (the two previous observations had occurred in adults).

Conclusion

The occurrence of an authentic HSP in the course of a systemic infection to SA remains exceptional and unusual. This situation represents a real diagnostic challenge for clinicians, especially since severe SA infections may have a clinical presentation simulating HSP (HSP-like syndrome).

Our observation is, to our knowledge, the third reporting an authentic vasculitis type HSP complicating osteomyelitis to SA. It is characterized moreover by its pediatric character.

Conflicts of Interest

None

References

- Holl-Ulrich K (2014) Vasculitis: New nomenclature of the Chapel Hill consensus conference 2012. *Z Rheumatol* 73: 823-833.
- Hetland LE, Susrud KS, Lindahl KH, Bygum A (2017) Henoch-Schönlein purpura: A literature review. *Acta Derm Venereol* 97: 1160-1166.
- Yang HR (2018) What we know about Henoch-Schönlein purpura in children up to date? *J Korean Med Sci* 33: e199.
- Kunicka A, Pruszczyk P, Kryst A (2009) Henoch-Schönlein purpura: an atypical cause of abdominal pain in a 70-year-old man: A case report. *Pol Arch Med Wewn* 119: 509-513.
- Rigante D, Castellazzi L, Bosco A, Esposito S (2013) Is there a crossroad between infections, genetics, and Henoch-Schönlein purpura? *Autoimmun Rev* 12: 1016-1021.
- Guliaev SV, Strizhakov LA, Moiseev SV, Fomin VV (2018) From Schönlein-Henoch purpura to IgA-vasculitis: Pathogenetic aspects of the disease. *Ter Arkh* 90: 109-114.
- Araque A, Sánchez R, Alamo C, Torres N, Praga M (1995) Evolution of immunoglobulin: A nephropathy into Henoch-Schönlein purpura in an adult patient. *Am J Kidney Dis* 25: 340-342.
- Temkiatvises K, Nilanont Y, Pongvarin N (2008) Stroke in Henoch-Schönlein purpura associated with methicillin-resistant *Staphylococcus aureus* septicemia: Report of a case and review of the literature. *J Med Assoc Thai* 91: 1296-1301.
- Montoliu J, Miro JM, Campistol JM (1987) Henoch-Schönlein purpura complicating staphylococcal endocarditis in a heroin addict. *Am J Nephrol* 7: 137-139.
- Maliske SM, Edwards D, Suneja M (2015) Methicillin-resistant *Staphylococcus aureus*-related Henoch-Schönlein Purpura treated without systemic immunosuppressants. *Am J Med Sci* 350: 514-516.
- Uggeri S, Fabbian F, Catizone L (2008) Henoch-Schönlein purpura due to methicillin-sensitive *Staphylococcus aureus* bacteremia from central venous catheterization. *Clin Exp Nephrol* 12: 219-223.
- Satoskar AA, Molenda M, Scipio P, Shim R, Zirwas M, et al. (2013) Henoch-Schönlein purpura-like presentation in IgA-dominant *Staphylococcus* infection-associated glomerulonephritis- a diagnostic pitfall. *Clin Nephrol* 79: 302-312.
- Anegg B, Diem E (1994) Schoenlein-Henoch purpura associated with chronic post-traumatic osteomyelitis. *Hautarzt* 45: 179-183.
- Tevlin MT, Wall BM, Cooke CR (1992) Reversible renal failure due to IgA nephropathy associated with osteomyelitis. *Am J Kidney Dis* 20: 185-188.
- Riley AM, Wall BM, Cooke CR (2009) Favorable outcome after aggressive treatment of infection in a diabetic patient with MRSA-related IgA nephropathy. *Am J Med Sci* 337: 221-223.