

Peripheral Corneal Melt in Rheumatoid Arthritis

Sagili Chandrasekhara Reddy^{1,2*}

¹Department of Ophthalmology, Osmania Medical College & Sarojini Devi Eye Hospital, Hyderabad, Telangana, India

²Department of Ophthalmology, Faculty of Medicine and Defence Health, National Defence, University of Malaysia, Sungai Besi campus, 57000 Kuala Lumpur, Malaysia

*Corresponding author: Dr. Sagili Chandrasekhara Reddy, Department of Ophthalmology, Faculty of Medicine and Defence Health, National Defence University of Malaysia, Sungai Besi campus, Kuala Lumpur, Malaysia, Tel: +6013-6244532; E-mail: profscreddy@gmail.com

Received date: April 09, 2019; Accepted date: June 11, 2019; Published date: June 17, 2019

Copyright: ©2019 Reddy SC, This is an open-access article distributed under the terms of the Creative Commons Attribution License, which permits unrestricted use, distribution, and reproduction in any medium, provided the original author and source are credited.

Abstract

A 38-year-old lady presented with history of redness, blurring of vision, irritation, and photophobia in the left eye of two weeks duration. She gave past history of similar problem in the right eye two years back and the eye became small with loss of vision in spite of taking treatment from an eye specialist. She had joint pains in both knees and wrists for the past four years. Examination of right eye showed phthisis bulbi with no perception of light. Left eye showed peripheral corneal ulcer and thinning of cornea (5-7 o' clock position) with 6/36 vision. She had keratoconjunctivitis sicca also. She was treated with ciprofloxacin, homatropine and carboxymethyl cellulose eye drops. After the investigations for the joint pains, she was diagnosed as a case of rheumatoid arthritis by the physician and started on diclophen and prednisolone tablets. The peripheral corneal ulcer did not respond to treatment; cornea showed melting and mild iris bulge was noted at 6 o'clock position inside the limbus. Intravenous acetazolamide was given and the pupil was constricted with pilocarpine eye drops. Since donor cornea was not available, the conjunctival pedicle graft from the lower bulbar conjunctiva was done under topical anaesthesia and the eye was patched. On the next day, the anterior chamber formed well without any anterior synechiae. Ciprofloxacin eye drops, carboxymethyl cellulose eye drops and tablet acetazolamide were given postoperatively. Patient was discharged three weeks after admission on ciprofloxacin and carboxymethyl cellulose eye drops. She was advised the need of corneal transplantation when donor cornea is available. Unfortunately, she defaulted further follow up after four weeks.

Keywords: Peripheral corneal ulcer; Corneal melt; Rheumatoid arthritis; Conjunctival graft; Keratoconjunctivitis sicca

Introduction

Rheumatoid arthritis (RA) is a chronic systemic autoimmune disease affecting joints as well as extra-articular organs such as the lungs, pericardium, skin and ocular tissues [1]. The most frequent ocular manifestation of rheumatoid arthritis is keratoconjunctivitis sicca; others being episcleritis, scleritis, corneal changes (marginal thinning of cornea, stromal corneal opacities with peripheral vascularization), iridocyclitis and retinal vasculitis [2,3].

Corneal melting is a rare yet devastating extra-articular complication of RA that may progress to corneal perforation. The management of sterile melts associated with RA needs an aggressive systemic control of the disease and surgical intervention to improve the tectonic stability of the cornea and prevent perforations in those presenting with corneal melts. Management of corneal perforation in these patients requires surgical procedures such as corneal cyanoacrylate glue, conjunctival flaps, amniotic membrane grafts or corneal transplants as well as medical therapy including steroids, immunosuppressants and antibiotics [4,5]. The literature search showed only few isolated case reports of corneal melt in rheumatoid arthritis from India [6-8] and other parts of world [9-14]. Therefore, the present case is reported in view of its rarity with a brief review of the literature on this subject.

Case Report

A 38-year-old lady came to the eye clinic with history of redness, blurring of vision, irritation, and photophobia in the left eye of two weeks duration. There was no history of trauma to the left eye. There was no improvement in the eye condition with the treatment taken earlier in a private hospital. She gave past history of similar problem in the right eye two years back and the eye became small with loss of vision in spite of taking treatment from another eye specialist. She is taking treatment for joint pains in both knees and both wrists since 4 years, which was under control with tablets given by a general practitioner. General physical examination was normal. Systemic examination did not reveal any abnormality.

Examination of right eye showed phthisis bulbi with no perception of light. Examination of left eye: Vision was 6/36 which improved to 6/18 with pinhole. Slit lamp examination showed conjunctival congestion, crescent shaped peripheral corneal ulcer, thinning of cornea (5-7 o' clock position) (Figure 1), and positive fluorescein staining at the lower part of limbus. Rest of the cornea, anterior chamber, iris, pupil and lens were normal. Fundus was normal. Intraocular pressure with Tonopen was 18 mm Hg. Lacrimal drainage system was normal. Investigations for keratoconjunctivitis sicca in the left eye were positive (Schirmer test: 5 mm, Tear film break up time: 8 seconds, and Rose Bengal staining: positive in the inter palpebral conjunctiva and corneal ulcer area).

The diagnosis of peripheral corneal ulcer and dry eye was made in the left eye; the patient was admitted for investigations and treatment. She was started on ciprofloxacin eye drops four hourly, homatropine eye drops once daily, carboxy methylcellulose eye drops four hourly in

the left eye, capsule doxycyclin 100 mg two times daily and tablet vitamin C 500 mg daily.

Conjunctival swab for culture was sterile. The results of urinalysis, haematological studies were normal. X-ray of both knees were normal; however, both wrists and hands showed juxta-articular rarefaction of the bones, as well as narrowing of the radiocarpal, intercarpal and metacarpophalyngeal joint spaces on both sides. Erythrocyte sedimentation rate was 65 mm in 1st hour (normal <20 mm in 1st hour – female under 50 years). Rose- Waler test (sheep red blood cell agglutination) for rheumatoid factor was 80 IU/ml (normal <15 IU/ml). She was referred to the physician for evaluation of arthritis.

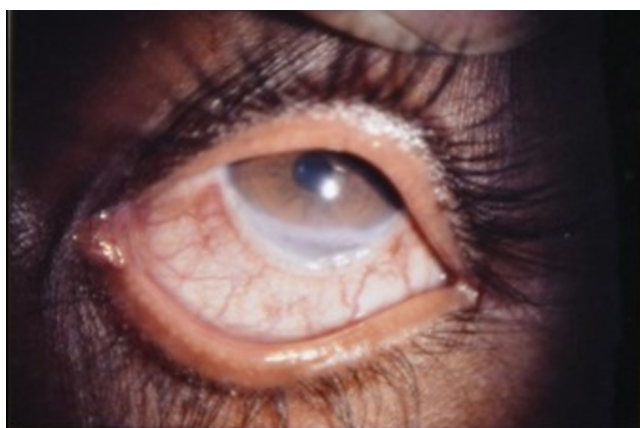


Figure 1: Left eye showing peripheral corneal ulcer with thinning in the lower part.

She was diagnosed as a case of rheumatoid arthritis and tablet diclofen 25 mg two times daily, tablet prednisolone 10 mg four times daily and tablet omeprazole 20 mg two times daily were started for rheumatoid arthritis. Same eye treatment was continued in the left eye. However, the infiltration in the cornea extended towards the central portion and the corneal ulcer did not respond to the treatment. After five days of systemic treatment, cornea showed melting in the lower part with mild iris prolapse at 6 o'clock position inside the limbus (Figure 2).

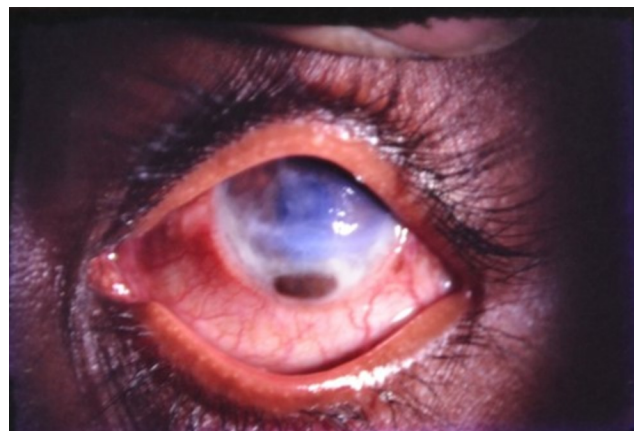


Figure 2: Left eye showing mild iris prolapse at 6 o'clock position due to corneal melt.

Immediately, intravenous acetazolamide 500 mg was given. Homatropine eye drops were stopped in the left eye and the pupil was constricted with pilocarpine eye drops. On the same day, under topical and retrobulbar xylocaine anaesthesia, sodium hyaluronate was injected into anterior chamber through a corneal stab incision on the temporal side. After thorough cleaning of the iris with normal saline, it was separated from the corneal edges. Through the corneal stab incision the iris was repositioned into anterior chamber with the help of sodium hyaluronate over the iris. A pedicle conjunctival graft (5 mm width) from the lower part of conjunctiva (4-8 o'clock) was done in the left eye. The upper margin of the conjunctiva was sutured to the cornea and the lower margin of conjunctiva to the sclera with multiple 10-0 nylon sutures. The viscoelastic was replaced with normal saline in the anterior chamber. Bandage contact lens was applied; ciprofloxacin eye drops were put and the left eye was patched.

On the next day, the anterior chamber was formed well without any anterior synechiae. Post operatively, ciprofloxacin eye drops and carboxymethyl cellulose eye drops were given four hourly in the left eye; tablet acetazolamide 250 mg was given two times daily for one week. Bandage contact lens was removed after 96 hours. Same treatment was continued. Sutures were removed after seven days. On the next day, the patient was discharged on ciprofloxacin eye drops and carboxymethyl cellulose eye drops four times daily in the left eye; and tablet vitamin C 500 mg daily. In the two weeks follow up visit, the vision was 6/60 which improved to 6/36 with pinhole; corneal haziness was less and the conjunctival graft was taken up well (Figure 3). She was advised the need of corneal transplantation when donor cornea is available. Unfortunately, she defaulted further follow up after four weeks.

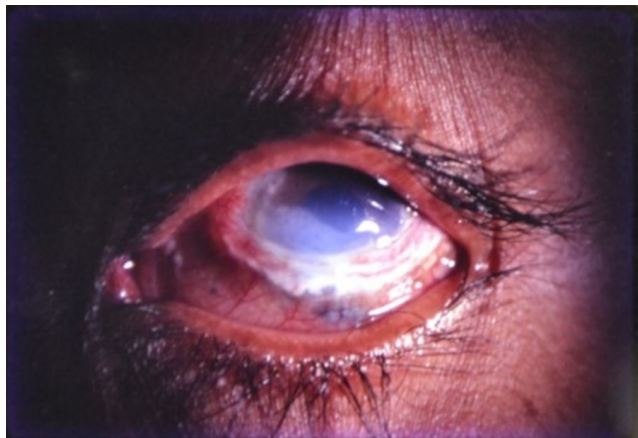

Figure 3: Left eye showing less corneal haziness and well taken up conjunctival graft.

Discussion

Peripheral corneal ulcer/ulcerative keratitis is characterized by inflammation involving the limbal part of the cornea, collagen destruction, cellular infiltration and limbal vascular changes indicating vasculitis [5]. Usually, it is a unilateral crescent-shaped stromal inflammation, which involves juxtalimbal area and is characterized by sectorial thinning of the affected area. It is always associated with overlying epithelial defect and progressive loss of corneal stroma [15]. They usually remain indolent, but when they progress to extreme thinning perforation of cornea is precipitated. The literature search showed only handful of case series documenting the presenting features and outcome of keratolysis (sterile corneal melt)/corneal melt associated with rheumatoid arthritis [5,8,16-18].

McKibbin et al. [19] reported rheumatoid arthritis as an associated systemic disease in 15 out of 27 (55%) patients with corneal melting in the Yorkshire region. In a retrospective study of 38 patients of RA who presented with keratolysis (sterile melting of cornea), aged 50-93 years and duration of arthritis 6-60 years, Malik et al [16] reported bilateral simultaneous corneal lesions in two patients (total 40 eyes). Fifty five percent (55%) of ulcers were peripheral, 25% were paracentral, 17% were central and 3% were limbal. There was evidence of dry eye in 71% of patients, previous keratolysis in the affected eye or fellow eye in 50%, concurrent limbal inflammation in 8%, preceding scleritis in 2.7% of patients.

In rheumatoid arthritis, the ulcerative keratitis tends to develop more frequently in the peripheral cornea due to its denser vasculature which facilitates the infiltration of the inflammatory cells, as compared to the central avascular cornea. The pathogenesis of corneal melting is poorly understood. Leucocyte chemotaxis and release of lysozyme enzymes such as collagenases and proteases which destroy the corneal collagen and proteoglycans were suggested to have key role in corneal melting in rheumatoid arthritis [7]. Evidence of immune mediated vascular occlusive disease was revealed in the biopsy of conjunctival tissue adjacent to the zone of corneal melting [20].

Fujita et al. [21] reported that in rheumatoid arthritis, severe xerosis associated with Sjogren's disease can contribute to development of corneal melting. Local imbalance between levels of a specific

collagenase (MMP-1) and its tissue inhibitor (TIMP-1) causing rapid keratolysis was attributed in rheumatoid associated corneal ulcers, causing keratolysis [5]. Smith et al. [22] suggested that overproduction of MMP-2 in the corneal stroma and MMP-9 in the lacrimal glands may cause keratocyte collagen degradation.

Peripheral ulcerative keratitis 'corneal melt' was seen usually in seropositive RA patients with longstanding arthritis, presence of vasculitis locally and systemically [5]. However, Singh et al. [13] reported a case of seropositive RA with corneal melting in the absence of other manifestations of arthritis flare, but the corneal was associated with methicillin resistant staphylococcus aureus.

Management of corneal melt/perforation in these patients requires surgical procedures such as corneal cyanoacrylate glue with contact lens, conjunctival flaps, amniotic membrane grafts or corneal transplants as well as medical therapy including systemic steroids, immunosuppressants (azathioprine, methotrexate, cyclophosphamide and cyclosporine) and antibiotics [4,5,16,23]. Visual prognosis is often poor, although surgical preservation of the eye is achieved by lamellar or penetrating keratoplasty [16]. However, remelting or recurrence of keratolysis after the initial episode resolved has been reported after surgical treatment in these patients [16,23].

In the present patient, she had features of peripheral ulcerative keratitis with corneal thinning and keratoconjunctivitis sicca, but no scleritis in the left eye. The conjunctival swab culture was sterile. The clinical features of RA were not aggressive. The patient was treated with systemic corticosteroids and conjunctival flap surgery. The condition of the eye was improved and the structure of the globe was maintained well. However, the haziness of cornea did not clear during the short follow up period. The past history given by the patient that the right eye became small with loss of vision in spite of the treatment suggests the possibility of similar nature of the disease in the right which caused perforation of the ulcer and finally phthisis bulbi.

Conclusion

Corneal melting is a rare but dangerous ocular complication of rheumatoid arthritis, associated with poor visual prognosis. Rapid course of the disease which depends on its severity makes every case a challenge. In some patients, corneal melting can occur in the absence of active arthritis and despite the use of potent anti-rheumatic drugs. Therefore, cooperation between rheumatologist and ophthalmologist is crucial, because aggressive medical management along with proper surgical intervention are the best treatment options in rheumatoid arthritis related corneal melting.

References

1. Majitha V, Geraci SA (2007) Rheumatoid arthritis: diagnosis and management. *Am J Med* 120: 936-939.
2. Reddy SC, Rao UR (1996) Ocular complications of adult rheumatoid arthritis. *Rheumatol Int* 16: 49-52.
3. Zlatanovic G, Veselinovic D, Cekic S, Zivkovic M, Dordevic-Joic J, et al. (2010) Ocular manifestation of rheumatoid arthritis-different forms and frequency. *Bosn J Basic Med Sci* 10: 323-327.
4. Alino AM, Perry HD, Kanellopoulos AJ, Donnenfeld ED, Rahn EK (1998) Conjunctival flaps. *Ophthalmology* 105: 1120-1123.
5. Squirrel DM, Winfield J, Amos RS (1993) Peripheral ulcerative keratitis 'corneal melt' and rheumatoid arthritis: a case series. *Rheumatology* 38: 1245-1248.

6. Mohan M, Panda A, Pattnaik NK, Dada VK (1984) Corneomalacia perforans in a patient with rheumatoid arthritis. *Can J Ophthalmol* 19: 237-239.
7. Gokhle NS (1997) Rheumatoid corneal melting. *Indian J Ophthalmol* 45:238-239.
8. Sule A, Balakrishnan C, Gaitonde S, Mittal G, Pathan E, et al. (2002) Rheumatoid corneal melt. *Rheumatology* 41: 705-706.
9. Scharf Y, Meyer E, Nahir M, Zonis S (1984) Marginal melting of cornea in rheumatoid arthritis. *Ann Ophthalmol* 16: 924-926.
10. Williams GP, Denniston AKO, Elamanchi SR, Rauz S (2011) Rheumatoid corneal melt:autoimmunity or infection? *J R Soc Med Sh Rep* 2: 1.
11. Antao SF, Ayoub T, Tahir H, Parmar DN (2012) Stabilization of bilateral progressive rheumatoid corneal melt with Infliximab. *Case Reports in Ophthalmological Medicine* 2012: 173793.
12. Karampatakis V, Konodaris V, Michalidou M, Gerofotis A, Daniilidis M (2013) Peripheral corneal ulceration associated with rheumatoid arthritis. *Am J Case Rep* 14: 318-321.
13. Singh G, Salvador VB, Bagchi A, Tushabe R, Abrudescu A (2014) Rheumatoid arthritis-associated corneal ulceration with superimposed infection by methicillin-resistant staphylococcus aureus: A complete type of corneal melt. *Am J Case Rep* 15: 523-525.
14. Mimer M, Janczak D, Hill-Bator A, Sehbastian A, Wiland G, et al. (2016) Management of corneal melting in a patient with long-standing rheumatoid arthritis- case report. *Klinika Oczna* 118: 235-237.
15. Galor A, Thorne JE (2007) Scleritis and peripheral ulcerative keratitis. *Rheum Dis Clin N A*, 33: 835-854.
16. Malik R, Culinane AB, Tole DM, Cook SD (2006) Rheumatoid keratolysis: a series of 40 eyes. *Eur J Ophthalmol* 16: 791-797.
17. Knox Cartwright Ne, Tole DM, Georgoudis P, Cook SD (2014) Peripheral ulcerative keratitis and corneal melt: a 10-year single center review with historical comparison. *Cornea* 33: 27-31.
18. Livny E, Mimouni M, Bahar I, Molad Y, Gershoni A, et al. (2018) Corneal melting in rheumatoid arthritis treated with a tectonic reinforcing corneoscleral graft: an interventional case series. *Int Ophthalmol* 38: 1317-1324.
19. McKibbin M, Issacs JD, Morrell AJ (1999) Incidence of corneal melting in association with systemic diseases in the Yorkshire region. *Br J Ophthalmol* 83: 941-943.
20. Scharf Y, Meyer E, Nahir M, Zonis S (1984) Marginal melting of cornea in rheumatoid arthritis. *Ann Ophthalmol* 16: 924-926.
21. Fujita M, Igarashi T, Kurai T, Sakane M, Yoshino S, et al. (2005) Correlation between dry eye and rheumatoid arthritis activity. *Am j Ophthalmol* 140: 808-813.
22. Smith VA, Hoh HB, Estly DL (1999) Role of ocular matrix metallo proteinases in peripheral ulcerative keratitis. *Br J Ophthalmol* 83: 1376-1383.
23. Bernauer W, Ficker LA, Watson PG, Dart JK (1995) The management of corneal perforations associated with rheumatoid arthritis. An analysis of 32 eyes. *Ophthalmology* 102: 1325-1337.