

Selective Median, Ulnar and Superficial Branch of the Radial Nerve Blockade with Liposomal Bupivacaine for Postoperative Analgesia in a Super-Super Morbidly Obese Patient

Ryan Rihani^{*}, Johanna B DeHaan and Nadia Hernandez

Department of Anesthesiology, University of Texas Health Science Center at Houston, Texas, USA

***Corresponding author:** Dr Ryan Rihani, Department of Anesthesiology, University of Texas Health Science Center at Houston, Texas, USA, Tel: 281-827-8566; E-mail: ryan.j.rihani@uth.tmc.edu

Received date: August 12, 2019; **Accepted date:** August 22, 2019; **Published date:** August 29, 2019

Copyright: © 2019 Rihani R, et al. This is an open-access article distributed under the terms of the Creative Commons Attribution License, which permits unrestricted use, distribution, and reproduction in any medium, provided the original author and source are credited.

Abstract

Regional anesthesia has become a mainstay for post-surgical pain control, especially in upper extremity surgery. Peripheral nerve blocks have improved quality of recovery by improving pain control, decreasing or eliminating narcotics with associated side effects, and shortening hospital length of stay. Some situations hinder the anesthesiologist's ability to approach the nerve for blockade using standard techniques, such as poly-trauma hindering positioning due to pain and access due to braces or dressings, infections or wounds at the site of needle entry. Other conditions contribute to the avoidance of brachial plexus blocks such as body habitus and significant pulmonary or cardiovascular disease due to the high likelihood of phrenic nerve paralysis in most brachial plexus blocks. While alternatives to brachial plexus block exist, their use is limited due to the short duration of action of field blocks. In this case report, we discuss the utility of selective median, ulnar and superficial branch of radial nerve blockade with liposomal bupivacaine for extended post-operative analgesia in a super-super morbidly obese patient with multiple comorbidities. This patient's case supports the utility of isolated nerve blocks in patients with severe upper extremity pain with contraindications to brachial plexus blocks.

Keywords: Regional anesthesia; Post-surgical pain; Post-surgical pain

Introduction

Regional anesthesia has become a mainstay for post-surgical pain control, especially in upper extremity surgery. The utility of the brachial plexus block has been supported throughout the literature for decades [1,2]. By providing intra-operative and post-surgical analgesia, peripheral nerve blocks have allowed for advances in ambulatory surgery due to decreased times to discharge secondary to improved pain control and decreased narcotic usage [3]. Some situations hinder the anesthesiologist's ability to approach the nerve for blockade using typical techniques, such as poly-trauma patients with multiple sites of injury, morbid obesity, infections or wounds at the site of needle entry. Contraindications can include significant pulmonary or cardiovascular disease, cellulitis or abscess over the site of needle entry, allergy to local anesthetic, super morbid obesity, and of course patient refusal [4]. Other patients possess contraindications to the use of high brachial plexus blocks due to the close proximity of the phrenic nerve and the potentially deleterious effects of hemidiaphragmatic paresis. The incidence of hemidiaphragmatic paresis has been reported to be as high as 100% for interscalene blocks [5,6], 50% for supraclavicular blocks [7,8], and 25% for infraclavicular blocks [9]. For most healthy patients, unilateral phrenic nerve palsy does not result in clinically significant respiratory dysfunction, however, some medically complicated may develop acute respiratory distress. We report a case of a morbidly obese patient with a complex medical history and the utility of ultrasound-guided isolated radial, median and ulnar nerve blocks using liposomal bupivacaine for post-surgical pain control.

Case Report

A 44-year-old, 174 kg (BMI 66) woman with heart failure secondary to non-ischemic cardiomyopathy, left ventricular ejection fraction (LVEF) of 20-25% and severe mitral regurgitation, prior episodes of ventricular tachycardia and ventricular fibrillation status post automated internal cardiac defibrillator (AICD) implantation, and a history of chronic hypoxemic respiratory failure on 2 liters per minute supplementary home oxygen presented for left mini thoracotomy for epicardial lead replacement for her AICD. The cardiovascular anesthesiologist elected to perform the operation under general anesthesia (GA) with the patient in the supine position. Intraoperatively, endotracheal intubation proved difficult and traumatic, requiring 3 attempts at laryngoscopy with a video-laryngoscope. Arterial line placement was challenging, with more than 5 attempts on each arm, until the right brachial artery was finally successfully accessed. The surgical procedure was completed without complication. On emergence the patient could not generate adequate tidal volumes for extubation, and she remained intubated and transferred to the heart failure intensive care unit (HFICU). Upon extubation on post-operative day one, she began noticing pain and swelling in her left wrist and shoulder. A chest x-ray revealed a left anterior fracture-dislocation of the humeral head and a left distal radius fracture that occurred during positioning under general anesthesia. She was taken back to the operating room for open reduction and internal fixation (ORIF) of the left radius with closed reduction of the left humerus under GA and did not meet extubation criteria, so she returned to the HFICU intubated and sedated. On post-operative day 2, she was extubated, and the acute pain service was consulted for narcotic sparing pain control. The complicated medical history had made medical management of pain difficult for the HFICU

team, who had been unable to wean her off of intravenous (IV) hydromorphone. She was requiring IV hydromorphone 0.4 milligrams (mg) every 4 hours and hydrocodone-acetaminophen 10/325 one to two tablets every 6 hours for adequate pain control. When the patient was first examined by the acute pain service, she was dyspneic on 3 liters per minute (L/min) of supplementary oxygen via nasal cannula (NC) and maintaining position of her left arm close to her chest, using an abdominal binder around the arm as a sling (Figure 1). Her body habitus and history of chronic respiratory failure put her at risk for respiratory distress, and the need for reintubation in the setting of prior difficult intubation. Emergent difficult airway management was likely if either left hemidiaphragmatic paresis or over-narcotization occurred.

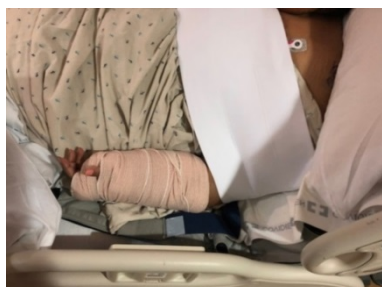

Figure 1: Shown is the position of the patient with the cast and binder in place over the left upper extremity.

These considerations called for an alternative to high brachial plexus blockade that could provide prolonged adequate analgesia without hemidiaphragmatic paresis. The first choice was an axillary brachial plexus block for wrist analgesia with the addition of a suprascapular nerve block for proximal humerus analgesia; both of these techniques have no reported cases of phrenic nerve involvement in the literature [6,10,11]. However, this patient was in significant pain and refused to move her arm away from her chest. Her body habitus also made positioning extremely difficult, as can be seen in Figures 1 and 2.

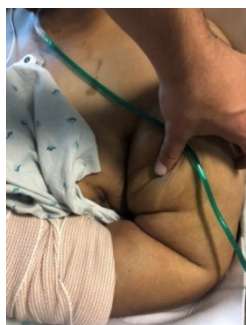

Figure 2: The position of the patient's arm after the abdominal binder was removed from the arm, and the subcutaneous fat of the upper arm was retracted. Patient in pain and unwilling to move her arm away from her side, even with help.

The patient was unable to abduct or externally rotate the arm for axillary brachial plexus block; isolated blockade of the left superficial branch of the radial, ulnar and median nerves was performed, just distal to the antecubital fossa. The first of these nerves to be identified

was the left superficial branch of the radial nerve, as this provides the sensory innervation of the radial head and dorsum of the hand, which ran adjacent to the radial artery [12]. Figure 3 shows the ultrasound image of the left superficial branch of the radial nerve blockade with a 21-gauge echogenic blunt-tipped needle (BBraun, Bethlehem, Pennsylvania, USA) using an in-plane technique and a high-frequency linear ultrasound probe (Sonosite, Bothell, Washington, USA) placed in a transverse orientation 1-2 cm distal to the antecubital fossa.

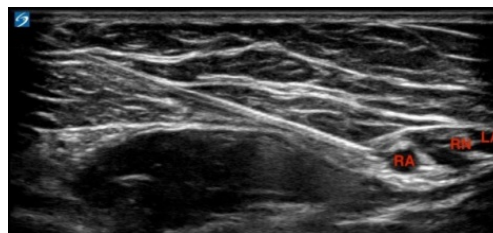


Figure 3: This shows the superficial branch of the radial nerve (RN) running alongside the radial artery (RA). Also seen is the local anesthetic (LA) spreading around the nerve and artery. The nerve was approached from lateral to medial with the LUE held close to the chest in pronation. The tip of the needle can be seen entering the neurovascular bundle about 1-2 cm distal to the antecubital fossa.

The ulnar nerve was found by tracing the ulnar artery proximally from the patient's cast until it separated from the ulnar nerve. This ultrasound image can be seen in Figure 4. Finally, the median nerve was found by identifying the brachial artery in the antecubital fossa and following it immediately distal to the fossa. The ultrasound imaging can be seen in Figure 5. Each block was performed with 3 mL of 0.25% bupivacaine hydrochloride with 3 mL of 1.3% liposomal bupivacaine. The patient reported experiencing anesthesia of her wrist and hand within 25 minutes of the block procedure and stated the anesthesia and associated pain relief lasted nearly 22 hours.

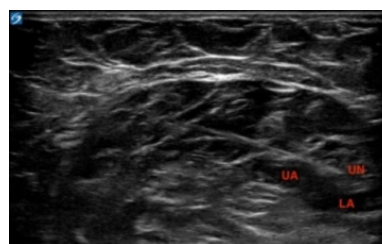


Figure 4: This shows the ulnar nerve (UN) separated from the ulnar artery (UA), which runs closer to the ulnar artery as you scan distally along the arm using a high-frequency linear ultrasound probe in a transverse position (Sonosite, Bothell, Washington, USA). However, in this image, 2 cm distal to the antecubital fossa, the UN has separated from the UA, allowing for an easier needle approach. The 21-gauge echogenic blunt-tipped needle (BBraun, Bethlehem, Pennsylvania, USA) was advanced in-plane from lateral to medial.

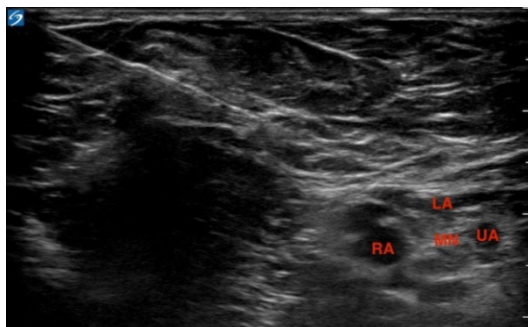


Figure 5: The median nerve (MN) can be seen here running along the radial (RA) and ulnar (UA) arteries which have just branched off of the brachial artery. Local anesthetic (LA) can be seen around the median nerve. This block was also performed using an in-plane technique, with the needle advanced from lateral to medial, entering the neurovascular bundle just superficial to the RA.

Analgesia of the proximal humerus fracture was unable to be provided via peripheral nerve blockade due to patient refusal to reposition for this procedure. Therefore, analgesia was provided to the proximal humerus using a medication regimen consisting of: 1 gm acetaminophen every 6 hours, gabapentin 300mg every 8 hours, oxycodone 10-15 mg every 4 hours as needed, and a once daily rescue dose of IV hydromorphone. The patient was also offered tramadol, but refused it due to a history of side effects. She was weaned off her IV hydromorphone the day following the nerve blocks and found her pain to be better controlled with oral (PO) medications.

Discussion

This case report provides an example of a patient in which nontraditional regional techniques were used due to contraindications to high brachial plexus blockade and inability to position for axillary brachial plexus block and suprascapular blocks. The upper extremity is innervated by the brachial plexus and the intercostobrachial nerve. Choices for peripheral nerve blockade of the upper extremity are limited to brachial plexus and selective terminal branches of the brachial plexus which are field blocks and have a limited duration of action of 6 to 8 hours. Because this was the only technique we could offer to this patient, liposomal bupivacaine was chosen for this procedure as the duration of subcutaneous infiltration has been reported to last up to 72 hours [13].

The extent of the clinical effects of hemidiaphragmatic paresis on respiratory function is determined by the patient's baseline pulmonary status [14]. The diaphragm accounts for 75% of inspiration, while the intercostal, scalene and sternocleidomastoid muscles account for the other 25% [15]. Unilateral phrenic nerve palsy after interscalene block reduces the forced expiratory volume in 1 second (FEV1) by 16 to 40%, the forced vital capacity by 13 to 40%, and the peak expiratory flow rates by 15 to 43% [16,17]. Therefore, loss of a hemidiaphragm can significantly affect respiratory mechanics and ability to maintain acceptable oxygen saturation. In one study, brief episodes of oxygen saturation less than 85% following interscalene block with 20-28 mL of 0.25% bupivacaine hydrochloride were seen in 4 out of 10 patients, 3 of whom were obese [18]. Several case reports have also been published which report symptomatic dyspnea and clinically significant

hypoxemia, and each one of the reported patients was obese; several also had underlying pulmonary disease [19-26].

Conclusion

This case supports the utility of isolated nerve blocks in patients who have relative contraindications to the use of brachial plexus blocks. Isolated nerve blocks are a useful technique for anesthesiologists to remember when treating a patient with contraindications to blockade at the brachial plexus.

References

1. Singelyn FJ, Deyaert M, Joris D, Pendeville E, Gouverneur JM (1998) Effects of intravenous patient-controlled analgesia with morphine, continuous epidural analgesia, and continuous three-in-one block on postoperative pain and knee rehabilitation after unilateral total knee arthroplasty. *Anesth Analg* 87: 88-92.
2. Capdevila X, Barthelet Y, Biboulet P, Ryckwaert Y, Rubenovitch J, et al. (1999) Effects of perioperative analgesic technique on the surgical outcome and duration of rehabilitation after major knee surgery. *Anesthesiology* 91: 8-15.
3. Hebl JR, Dilger JA, Byer DE, Kopp SL, Stevens SR, et al. (2008) A preemptive multimodal pathway featuring peripheral nerve block improves perioperative outcomes after major orthopedic surgery. *Reg Anesth Pain Med* 33: 510-517.
4. Pester JM, Dulebohn SC. Brachial Plexus Block. In: StatPearls [Internet]. Treasure Island (FL): StatPearls Publishing; 2018.
5. Available from: <https://www.ncbi.nlm.nih.gov/books/NBK470213/>
6. Urmey WF, McDonald M (1992) Hemidiaphragmatic paresis during interscalene brachial plexus block: Effects on pulmonary function and chest wall mechanics. *Anesth Analg* 74: 352-357.
7. Urmey WF, Talts KH, Sharrock NE (1991) One hundred percent incidence of hemidiaphragmatic paresis associated with interscalene brachial plexus anesthesia as diagnosed by ultrasonography. *Anesth Analg* 72: 498-503.
8. Neal JM, Moore JM, Kopacz DJ, Liu SS, Kramer DJ, et al. (1998) Quantitative analysis of respiratory, motor, and sensory function after supraclavicular block. *Anesth Analg* 86: 1239-1244.
9. Mak PH, Irwin MG, Ooi CG, Chow BF (2001) Incidence of diaphragmatic paralysis following supraclavicular brachial plexus block and its effect on pulmonary function. *Anaesthesia* 56: 352-356.
10. Rettig HC, Gielen MJ, Boersma E, Klein J, Groen GJ (2005) Vertical infraclavicular block of the brachial plexus: Effects on hemidiaphragmatic movement and ventilatory function. *Reg Anesth Pain Med* 30: 529-535.
11. Shanahan EM, Shanahan KR, Hill CL, Ahern MJ, Smith MD (2012) Safety and acceptability of suprascapular nerve block in rheumatology patients. *Clin Rheumatol* 31: 145-149.
12. Checcucci G, Allegra A, Bigazzi P, Giancesello L, Ceruso M, et al. (2008) A new technique for regional anesthesia for arthroscopic shoulder surgery based on a suprascapular nerve block and an axillary nerve block: An evaluation of the first results. *Arthroscopy* 24: 689-696.
13. Hasenkam CS, Hoy GA, Soeding PF (2017) Sensory distribution of the lateral cutaneous nerve of forearm after ultrasound-guided block: potential implications for thumb-base surgery. *Reg Anesth Pain Med* 42: 478-482.
14. Hadzic A, Abikhaled JA, Harmon WJ (2015) Impact of volume expansion on the efficacy and pharmacokinetics of liposome bupivacaine. *Local Reg Anesth* 8: 105-111.
15. Hartrick CT, Tang YS, Siwek D, Murray R, Hunstad D, et al. (2012) The effect of initial local anesthetic dose with continuous interscalene analgesia on postoperative pain and diaphragmatic function in patients undergoing arthroscopic shoulder surgery: A double-blind, randomized controlled trial. *BMC Anesthesiol* 12: 6.

16. El-Boghdadly K, Chin KJ, Chan VW (2017) Phrenic nerve palsy and regional anesthesia for shoulder surgery: Anatomical, physiologic, and clinical considerations. *Anesthesiology* 127: 173-191.
17. Al-Kaisy AA, Chan VW, Perlas A (1999) Respiratory effects of low-dose bupivacaine interscalene block. *Br J Anaesth* 82: 217-220.
18. Wiesmann T, Feldmann C, Müller HH, Nentwig L, Beermann A, et al. (2016) Phrenic palsy and analgesic quality of continuous supraclavicular vs. interscalene plexus blocks after shoulder surgery. *Acta Anaesthesiol Scand* 60: 1142-1151.
19. Pere P, Pitkänen M, Rosenberg PH, Björkenheim JM, Linden H, et al. (1992) Effect of continuous interscalene brachial plexus block on diaphragm motion and on ventilatory function. *Acta Anaesthesiol Scand* 36: 53-57.
20. Rau RH, Chan YL, Chuang HI, Cheng CR, Wong KL, et al. (1997) Dyspnea resulting from phrenic nerve paralysis after an interscalene brachial plexus block in an obese male: A case report. *Acta Anaesthesiol Sin* 35: 113-118.
21. Minett DM, Nace JE, Nomura JT (2011) Hypoxic respiratory failure due to phrenic nerve palsy from an interscalene brachial plexus block and previously asymptomatic pulmonary embolism. *Crit Ultra J* 3: 105-107.
22. Erickson JM, Louis DS, Naughton NN (2009) Symptomatic phrenic nerve palsy after supraclavicular block in an obese man. *Orthopedics* 32: 368.
23. Cangiani LH, Edwards Rezende LA, Giancoli Neto A (2008) Phrenic nerve block after interscalene brachial plexus block. *Rev Bras Anesthesiol* 58: 152-159.
24. Raymond CS, Borel JC, Wuyam B, Gil P, Payen JF, et al. (2008) Persistent phrenic nerve palsy following interscalene block, leading to chronic respiratory insufficiency and requiring long term non-invasive ventilation. *Respir Med CME* 1: 253-255.
25. Fujimura N, Namba H, Tsunoda K, Kawamata T, Taki K, et al. A Effect of hemidiaphragmatic paresis caused by interscalene brachial plexus block on breathing pattern, chest wall mechanics, and arterial blood gases. *Anesth Analg* 1995; 81: 962-966.
26. Efthimiou J, McLelland J, Round J, Gibbin HR, Loh L, et al. (1987) Diaphragm paralysis causing ventilatory failure in an adult with rigid spine syndrome. *Am Rev Respir Dis* 136: 1483-1485.