

Radiation Maculopathy Treated with Ranibizumab

Alex Yuan and Rishi P. Singh*

Cole Eye Institute, Cleveland Clinic, Cleveland, OH, USA

Abstract

Aim: Radiation maculopathy is a major cause of vision loss after brachytherapy or localized radiation treatments. Here, we describe a case report of a patient with bilateral radiation maculopathy and macular edema treated with ranibizumab and panretinal laser photocoagulation.

Methods: Baseline fluorescein angiography and spectral domain OCT (SDOCT) was obtained. Eight-monthly intravitreal injections of ranibizumab 0.5mg were performed in each eye. Snellen visual acuity, central subfield thickness (CST), total cube volume (TCV), cube average thickness (CAT) was recorded and a fundoscopic exam was performed at each visit. A final fluorescein angiography was obtained at the final visit.

Results: After 8 treatments of ranibizumab 0.5mg, Snellen visual acuity was 20/200 OD and 20/40 OS. The final CST was 392 μ m OD and 495 μ m OS, TCV was 13.4mm³ OD and 11.1mm³ OS, and CAT was 371 μ m OD and 310 μ m OS. Fundus photography and fluorescein angiography showed stabilization of radiation maculopathy OU but prominent macular ischemia OD.

Conclusion: Vision loss from radiation maculopathy can be successfully treated with off-label ranibizumab in the short term. However, visual improvement is limited by macular ischemia, which had a larger effect on final visual acuity than reductions in CST, TCV, or CAT. Our study and others suggest that larger clinical trials to determine the dose, timing, and duration of ranibizumab treatment could benefit patients with radiation maculopathy.

Keywords: Radiation maculopathy; Macular edema; Ranibizumab; Anti-VEGF

Introduction

Radiation maculopathy is a common cause of vision loss after localized radiotherapy for ocular tumors as well as regional or whole brain radiation. Treatments such as focal macular laser [1], scatter laser photocoagulation [2], hyperbaric oxygen [3], periocular and intraocular steroids [4,5], and anti-VEGF agents [6-8] have all been attempted with variable success [9,10].

We describe a report of a 49 year old female with a history of metastatic breast cancer status post whole brain radiation (11/2006, 30 Gy) and gamma knife radiotherapy (5/2007, 72 Gy and 4/2008, 150 Gy) who developed radiation maculopathy. She was initially treated with panretinal photocoagulation without improvement in vision, followed by intravitreal ranibizumab in both eyes with subsequent stabilization in maculopathy and improvement in visual acuity in one eye.

Methods

Bilateral intravitreal injections of ranibizumab 0.5mg were given to both eyes at each visit. Standard sterile technique was used and each eye was separately prepped. The patient returned every 4 weeks for repeat examination, OCT, and injection of ranibizumab. A total of 8 serial bilateral injections were given. Fluorescein angiography was performed at the onset of vision loss and at the last visit.

Results

Our patient was initially referred to our clinic by her oncologist after receiving whole brain radiation and gamma knife radiotherapy. Her baseline Snellen visual acuity was 20/25 OU. Her exam was significant for mild posterior subcapsular cataracts OU, cotton wool spots, and intraretinal hemorrhages consistent with radiation maculopathy OU. She was followed for several months with stable exams until 11/24/2009 when she presented with complaints of blurry vision. Snellen visual acuity declined to 20/80 OD and 20/50 OS. Her cataracts were stable,

but fundoscopic exam revealed worsening radiation maculopathy including a patch of hemorrhage over the fovea OD, lipid exudates, and macular edema OU (Figure 1a). SDOCT revealed the presence of sub retinal fluid, loss of the foveal contour, and cystoid macular edema OU (Figure 1b). The CST was measured at 575 μ m OD and 452 μ m OS, TCV was 14.3mm³ OD and 11.6mm³ OS, and CAT was 396 μ m OD and 321 μ m OS. Fluorescein angiography revealed macular ischemia, microaneurysms, telangiectatic vessels, and angiographic edema OU (Figure 1c).

The patient was initially treated with panretinal laser photocoagulation. Vision continued to decline to 20/200 OD and 20/80 OS, the presence of subretinal fluid and cystoid edema on SDOCT remained essentially unchanged but TCV and CAT increased to 16.8mm³ and 467 μ m OD, and 13.0mm³ and 360 μ m OS (Figure 2a). CST improved to 423 μ m OS, but worsened to 630 μ m OD (Figure 2a). Due to her declining vision OU, bilateral intravitreal injections of ranibizumab were attempted based on the hypothesis that macular edema was in response to increased vascular endothelial growth factor (VEGF) levels and that laser photocoagulation treatment was not sufficient to decrease the ischemic stimulus for VEGF rapidly.

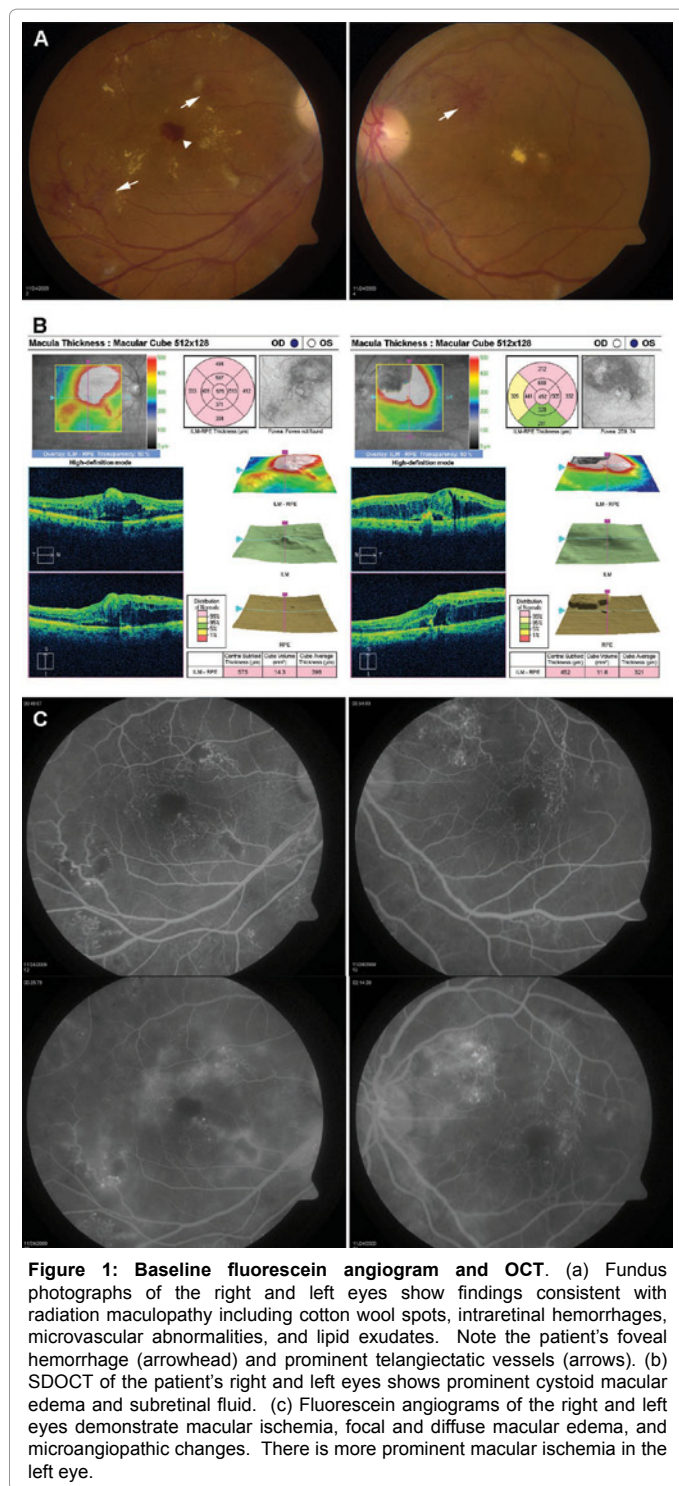
After two injections of ranibizumab, her vision improved to 20/60 OS and remained stable at 20/200 OD. SDOCT showed improvement

*Corresponding author: P. Singh, Cole Eye Institute, Cleveland Clinic, 9500 Euclid Ave i31, Cleveland, OH, 44195, USA, Tel: 216-445-9497; E-mail: singhr@ccf.org

Received December 23, 2010; Accepted February 09, 2011; Published February 11, 2011

Citation: Yuan A, Singh RP (2011) Radiation Maculopathy Treated with Ranibizumab. J Clin Exp Ophthalmol 2:129. doi:10.4172/2155-9570.1000129

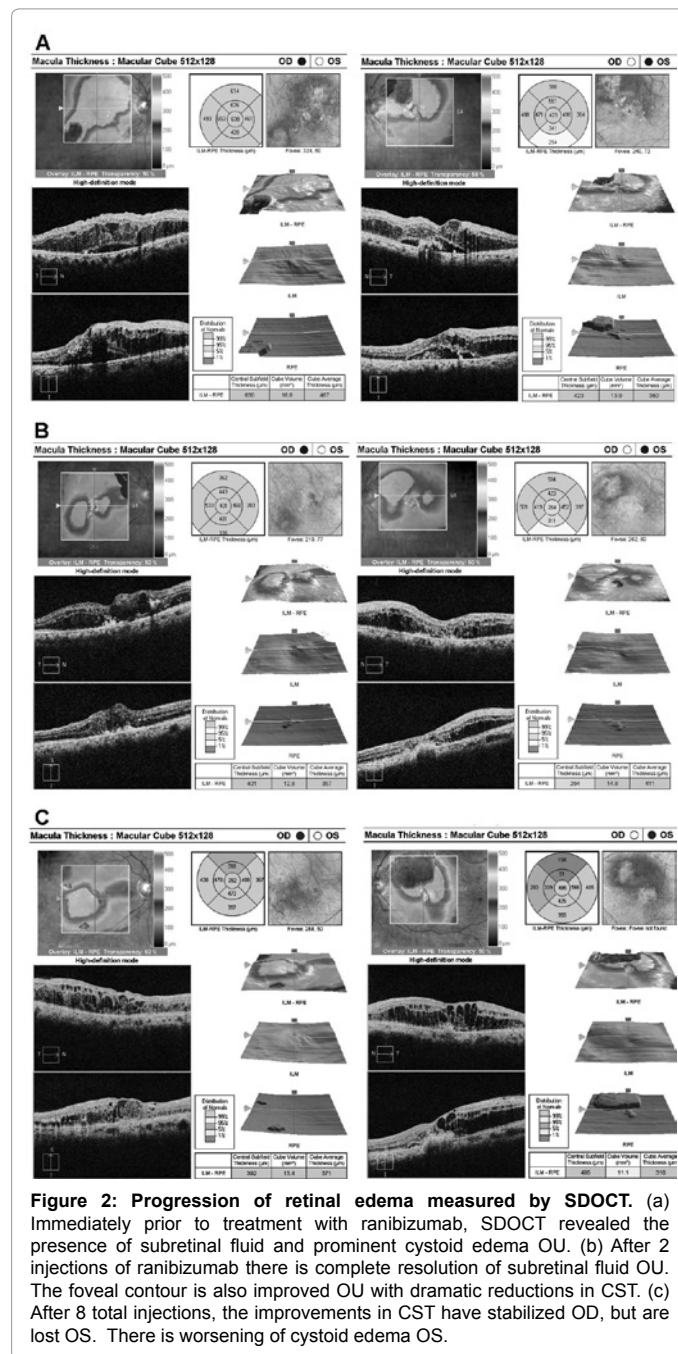
Copyright: © 2011 Yuan A, et al. This is an open-access article distributed under the terms of the Creative Commons Attribution License, which permits unrestricted use, distribution, and reproduction in any medium, provided the original author and source are credited.



in CST OU with resolution of subretinal fluid but persistence of cystoid macular edema OU (Figure 2b). TCV and CAT improved significantly OD, but worsened OS despite an improvement in vision (Figure 2b). Fundoscopic examination showed stabilization of maculopathy. Additional monthly bilateral injections of ranibizumab showed continued improvement in vision OS and stabilization in vision OD. The maximal improvement in CST occurred after 3 injections OD and 2 injections OS (Figure 3). In the right eye, TCV and CAT followed

the trend of CST with peak improvement early after 2 or 3 injections. However, in the left eye, TCV and CAT got worse after the first 2 injections but then stabilized and finally improved towards the end of our study (Figure 3).

After 8 serial ranibizumab injections OU, her vision remained stable at 20/200 OD and improved to 20/40 OS. Comparison of her fundus photos showed complete resolution of foveal hemorrhage OD, a decrease in the number of cotton wool spots, but an increase in the number of hard exudates throughout the macula OU (Figure 4a). SDOCT showed persistent cystoid macular edema but complete resolution of subretinal fluid and an overall improvement in TCV and CAT OU (Figure 2c). The final CST was 392µm OD and 495µm



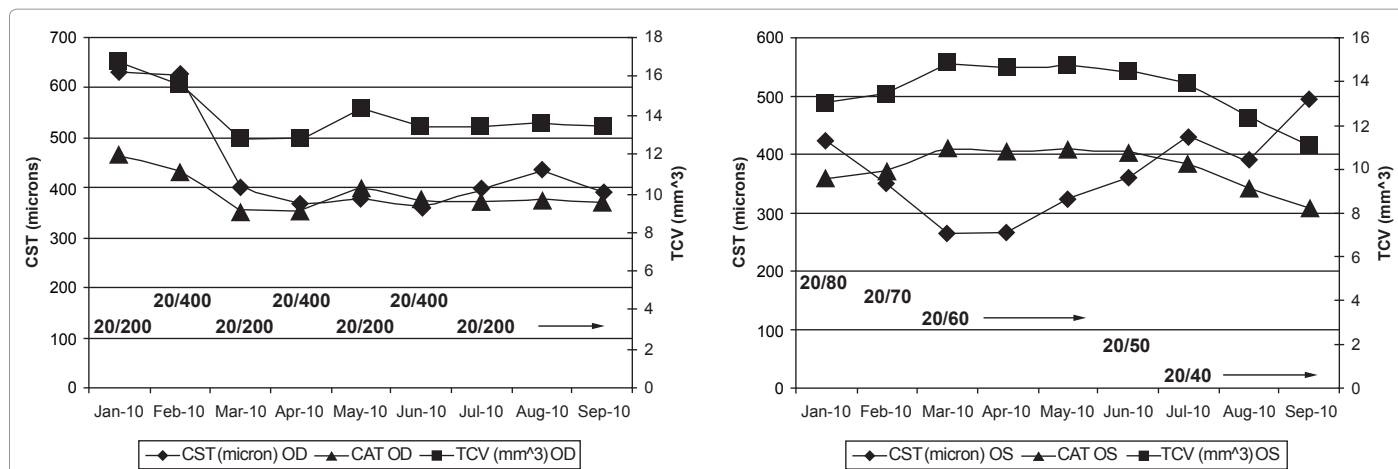


Figure 3: Changes in CST, TCV, and CAT do not parallel visual acuity. The change in CST, TCV, and CAT are plotted for the right and left eyes. The visual acuity at each visit is shown below the plots.

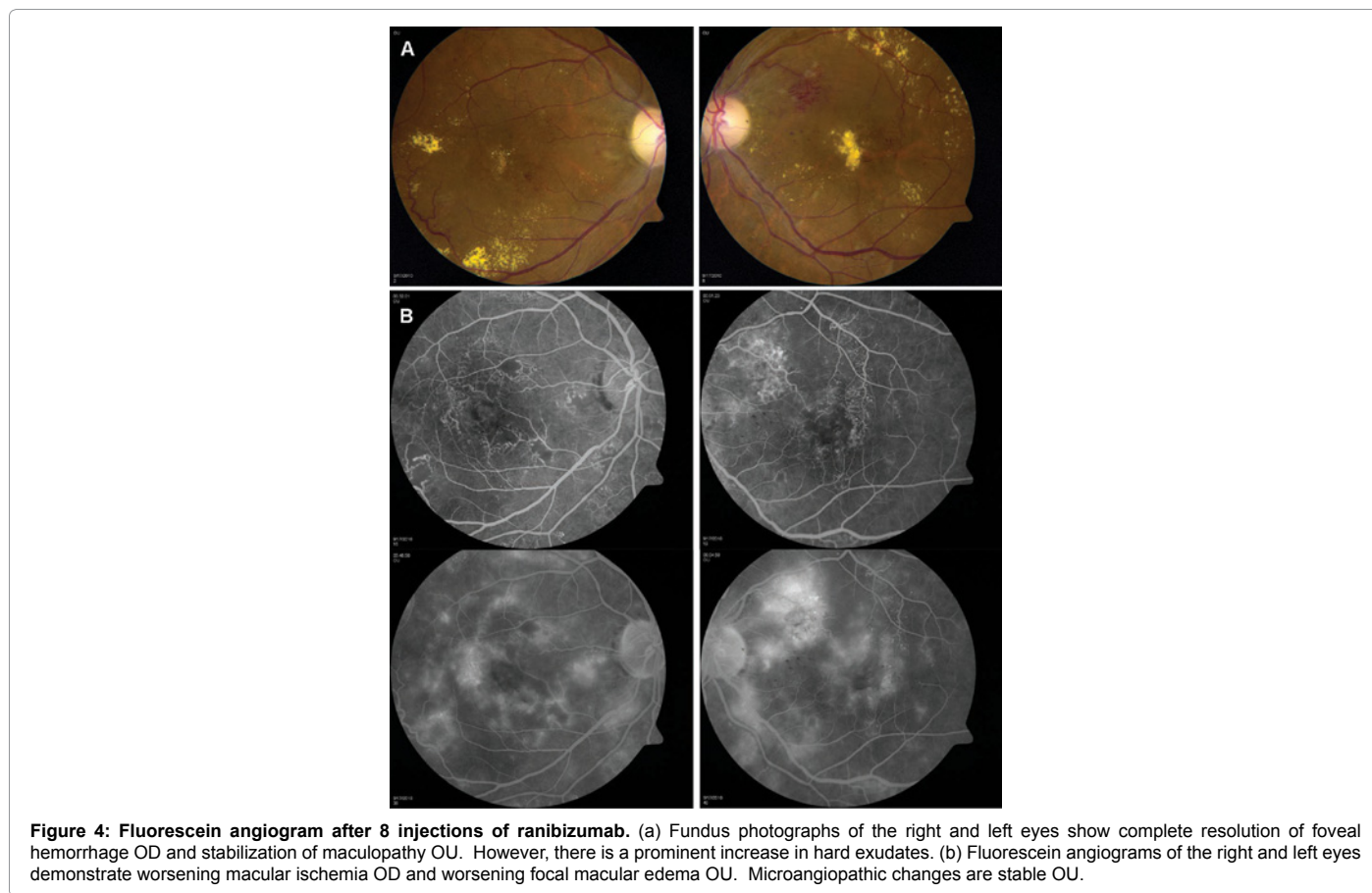


Figure 4: Fluorescein angiogram after 8 injections of ranibizumab. (a) Fundus photographs of the right and left eyes show complete resolution of foveal hemorrhage OD and stabilization of maculopathy OU. However, there is a prominent increase in hard exudates. (b) Fluorescein angiograms of the right and left eyes demonstrate worsening macular ischemia OD and worsening focal macular edema OU. Microangiopathic changes are stable OU.

OS, TCV was 13.4mm³ OD and 11.1mm³ OS, and CAT was 371µm OD and 310µm OS. Fluorescein angiography showed stabilization of microaneurysms and microvascular changes and more prominent macular ischemia OD compared to OS (Figure 4b). At the end of the study, angiographic edema was stable OD, but more prominent in the perifoveal region OS, exhibiting a more cystoid pattern (Figure 4b).

Discussion

Our study evaluates the use of off-label ranibizumab in a patient

with prior whole brain radiotherapy and 2 sessions of gamma knife radiotherapy. Radiation maculopathy in this setting would likely be more severe than with localized plaque bradytherapy not centered over the macula. Our patient had a 4 line gain in Snellen visual acuity in the left eye, from 20/80 to 20/40. Interestingly, this improvement in visual acuity did not parallel the changes in CST, TCV, or CAT seen on SDOCT (Figure 3). Some of this discrepancy might be explained by the inability of the OCT software to accurately measure areas with severe edema and also by the inability of the software to consistently

identify the fovea. Based on fluorescein angiography and SDOCT measurements, visual acuity in this patient is likely limited by the presence of macular ischemia (OD>OS), persistent cystoid macular edema, and foveal exudates. The patient's vision remained stable over the 3 most recent visits.

A recent case series described the use of ranibizumab for the treatment of radiation maculopathy after plaque radiotherapy for choroidal melanoma [8]. Best corrected visual acuity increased by an average of 6 letters on the ETDRS charts. Over a period of 8 months, there was a mean 35% improvement in foveal thickness and an improvement in intraretinal hemorrhages and exudates. The authors concluded that ranibizumab was useful for the treatment of macular edema from radiation maculopathy after plaque brachytherapy. In that study, the gain in vision correlated with the improvements in foveal thickness.

Our case report illustrates that patients with radiation maculopathy may benefit from intravitreal ranibizumab albeit in the short term. Unlike prior reports using anti-VEGF agents, improvements in vision occurred without parallel improvements in macular edema measured by SDOCT, suggesting that retreatment decisions should not depend solely on SDOCT measurements. OCT is a rapid, non-invasive testing modality to measure macular edema. However, in patients with radiation maculopathy, where visual acuity may depend on several other factors, OCT may not be the best predictor of visual outcomes. For example, the extent of macular ischemia was stable in our patient's left eye, but increased greatly in her right eye. Her visual acuity showed the greatest improvement in her left eye. Judicial use of OCT as a retreatment and outcomes measure is advised.

Two prior studies using bevacizumab, another anti-VEGF agent and showed similar results. In one study, best corrected visual acuity improved in two of six patients and were stable in the remaining four. Three of the four patients with stabilization in vision had visual acuity of 20/25 or better. Although objective measurements of macular thickness were not reported, the authors concluded that the most consistent and reproducible finding was a reduction in macular edema [6]. In

the other study, two of five patients showed improvements in vision and resolution of macular edema based on OCT and angiography. The remaining three patients, who did not show any improvement, were older and had long-standing radiation retinopathy [7].

Larger randomized prospective trials could determine the optimal dose, timing, and duration of ranibizumab and other anti-VEGF treatments in patients with radiation maculopathy. Important information regarding the natural progression of macular edema and macular ischemia could be extracted from additional studies.

References

1. Hykin PG, Shields CL, Shields JA, Arevalo JF (1998) The efficacy of focal laser therapy in radiation-induced macular edema. *Ophthalmology* 105: 1425-1429.
2. Finger PT, Kurli M (2005) Laser photocoagulation for radiation retinopathy after ophthalmic plaque radiation therapy. *The British journal of ophthalmology* 89: 730-738.
3. Gall N, Leiba H, Handzel R, Pe'er J (2007) Severe radiation retinopathy and optic neuropathy after brachytherapy for choroidal melanoma, treated by hyperbaric oxygen. *Eye* 21: 1010-1012.
4. Shields CL, Demirci H, Dai V, Marr BP, Mashayekhi A, et al. (2005) Intravitreal triamcinolone acetonide for radiation maculopathy after plaque radiotherapy for choroidal melanoma. *Retina* 25: 868-874.
5. Horgan N, Shields CL, Mashayekhi A, Salazar PF, Materin MA, et al. (2009) Periocular triamcinolone for prevention of macular edema after plaque radiotherapy of uveal melanoma: a randomized controlled trial. *Ophthalmology* 116: 1383-1390.
6. Finger PT, Chin K (2007) Anti-vascular endothelial growth factor bevacizumab (avastin) for radiation retinopathy. *Archives of Ophthalmology* 125: 751-756.
7. Gupta A, Muecke JS (2008) Treatment of radiation maculopathy with intravitreal injection of bevacizumab (Avastin). *Retina* 28: 964-968.
8. Finger PT, Chin KJ (2010) Intravitreal ranibizumab (lucentis) for radiation maculopathy. *Archives of Ophthalmology* 128: 249-252.
9. Horgan N, Shields CL, Mashayekhi A, Shields JA (2010) Classification and treatment of radiation maculopathy. *Current opinion in ophthalmology* 21: 233-238.
10. Wen JC, McCannel TA (2009) Treatment of radiation retinopathy following plaque brachytherapy for choroidal melanoma. *Current opinion in ophthalmology* 20: 200-204.