

## Bilateral Conjunctival Nodules in Sweet's Syndrome

Yan Zhuang and Ying Li\*

Department of Ophthalmology, Peking Union Medical College Hospital, Chinese Academy of Medical Sciences, China

### Abstract

The authors report a case with bilateral conjunctival nodules in Sweet's syndrome. The patient was a 47-year-old Chinese male, who fulfilled the diagnostic criteria of Sweet's syndrome. Fever as well as erythematous papules and blains on his face and arms resolved completely after administration of oral prednisolone. However, he developed secondary facial milia and painless nodules in bilateral eyes. Two well demarcated conjunctival nodules with hyperemia were found, one in the temporal aspect of the right eye and the other in the nasal aspect of the left eye. Excision biopsy of the right eye's lesion showed neutrophilic infiltration without vasculitis, the same histopathologic feature of Sweet's syndrome. The one in the left eye was responsive to local corticosteroids. To our knowledge, this is the first reported case of bilateral conjunctival nodules in Sweet's syndrome.

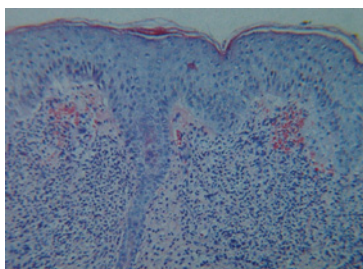
**Keywords:** Conjunctival nodules; Sweet's syndrome

### Introduction

Sweet's syndrome (SS), also referred to as febrile neutrophilic dermatosis, is an uncommon skin disorder characterized by fever, neutrophilic leukocytosis, red papules, nodules and plaques that respond readily to corticosteroid therapy [1]. Ocular manifestations are rare in SS. We reported a case of SS who developed bilateral conjunctival nodules. Excision biopsy of the right eye's lesion showed neutrophilic infiltration without vasculitis. The one in the left eye was responsive to local corticosteroids.

### Case Report

A 47-year-old Chinese male presented to the dermatologist, complaining of fever of 38.5°C for 2 weeks as well as erythematous papules and blains on his face and arms for 1 week on October 5th 2009. There was not any preceding upper respiratory infection, trauma or drug ingestion. Laboratory tests revealed normal leucocyte count with neutrophilia (neutrophils 78.5%). Erythrocyte sedimentation rate (ESR) and hypersensitive C-reactive protein (hsCRP) were elevated dramatically to more than 140mm/h and 10mg/L respectively. A biopsy of blain in the arm showed dense neutrophilic infiltration with no evidence of vasculitis (Figure 1). Other examinations, including bone marrow aspiration, abdominal ultrasonography, chest computed tomography, carcinoembryonic antigen, cancer antigen-125, 19-9, 242, antinuclear antibody, antineutrophil cytoplasmic antibody, complement, rheumatoid factor, anti-ENA antibodies, anti-double stranded DNA antibody, were also undertaken to exclude systematic diseases, but all the results were normal. Diagnosis of idiopathic SS was

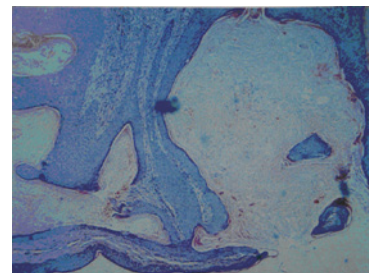


**Figure 1:** Skin biopsy from the blain in the arm showed superficial dermal edema and dense neutrophilic infiltration with no evidence of vasculitis (Hematoxylin-eosin staining).

made. Oral prednisolone of 50mg/day was initiated. Fever and skin lesions promptly resolved, and disappeared 2 weeks later. Three weeks after the treatment, the percentage of neutrophils decreased to 57.9%. Prednisolone was tapered slowly.

However, despite of the resolution of erythematous papules and blains, small white and firm papules developed on the face and fused into plaques quickly. Histopathologic examination demonstrated multiple milia (Figure 2), which was considered to be a secondary lesion. Therefore, no specific treatment was given.

The patient was referred to Department of Ophthalmology on November 12th 2009, complaining of bilateral painless nodules, which developed simultaneously with the facial milia. Prominent white plaques(milia) could be noticed on the face, especially around the nose and mouth (Figure 3). Two well demarcated conjunctival nodules, 3mm in diameter with hyperemia, were found, one in the temporal aspect of the right eye and the other in the nasal aspect of the left eye



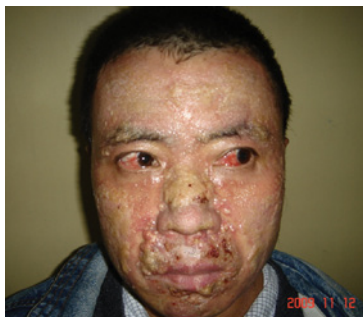**Figure 2:** Skin biopsy from the white plaque in the forehead showed several cysts in superficial dermis, filling with a keratin like substance (Hematoxylin-eosin staining).

**\*Corresponding author:** Ying Li, Department of Ophthalmology, Peking Union Medical College Hospital, Chinese Academy of Medical Sciences, Shuaifuyuan, Dongcheng District, Beijing, China, Tel: 86-10-65296351; Fax 86-10-65296351; E-mail: [liyinqumch@126.com](mailto:liyinqumch@126.com)

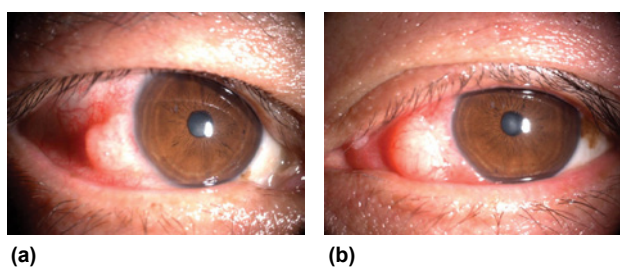
**Received** January 09, 2011; **Accepted** March 07, 2011; **Published** March 09, 2011

**Citation:** Zhuang Y, Li Y (2011) Bilateral Conjunctival Nodules in Sweet's Syndrome. J Clin Exp Ophthalmol 2:146. doi:10.4172/2155-9570.1000146

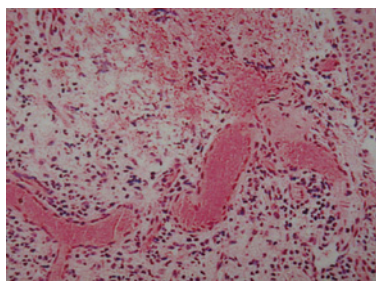
**Copyright:** © 2011 Zhuang Y, et al. This is an open-access article distributed under the terms of the Creative Commons Attribution License, which permits unrestricted use, distribution, and reproduction in any medium, provided the original author and source are credited.



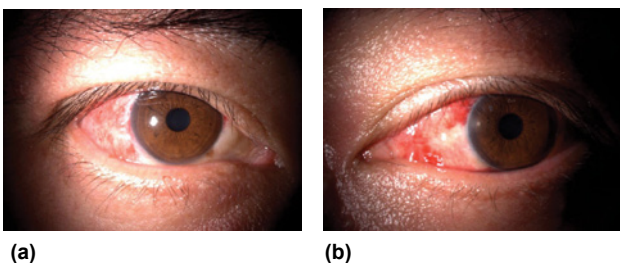
**Figure 3:** Prominent white and firm plaques could be noticed on the face at the initial visit to our department, especially around the nose and mouth.



**Figure 4:** Two well demarcated nodules were found, one in the temporal conjunctiva of the right eye (Figure 4a) and the other in the nasal conjunctiva of the left eye (Figure 4b).



**Figure 5:** Conjunctival biopsy of the nodule in the right eye showed neutrophilic infiltration and vascular dilation without vasculitis (Hematoxylin-eosin staining).



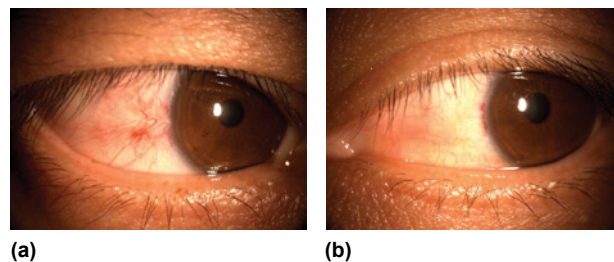
**Figure 6:** Mild conjunctival edema resulting from the surgical removal of the nodule in the right eye was noticed 10 days postoperatively (Figure 6a). Partial resolution of the conjunctival nodule in the left eye was observed after treatment with 1% prednisolone acetate for 10 days (Figure 6b).

(Figure 4). His visual acuity was 30/20 in both eyes. No abnormalities were found in the anterior and posterior segment of both eyes. Fluorometholone (0.1%) eyedrops six times/day was administered for 1 week. However, no resolution was noticed. Therefore, excision biopsy of the right eye's lesion was carried out on 19th November. No

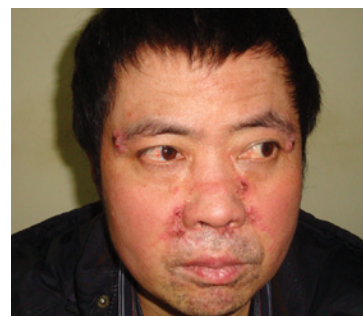scleral abnormalities were found during operation. Histopathologic examination showed neutrophilic infiltration and vascular dilation without any suggestion of vasculitis (Figure 5), similar to the primary skin lesions (Figure 1). Prednisolone acetate (1%) eyedrops six times/day was applied for both eyes. The stitches were removed on the 4th postoperative day. Mild conjunctival edema resulting from the surgical removal of the nodule in the right eye was noticed as well as partial resolution of the conjunctival nodule in the left eye on the 10th postoperative day (Figure 6). Prednisolone acetate was tapered slowly over 1 month. At the final visit 2 months postoperatively, mild conjunctival scarring in the right eye was observed, and the conjunctival nodule in the left eye disappeared completely (Figure 7). All the active skin lesions, including the primary papules and blains as well as the secondary milia, disappeared, leaving small scabs in the peri-nasal and temporal area (Figure 8).

## Discussion

SS is an uncommon skin disease, which can present in three clinical settings: classical (or idiopathic), malignancy-associated and drug-induced [1]. Diagnosis of classical SS requires to fulfill both major criteria (1 and 2), and two of the four minor criteria (3, 4, 5, and 6): (1) Abrupt onset of painful erythematous plaques or nodules, (2) Histopathologic evidence of a dense neutrophilic infiltrate without evidence of leukocytoclastic vasculitis, (3) Pyrexia  $>38^{\circ}\text{C}$ , (4) Association with an underlying hematologic or visceral malignancy, inflammatory disease, or pregnancy, or preceded by an upper respiratory or gastrointestinal infection or vaccination, (5) Excellent response to treatment with systemic corticosteroids or potassium iodide, (6) Abnormal laboratory values at presentation (three of four): erythrocyte sedimentation rate  $>20$  mm/hr; positive C-reactive protein;  $>8,000$  leukocytes;  $>70\%$  neutrophils. Bones, central nervous system,



**Figure 7:** Mild conjunctival scarring in the right eye was found 2 months postoperatively (Figure 7a). The conjunctival nodule in the left eye disappeared completely after treatment with local corticosteroids (Figure 7b).



**Figure 8:** All the active skin lesions, including the primary erythematous papules and blains as well as the secondary white milia, disappeared at the final visit, leaving small scabs in the peri-nasal and temporal area.

ears, eyes, kidneys, intestines, liver, heart, lung, mouth, muscles, and spleen can be the sites of extracutaneous manifestations of SS [1].

With the fever, skin lesion and its histopathologic examination, elevated ESR and neutrophilia, as well as the response to corticosteroids, our present patient fulfilled the diagnostic criteria. The systematic examinations did not find any evidence of hematologic disorders, internal malignant diseases, or other autoimmune diseases associated with SS. Kemmett et al. reported that resolution of the primary skin lesions was occasionally followed by milia and scarring. [2]. Our patient was a good case in illustrating this point.

Gunawardena et al. found that ocular manifestations occur in 4% to 72% of patients with SS. [3] Conjunctivitis, [4,5] conjunctival and limbal nodules, [6,7] scleritis, [8,9] retinal vasculitis, [10] and orbital cellulitis [11] had been reported. However, most of the cases were unilateral involvement and the development of ocular lesions was coincidental with fever and skin lesions. [6,7,9,11] Our case was characterized by bilateral involvement and the solitary big conjunctival nodule in both eyes, which was quite different from the cluster of small nodules reported before. [6,7] Moreover, the conjunctival nodules and facial milia developed simultaneously after the resolution of fever and primary skin lesions. Conjunctival biopsy showed neutrophilic infiltration without any suggestion of vasculitis, which was the typical histopathologic feature of SS. Therefore, it was proved that the conjunctival nodules were associated with SS rather than the secondary milia. Prednisolone acetate (1%) eyedrops was administered in the left eye according to the histopathologic result, and good response was noticed, suggesting that local corticosteroids treatment was effective. However, the initial fluorometholone eyedrops (0.1%) did not work, which might be attributed to low concentration.

Our case is the first report with ocular surface abnormality in SS in China, although 2 cases with retinal vasculitis have been reported before [12].

## Conclusion

Ocular manifestations in SS can present as a solitary big

conjunctival nodule in both eyes, which has the same histopathologic feature of SS in the skin. The conjunctival nodules are responsive to local corticosteroids.

## Acknowledgement

The authors wish to give their thanks to Doctor Hongwei Wang, Jin Hongzhong and Ju Qiao, from Department of Dermatology, Peking Union Medical College Hospital, Chinese Academy of Medical Sciences, for their effort for the diagnosis and treatment on the patient.

## References

1. Cohen PR (2007) Sweet's syndrome-a comprehensive review of an acute febrile neutrophilic dermatosis. *Orphanet J Rare Dis* 2: 34.
2. Kemmett D, Hunter JA (1990) Sweet's syndrome: a clinicopathologic review of twenty-nine cases. *J Am Acad Dermatol* 23: 503-507.
3. Gunawardena DA, Gunawardena KA, Ratnayaka RM, Vasanathanan NS (1975) The clinical spectrum of Sweet's syndrome (acute febrile neutrophilic dermatosis)-a report of eighteen cases. *Br J Dermatol* 92: 363-373.
4. Cohen PR (1993) Sweet's syndrome presenting as conjunctivitis. *Arch Ophthalmol* 111: 587-588.
5. Michel G, Lhermitte B, Cribier B, Speeg-Schatz C, Bourcier T (2008) Sweet Syndrome Presenting as Resistant Conjunctivitis. *Cornea* 27: 1189-1190.
6. Kato T, Kawana S, Takezaki S, Kikuchi S, Futagami A (2008) A case of Sweet's syndrome with extensive necrosis and ulcers accompanied by myelodysplastic syndrome. *J Nippon Med Sch* 75: 162-165.
7. Kikuchi S, Hori J, Tsukada R, Takahashi H, Kato T (2009) Limbal nodules associated with Sweet's syndrome. *Jpn J Ophthalmol* 53: 652-653.
8. Wong MH, Su DH, Loh RS (2007) Nodular scleritis and Sweet's syndrome. *Clin Experiment Ophthalmol* 35: 858-860.
9. Mazokopakis E, Kalikaki A, Stathopoulos E, Vrentzos G, Papadakis JA. (2005) Acute febrile neutrophilic dermatosis (Sweet's syndrome) with erythema nodosum and anterior scleritis. A case report. *Int J Dermatol* 44: 1051-1053.
10. Sato M, Kawamura T, Hase S, Katsumata S, Oshika T (2005) A case of bilateral retinal vasculitis associated with Sweet syndrome. *Retina* 25: 800-802.
11. Oshitari K, Hida T, Takahashi M, Okada AA, Shiobara T (2004) Sweet syndrome presenting as orbital cellulitis. *Nippon Ganka Gakkai Zasshi* 108: 162-165.
12. Hu M, Hui Y, Hao Y, Zhou J (1991) Two cases of ocular complications in Sweet's syndrome (in Chinese). *Ocular fundus diseases* 7: 163-164.