

Lens Thickness and Position of Primary Angle Closure Measured by Anterior Segment Optical Coherence Tomography

Li Mei¹, Wang Zhonghao², Mao Zhen², Zhong Yimin² and Liu Xing^{2*}

¹University of Hongkong-Shenzhen Hospital, Shenzhen, China

²Zhongshan Ophthalmic Center, Sun Yat-sen University, Guangzhou, China

Abstract

Purpose: To compare the lens' thickness and position between symptomatic and asymptomatic primary angle closure (PAC) patients.

Methods: Sixty-six patients (66 eyes) with acute symptomatic PAC, 49 patients (49 eyes) with asymptomatic PAC and 32 normal controls (32 eyes) were enrolled at the Zhongshan Ophthalmic Center, Sun Yat-sen University. A-mode applanation ultrasonography examination was performed to get axial length (AL). Anterior segment optical coherence tomography examination was performed to measure the anterior chamber depth (ACD), lens thickness (LT) and crystalline lens rise (CLR). The differences of these parameters among the three groups of symptomatic PAC, asymptomatic PAC and normal controls were compared.

Results: There was no significant difference of the mean age among the 3 groups ($P=0.087$). Compared with asymptomatic PAC eyes, symptomatic PAC eyes had significantly shallower ACD (2.02 ± 0.25 mm vs. 1.84 ± 0.24 mm, $P<0.001$), thicker LT (5.04 ± 0.36 mm vs. 5.19 ± 0.38 mm, $P=0.02$), larger CLR (0.93 ± 0.21 mm vs. 1.09 ± 0.26 mm, $P<0.01$); and shorter AL (22.90 ± 0.76 mm vs. 22.26 ± 0.82 mm, $P<0.001$). Compared with symptomatic PAC fellow eyes, affected eyes had significantly shallower ACD (1.90 ± 0.23 mm vs. 1.80 ± 0.24 mm, $P=0.038$), and larger CLR (1.01 ± 0.23 mm vs. 1.10 ± 0.27 mm, $P=0.043$); but no significant difference was found in AL and LT between symptomatic PAC affected and fellow eyes.

Conclusion: PAC has thicker lens and more anterior located lens than normal controls. Symptomatic PAC-affected eyes have shallowest ACD, thicker LT and more anterior lens position, and these differences may be contributory to APAC episode.

Keywords: Primary angle closure; Lens; Anterior segment optical coherence tomography

Introduction

Primary angle closure glaucoma (PACG) is a major cause of blindness worldwide, and a major type of glaucoma in Asian population. Ethnic or geographic differences in the prevalence rates of PACG are well known, with a relatively high prevalence rates (1.1%-2.0%) in Chinese, Mongolian, and Singaporean Chinese [1]. The predisposing factors for PACG largely relate to the anatomic configuration of the anterior segment of the eye. Biometric studies have shown that acute primary angle closure glaucoma (APACG) eyes have shallower anterior chambers [3-5] and shorter axial lengths (AL) [2-5]. Clearly, smaller ocular biometry is a risk factor for APACG. However, there may be other anatomical factors that are important with regard to triggering of the acute attack. It is believed that the relative size and position of the crystalline lens play a major role in the pathogenesis of angle closure [6]. When the biometry of contralateral eyes of patients with APACG was compared to population-based controls, thicker lens was found to be an unfavorable dimension [7]. With age, there is an increase in lens thickness (LT), and a relatively more anterior lens position (LP). In eyes that are hyperopia with small anterior segments, the result is angle crowding and a greater predisposition to pupillary block due to iridolenticular apposition. For these reasons, primary lens extraction, which deepens the anterior chamber and widens chamber angle, has been advocated for primary angle closure (PAC) [8,9].

Although significant biometric differences have been reported in the different subtypes of PACG, very few studies have been conducted to evaluate the lens thickness and lens position in the symptomatic and asymptomatic PAC. Anterior segment optical coherence tomography

(AS-OCT) is an easy-to-use, safe, non-contact examination technique which offers rapid and easy analysis of the anterior segment structural parameters qualitatively and quantitatively [10]. Moreover, AS-OCT is an alternative method to measure LT, which can be used in most eyes with clear or opacified lenses [11]. The aim of this study was to prospectively compare the lens thickness and lens position between symptomatic and asymptomatic PAC using AS-OCT to identify any differences in these characteristics that may be contributory to the acute episode. In addition, axial length and anterior chamber depth measurements were also evaluated.

Methods

Cases

PAC were defined as the presence of at least 180° of angle in which the trabecular meshwork was not visible on gonioscopy, and with evidence of either raised intraocular pressure (IOP) and/or primary peripheral anterior synechiae in any part of the angle [12]. Cases of

*Corresponding author: Liu Xing, Zhongshan Ophthalmic Center, Sun Yat-Sen University, 54 S, Xianlie Road, Guangzhou 510060, People's Republic of China, Tel: +86 20 8733 0434; Fax: +86 20 8733 3271; E-mail: drluixing@163.com

Received May 05, 2013; Accepted May 27, 2013; Published May 31, 2013

Citation: Mei L, Zhonghao W, Zhen M, Yimin Z, Xing L (2013) Lens Thickness and Position of Primary Angle Closure Measured by Anterior Segment Optical Coherence Tomography. J Clin Exp Ophthalmol 4: 281. doi:[10.4172/2155-9570.1000281](https://doi.org/10.4172/2155-9570.1000281)

Copyright: © 2013 Mei L, et al. This is an open-access article distributed under the terms of the Creative Commons Attribution License, which permits unrestricted use, distribution, and reproduction in any medium, provided the original author and source are credited.

secondary angle closure, such as neovascularization of the iris, uveitis, trauma, lens intumescence, or subluxation, were excluded.

Subjects were further categorized into two groups [13]: symptomatic PAC group (66 patients, 66 eyes) consisted of those who presented with acute symptomatic angle closure, and asymptomatic PAC group (49 patients, 49 eyes) consisted of those who were asymptomatic or without suggestive history of acute angle closure. For this study, acute angle closure was defined as follows:

1. Presence of at least two of the following symptoms: ocular or periocular pain, nausea and/or vomiting, and a history of intermittent blurring of vision halos.
2. Presenting IOP of more than 28 mmHg (as measured by Goldmann applanation tonometry) and the presence of at least of three of the following signs: conjunctival injection, corneal epithelial edema, mid-dilated unreactive pupil, and shallow anterior chamber.

Controls

These were age and gender matched normal subjects who had come for a health examination with refractive error within ± 1.0 D. They were thoroughly screened for any intraocular abnormalities and found to have no other ocular diseases, IOP < 21 mmHg and visual acuity better than 6/18. One eye of each subject was randomly selected. A total of 32 cases (32 eyes) were included in the control group.

We certified that all applicable institutional and governmental regulations concerning the ethical use of human volunteers were followed during this research. Written informed consent was obtained from all subjects, and the study had the approval of the Ethics Committee of the Zhongshan Ophthalmic Center, Sun Yat-sen University, Guangzhou, China and was performed according to the tenets of the Declaration of Helsinki.

Eye examinations

All cases and controls underwent detailed eye examinations including measurement of visual acuity, slit-lamp biomicroscopy, direct ophthalmoscopy, 90D fundus examination, gonioscopy, applanation tonometry, A-mode applanation ultrasonography (Sonomed A2500; HaagStreit, Koniz, Switzerland), optometry, AS-OCT (Visante™, Carl Zeiss Meditec, Dublin, CA) examination, Humphrey fields analyzer (Carl Zeiss Meditec, Dublin, CA) examination and OCT (Carl Zeiss Meditec, Dublin, CA) nerve fiber layer measurement to evaluate the glaucomatous changes.

Anterior segment coherence tomography examination

The AS-OCT measurements were performed by the same experienced operator, and were performed without pupil dilation in the same room in standard illumination conditions. The AS-OCT images were acquired in a non accommodated state. The subject's refractive correction was used to adjust the internal fixation target for the patient's distance correction by using the system's internal program. During imaging, the subjects were asked to fixate on the target. AS-OCT measurements were centered on the pupil and performed at the horizontal meridian (nasal-temporal, angles at 0-180°) using the anterior segment single-scan tools. The default fixation angle position in the AS-OCT is aligned along the visual axis. If the scans were noticeably off from the horizontal, the fixation angle was adjusted to align the image along the geometric axis.

AS-OCT parameters were measured using the device's manual

caliper tools included in the equipment's software. The AS-OCT parameters included the following variables: (1) ACD, which was measured along posterior corneal surface to the anterior pole of the lens; (2) LT, which was the distance between the anterior and posterior poles of the lens (Figure 1A); (3) CLR, which was measured perpendicularly along the center of the line joining the tips of the scleral spur to the anterior capsule of the lens. CLR was described by Bäckoff G [8] as the forward protrusion of the crystalline lens (Figure 1B).

Statistical analysis

Statistical analysis was done using Statistical Package for Social Science version 13.0 (SPSS Inc, Chicago, IL). Comparisons among different groups were assessed by LSD one-way ANOVA test. Comparisons between the symptomatic PAC affected and the fellow eyes were assessed by the paired-sample *t*-test. Comparisons between symptomatic and asymptomatic PAC eyes were assessed by the independent-sample *t* test. *P* value < 0.05 was considered as statistically significant.

Results

The mean age of each group was as follows: symptomatic PAC group: 61.35 \pm 9.33 years, asymptomatic PAC group: 59.77 \pm 10.24 years, control group: 65.70 \pm 12.80 years (Table 1). There was no significant difference in the mean age among three groups (*P*=0.087). But the IOP of control group was significantly lower than that of the symptomatic and asymptomatic PAC groups (*P*=0.032). The mean defects of visual field were -7.00 \pm 7.24 (-27.70-0.21) in the symptomatic PACG group and -8.59 \pm 7.88 (-23.46-0.13) in the asymptomatic PACG group.

The mean AS-OCT parameters measured by AS-OCT among

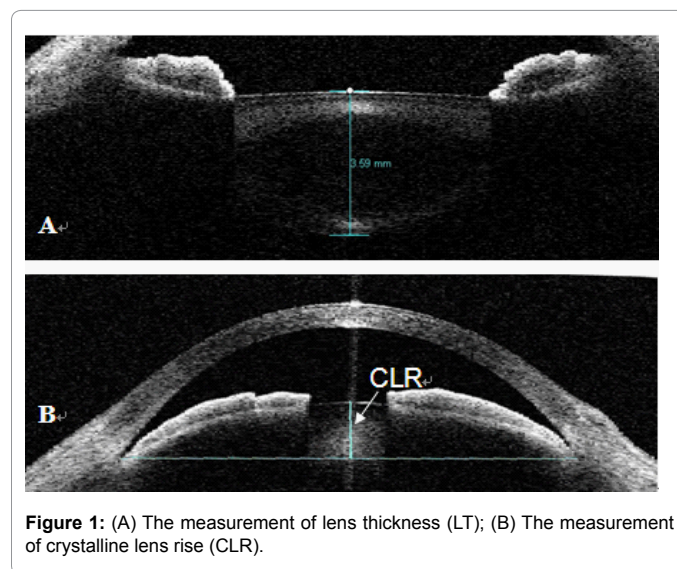


Figure 1: (A) The measurement of lens thickness (LT); (B) The measurement of crystalline lens rise (CLR).

| Variables | Symptomatic PAC group | Asymptomatic PAC group | Control group |
|-------------|-----------------------|------------------------|-------------------|
| Total | 66 | 49 | 32 |
| Male (n) | 30(45%) | 22(45%) | 15(47%) |
| Female (n) | 36(55%) | 27(55%) | 17(53%) |
| Age (yrs) | 61.35 \pm 9.33 | 59.77 \pm 10.24 | 65.70 \pm 12.80 |
| Range (yrs) | 40-80 | 37-79 | 35-78 |

PAC: Primary angle closure

Table 1: Baseline demographics of study participants.

different groups were shown in Table 2. The ACD of control group was significantly deeper than PAC groups (both $P < 0.001$), while the LT and CLR were significantly smaller than PAC groups (all $P < 0.001$) (Figure 2). And on A-mode applanation ultrasonography, the AL of control group was significantly longer than both PAC groups ($P < 0.001$).

Compared with asymptomatic PAC eyes, symptomatic PAC eyes

had significantly shallower ACD ($P < 0.001$), thicker LT ($P = 0.02$), larger CLR ($P < 0.001$), and shorter AL ($P < 0.001$). Compared with symptomatic PAC fellow eyes, affected eyes had significantly shallower ACD ($P = 0.038$), and larger CLR ($P = 0.043$), but no significant difference was found in AL ($P = 0.720$) and LT ($P = 0.257$) between symptomatic PAC affected and fellow eyes (Table 3).

| Parameters (mm) | Symptomatic PAC group | Asymptomatic PAC group | Control group | F value | P value |
|-----------------|-----------------------|------------------------|---------------|---------|---------|
| ACD | 1.84 ± 0.24 | 2.02 ± 0.25 | 2.70 ± 0.39 | 221.347 | <0.001 |
| LT | 5.19 ± 0.38 | 5.04 ± 0.36 | 4.57 ± 0.42 | 44.658 | <0.001 |
| CLR | 1.09 ± 0.26 | 0.93 ± 0.21 | 0.38 ± 0.33 | 30.753 | <0.001 |
| AL | 22.26 ± 0.82 | 22.90 ± 0.76 | 23.54 ± 0.72 | 84.386 | <0.001 |

PAC: Primary angle closure; ACD: Anterior chamber depth; LT: Lens thickness; CLR: Crystalline lens rise; AL: Axial length

Table 2: Biometric lens characteristics of PAC and normal control eyes.

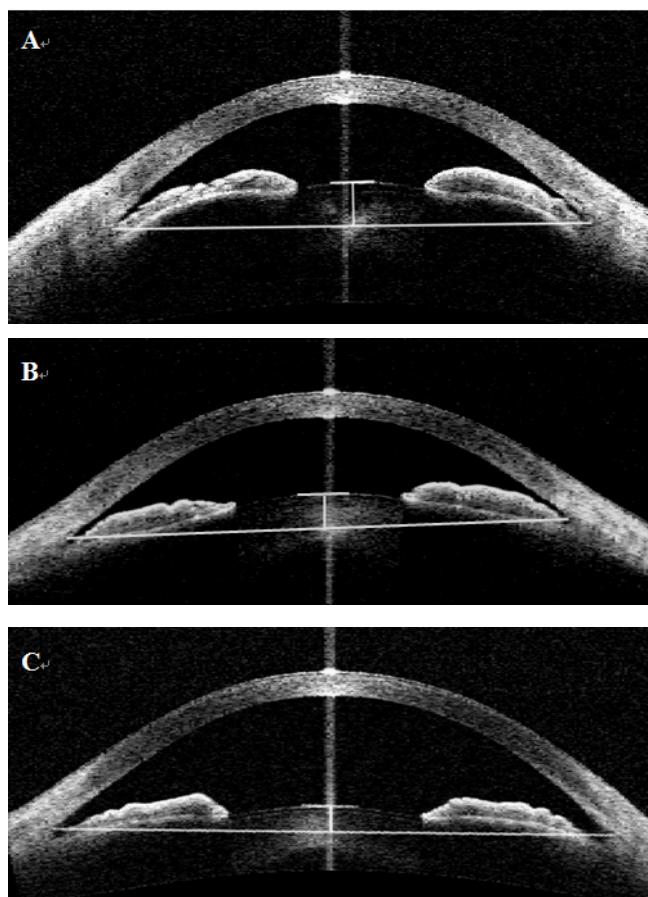


Figure 2: (A) AS-OCT image of symptomatic primary angle closure affected eye of a 51-year-old female patient. The anterior chamber width is 11.81 mm, and the crystalline lens rise is 1.49 mm; (B) AS-OCT image of asymptomatic primary angle closure eye of a 57-year-old female patient. The anterior chamber width is 11.00 mm, and the crystalline lens rise is 0.90 mm; (C) AS-OCT image of the right eye of a 55-year-old female normal control. The anterior chamber width is 11.47 mm, and the crystalline lens rise is 0.39 mm.

| Parameters (mm) | Symptomatic PAC-affected eyes | Symptomatic PAC-fellow eyes | t value | P value |
|-----------------|-------------------------------|-----------------------------|---------|---------|
| ACD | 1.80 ± 0.24 | 1.90 ± 0.23 | -2.129 | 0.038 |
| LT | 5.22 ± 0.40 | 5.14 ± 0.36 | 1.147 | 0.257 |
| CLR | 1.10 ± 0.27 | 1.01 ± 0.23 | 1.349 | 0.043 |
| AL | 22.24 ± 0.83 | 22.24 ± 0.84 | 0.360 | 0.720 |

PAC: Primary angle closure; ACD: Anterior chamber depth; LT: Lens thickness; CLR: Crystalline lens rise; AL: Axial length

Table 3: Biometric lens characteristics of symptomatic PAC-affected and fellow eyes.

Discussion

Although both of symptomatic and asymptomatic PAC have similar biometric configurations, It has still not yet been revealed why acute attack occurs in symptomatic PAC eyes but not in asymptomatic PAC eyes.

In this study, the lens was found to be thicker and positioned more anterior in PAC eyes than in normal controls under AS-OCT. Pupillary block is the most frequent and important mechanism responsible for angle closure [14,15] and the lens is accepted to have played a pivotal role in the pupillary block mechanism [16]. Under the observation of ultrasound biomicroscopy (UBM), pupillary block is found to exist in about 93% eyes with PACG in China [17]. As we know, aqueous humor is produced into the posterior chamber and flows anterior through iris-lens channel to enter the anterior chamber. When the dimensions of the iris-lens channel are changed in such a manner that the flow of aqueous is more impeded, the pressure differential between the posterior chamber and anterior chamber may increase greatly [18]. The iris will become more convex if this pressure differential increases. Lens size and position are proved to be potentially risk factors of more or less importance in determining iris contour and the development of pupillary block in eyes which become at risk for angle closure [19]. Clinically significant pupillary block is present when the thicker lens and more anterior located lens position brings the iris into apposition with the trabecular meshwork by increasing iris convexity.

Under the observation by A-mode applanation ultrasonography, Lowe [5] reported that ACD in PACG eyes is approximately 1 mm shallower than that in normal subjects. And Lowe [5,20] estimated that rather than the increase in LT, forward LP had played a more important role in the 1mm difference in ACD of PACG eyes compared to the normal eyes. CLR is thought to be a good indicator of the amount of narrowing of the anterior chamber angle, where the more anterior location of the lens position, the narrower of the anterior chamber angle [21]. We introduced CLR here to describe the lens position. Under the observation by AS-OCT in our study, the ACD of eyes with PAC was about 0.82 mm shallower, the LT was 0.59 mm thicker and CLR was 0.65 mm larger than those in normal eyes. It means that in eyes with PAC, the increase in LT mainly protruded towards the anterior chamber rather than towards the vitreous cavity, which eventually brought iris into apposition with the trabecular meshwork. Roberts et al. proposed that long anterior lens zonules might be a useful indicator for an increased risk of angle closure [22]. And this might be the explanation for the increased in the lens thickness and the antero-movement of lens location in eyes with PAC.

Moreover, the lens was found to be positioned even more anterior in symptomatic PAC eyes compared with asymptomatic PAC eyes. In our study, the LT was 0.15 mm thicker and the CLR was 0.16 mm larger in symptomatic PAC than those asymptomatic PAC eyes. Such differences in LT and LP make the iris-lens channel even more impeded, which further increase the pressure differential between posterior chamber and the anterior chamber, and then the pupillary block and acute attack may happen. Thus, thicker lens and ante location of the lens position in acute primary angle closure (APAC) eyes may be the one of explanations for acute attacks happening in these eyes rather than in asymptomatic PAC eyes.

Different from most previous studies by A-mode applanation ultrasonography, which found no difference in LT and LP between APAC affected and fellow eyes [17], our study shows that APAC affected eyes had larger CLR values than their fellow eyes by AS-OCT.

The reason may be the AS-OCT has a higher resolution and a better visibility of the lens.

Our result indicated that the lens of APAC-affected eyes had a bigger size and more anterior position than their fellow eyes, which are an explanation for our finding that the ACD was shallower in APAC affected eyes than those fellow eyes. These are interesting observations since they demonstrated that there might be a mild interocular differences in individuals with APAC even if there is a high degree of correlation between attack and fellow eyes in terms of biometric and lens characteristics. The possible reason of this mild interocular differences might be caused by long or/and relaxed lens zonules in APAC, which can also lead to an acute attack. As a result, cataract extraction is useful in preventing or relieving APAC.

In conclusion, PAC eyes have thicker LT and more anterior LP than normal controls. APAC-affected eyes have the shallowest ACD, thicker LT and more anterior LP, and these differences may be contributory to APAC episode.

Acknowledgements

This study was financially supported by the Natural Science Foundation of Guangdong Province (S2012040007421, 2011010006046).

References

1. Sawaguchi S, Sakai H, Iwase A, Yamamoto T, Abe H, et al. (2012) Prevalence of primary angle closure and primary angle-closure glaucoma in a southwestern rural population of Japan: the Kumejima Study. *Ophthalmology* 119: 1134-1142.
2. Foster PJ (2002) The epidemiology of primary angle closure and associated glaucomatous optic neuropathy. *Semin Ophthalmol* 17: 50-58.
3. Lowe RF (1970) Aetiology of the anatomical basis for primary angle-closure glaucoma. Biometrical comparisons between normal eyes and eyes with primary angle-closure glaucoma. *Br J Ophthalmol* 54: 161-169.
4. Seah SK, Foster PJ, Chew PT, Jap A, Oen F, et al. (1997) Incidence of acute primary angle-closure glaucoma in Singapore. An island-wide survey. *Arch Ophthalmol* 115: 1436-1440.
5. Wong TY, Foster PJ, Seah SK, Chew PT (2000) Rates of hospital admissions for primary angle closure glaucoma among Chinese, Malays, and Indians in Singapore. *Br J Ophthalmol* 84: 990-992.
6. Tarongoy P, Ho CL, Walton DS (2009) Angle-closure glaucoma: the role of the lens in the pathogenesis, prevention, and treatment. *Surv Ophthalmol* 54: 211-225.
7. Tomlinson A, Leighton DA (1973) Ocular dimensions in the heredity of angle-closure glaucoma. *Br J Ophthalmol* 57: 475-486.
8. Jacobi PC, Dietlein TS, Lücke C, Engels B, Krieglstein GK (2002) Primary phacoemulsification and intraocular lens implantation for acute angle-closure glaucoma. *Ophthalmology* 109: 1597-1603.
9. Yang CH, Hung PT (1997) Intraocular lens position and anterior chamber angle changes after cataract extraction in eyes with primary angle-closure glaucoma. *J Cataract Refract Surg* 23: 1109-1113.
10. Su DH, Friedman DS, See JL, Chew PT, Chan YH, et al. (2008) Degree of angle closure and extent of peripheral anterior synechiae: an anterior segment OCT study. *Br J Ophthalmol* 92: 103-107.
11. Baikoff G (2006) Anterior segment OCT and phakic intraocular lenses: a perspective. *J Cataract Refract Surg* 32: 1827-1835.
12. Foster PJ, Buhrmann R, Quigley HA, Johnson GJ (2002) The definition and classification of glaucoma in prevalence surveys. *Br J Ophthalmol* 86: 238-242.
13. Yong VK, Umaphathi T, Aung T, Tan NC, Lee JJ, et al. (2004) Systemic autonomic function in subjects with primary angle-closure glaucoma: a comparative study of symptomatic and asymptomatic disease presentation. *Clin Experiment Ophthalmol* 32: 137-141.
14. Kucumen RB, Yenerel NM, Gorgun E, Kulacoglu DN, Dinc UA, et al. (2008)

- Anterior segment optical coherence tomography measurement of anterior chamber depth and angle changes after phacoemulsification and intraocular lens implantation. J Cataract Refract Surg 34: 1694-1698.
15. Sihota R, Lakshmaiah NC, Agarwal HC, Pandey RM, Titiyal JS (2000) Ocular parameters in the subgroups of angle closure glaucoma. Clin Experiment Ophthalmol 28: 253-258.
 16. Zeng Y, Liu Y, Liu X, Chen C, Xia Y, et al. (2009) Comparison of lens thickness measurements using the anterior segment optical coherence tomography and A-scan ultrasonography. Invest Ophthalmol Vis Sci 50: 290-294.
 17. Wang N, Ouyang J, Zhou W, Lai M, Ye T, et al. (2000) Multiple patterns of angle closure mechanisms in primary angle closure glaucoma. Zhonghua Yan Ke Za Zhi 36: 46-51.
 18. Ritch R, Lowe RF (1996) Angle closure glaucoma: mechanisms and epidemiology. In: Ritch R, Shields MB, Krupin T (1996) The Glaucomas. (2nd edn), CV Mosby, St. Louis.
 19. Tarongoy P, Ho CL, Walton DS (2009) Angle-closure glaucoma: the role of the lens in the pathogenesis, prevention, and treatment. Surv Ophthalmol 54: 211-225.
 20. Silver DM, Quigley HA (2004) Aqueous flow through the iris-lens channel: estimates of differential pressure between the anterior and posterior chambers. J Glaucoma 13: 100-107.
 21. Lowe RF (1977) Primary angle-closure glaucoma: a review of ocular biometry. Aust J Ophthalmol 5: 9-17.
 22. Roberts DK, Ayyagari R, Moroi SE (2008) Possible association between long anterior lens zonules and plateau iris configuration. J Glaucoma 17: 393-396.

Citation: Mei L, Zhonghao W, Zhen M, Yimin Z, Xing L (2013) Lens Thickness and Position of Primary Angle Closure Measured by Anterior Segment Optical Coherence Tomography. J Clin Exp Ophthalmol 4: 281. doi:[10.4172/2155-9570.1000281](https://doi.org/10.4172/2155-9570.1000281)

Submit your next manuscript and get advantages of OMICS Group submissions

Unique features:

- User friendly/feasible website-translation of your paper to 50 world's leading languages
- Audio Version of published paper
- Digital articles to share and explore

Special features:

- 250 Open Access Journals
- 20,000 editorial team
- 21 days rapid review process
- Quality and quick editorial, review and publication processing
- Indexing at PubMed (partial), Scopus, EBSCO, Index Copernicus and Google Scholar etc
- Sharing Option: Social Networking Enabled
- Authors, Reviewers and Editors rewarded with online Scientific Credits
- Better discount for your subsequent articles

Submit your manuscript at: www.editorialmanager.com/clinicalgroup

