

Case Report

A Case of Ovarian Ectopic Pregnancy after In-Vitro-Fertilization

Banys M^{1*}, Krawczyk N², Henze C², Born S² and Spaetling L²

¹Department of Obstetrics and Gynecology, Marienkrankenhaus Hamburg, Hamburg, Germany

²Department of Obstetrics and Gynecology, Klinikum Fulda, Fulda, Germany

³Department of Obstetrics and Gynecology, University of Duesseldorf, Germany

Abstract

The incidence of Ectopic Pregnancies (EP) following IVF is 3–5-fold higher than in general population and has been reported to be in the range of 1-5%. The 35-year old primigravida presented in our Outpatient Clinic with lower abdominal pain, nausea and vomiting 30 days after the transfer of two embryos following IVF treatment. She had pressure pain and tenderness in the right adnexal area, as well as muscular abdominal defense. Transvaginal ultrasound revealed free intraperitoneal fluid in the pouch of Douglas and a cystic mass in the right adnexa without a definite embryonal structure. A diagnostic laparoscopy revealed coagulated blood in the pelvis and partly destructed right ovarian tissue, which clinically resembled a typical corpus luteum hemorrhage. This tissue was removed. Histological examination showed ovarian ectopic pregnancy. In this case report we discuss causes and diagnostic challenges of ectopic pregnancy following IVF.

Keywords: Ectopic pregnancy, Ovarian pregnancy, In-vitro-fertilization, Laparoscopic surgery, Embryo transfer

Introduction

The first In Vitro Fertilization (IVF) resulted in tubal pregnancy and was reported by Steptoe and Edwards in 1976 [1]. Overall, the incidence of Ectopic Pregnancies (EP) following IVF is 3–5-fold higher than in general population and has been reported to be in the range of 1-5% [2-6]. This is surprising, since IVF-ET leads to a transfer of embryos to an accurate area of uterine cavity and does not aim for fallopian tubes. Thus, the exact nature of this phenomenon remains unclear. The incidence of EP after IVF has significantly declined in the last decade and is currently estimated at 0.7% [7]. The strongest risk factors for an ectopic pregnancy include tubal pathology, pelvic infection, previous

tubal or abdominal surgery and endometriosis, as well as smoking and EP in the past [8,9].

Ovarian pregnancy accounts for 0.5 – 3.0% of all EP cases [10]. In this publication we report an interesting case of this very rare condition after IVF-procedure and embryo transfer.

Case Report

The patient was a 35-year-old woman who had undergone her first IVF cycle with transfer of two embryos due to her 4-year history of primary infertility. Prior to the IVF treatment, her menstrual cycles were regular with normal hormone profile. Diagnostic laparoscopic chromopertubation revealed normal anatomy with complete distant occlusion of both fallopian tubes. Her husband's semen analysis was normal.

β -hCG increase in serum was observed following the ET but an amniotic sac could not be located via ultrasound. The pattern of β -hCG rise was adequate for patient's week of gestation. The primigravida presented in our Outpatient Clinic with lower abdominal pain, nausea and vomiting 30 days after the transfer. Physical examination showed pressure pain and tenderness in the right adnexal area, as well as beginning muscular abdominal defense. Transvaginal ultrasound revealed free intraperitoneal fluid in the pouch of Douglas and a cystic mass in the right adnexa, though a definite embryonal structure could not be observed (Figure 1). A diagnostic laparoscopy was performed. This showed abdominal adhesions, abundant coagulated blood in the pelvis and partly destructed right ovarian tissue, which clinically resembled a typical corpus luteum hemorrhage. Adhesiolysis, hemostasis and removal of necrotic ovarian tissue were performed.

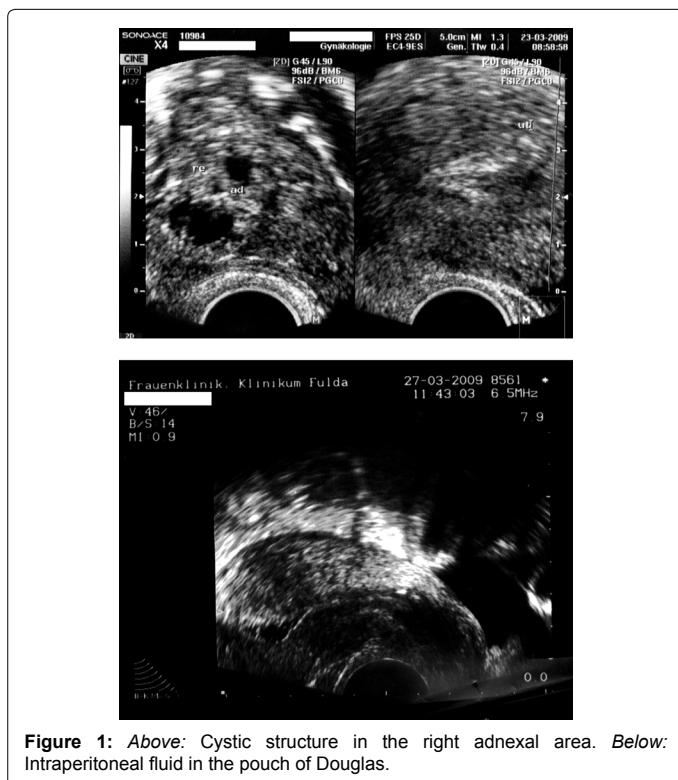


Figure 1: Above: Cystic structure in the right adnexal area. Below: Intraperitoneal fluid in the pouch of Douglas.

*Corresponding author: Dr. Malgorzata Banys, MD, Department of Obstetrics and Gynecology, Marienkrankenhaus Hamburg, Alfredstr. 9, 22087 Hamburg, Germany, Tel: +49-176 235 05735; Fax: +49-40 2546 1619; E-mail: maggybanys@yahoo.de

Received March 25, 2013; Accepted May 24, 2013; Published May 27, 2013

Citation: Banys M, Krawczyk N, Henze C, Born S, Spaetling L (2013) A Case of Ovarian Ectopic Pregnancy after In-Vitro-Fertilization. J IVF Reprod Med Genet 1: 102. doi:10.4172/2375-4508.1000102

Copyright: © 2013 Banys M, et al. This is an open-access article distributed under the terms of the Creative Commons Attribution License, which permits unrestricted use, distribution, and reproduction in any medium, provided the original author and source are credited.

Histopathological examination identified chorionic villi, as well as placental tissue and confirmed the diagnosis of an ovarian ectopic pregnancy. Postoperatively, the patient was followed up with weekly β -hCG controls, which showed decreasing levels, and had an uneventful recovery.

Discussion

Ectopic pregnancy is a major event in a woman's reproductive life and the leading cause of maternal mortality in the first trimester of pregnancy [11]. According to the Centers for Disease Control and Prevention (National Hospital Discharge Survey), EP accounts for nearly one-tenth of all pregnancy-related deaths in the United States. During the last decades the incidence of EP seemed to remain fairly stable with annual incidence rates of 100-175 per 100 000 women aged 15-44 [12,13]. Interestingly, although the incidence of EP following IVF was high in the early days of IVF, it has significantly declined during the last decade [7]. In the past, IVF was conducted mainly for tubal infertility; nowadays, IVF is done for many other indications (e.g. male infertility).

Causes of ectopic pregnancy

A large group of patients at risk of developing an EP are patients treated for infertility. The relationship between ectopic pregnancy and infertility is challenging, since EP is not only the reason for, but also the consequence of infertility [11,14-16]. Numerous risk factors, such as pelvic infection, history of tubal surgery, use of intrauterine device and smoking, may contribute both to infertility and the occurrence of EP. Furthermore, procedures commonly involved in infertility diagnosis and treatment (laparoscopy for chromopertubation, adhesiolysis, myomectomy etc.) facilitate the development of EP.

The exact cause of ectopic pregnancy remains unclear. It has been suggested that inadequate catheter insertion and excessive medium may lead to dispersion of embryos, called the "spray and drift" effect [17,18]. As to catheter positioning, a recent meta-analysis revealed no increase in ectopic pregnancy rates following "clinical touch" method of embryo transfer compared to ultrasound-guided ET, although ultrasound guidance significantly improved the chance of a live birth [19].

Ovarian pregnancy

Ovarian pregnancy is one of the rarest types of ectopic gestation, estimated at 0.5-3% of all extra uterine pregnancies [20]. Ovarian pregnancy is rarely diagnosed before the surgery due to poor clinical symptomatology and a difficult ultrasound diagnosis. The causes of primary ovarian gestation are unclear; one possibility is the reflux of the fertilized oocyte to the ovary. Other theories assume interference in the release of the ovum from the follicle, tubal malfunction and inflammatory changes in the tunica albuginea. The risk of ovarian pregnancy seems to be higher in women using intrauterine devices. Historically, following criteria defined by Spiegelberg in 1878 were used for intraoperative diagnosis of ovarian pregnancy: intact fallopian tube on the affected side, gestational sac localized in the ovary and connected to the uterus by ovarian ligament, and histopathologically confirmed ovarian tissue in the sac wall [21].

Diagnosis of ectopic pregnancy

In the past decade, the diagnosis of EP has improved markedly, resulting in earlier detection and therapy. Nonetheless, accurate diagnosis of an early EP is challenging. Moreover, infertility and its therapy may modify the relevant data about the site and clinical presentation of EP. Ultrasound examination in patients who underwent

IVF treatment is more difficult due to large stimulated ovaries which can mask ectopic implantation. Secondly, ART patients usually present with pathologic adnexal situs (endometriosis, hydrosalpinx) and peritoneal effusion is frequent, especially in the case of hyperstimulation [16]. Thus, correct identification of a haematosalpinx or ectopic sac in this patients' group is more demanding than in general population. A consensus recommends therefore early (6-8 weeks) and systematic ultrasound examinations by specialists [16,22].

Our patient presented with clinical symptoms of an EP and underwent laparoscopy. However, the surgery did not reveal an ectopic sac, both fallopian tubes were unremarkable, and the EP in the right ovary resembled a corpus luteum hemorrhage. Only after the histological examination of the removed tissue, could the diagnosis of ovarian pregnancy be confirmed. It is therefore prudent to keep in mind the possibility of the ovary being the site of ectopic pregnancy.

References

1. Steptoe PC, Edwards RG (1976) Reimplantation of a human embryo with subsequent tubal pregnancy. *Lancet* 1: 880-882.
2. Strandell A, Thorburn J, Hamberger L (1999) Risk factors for ectopic pregnancy in assisted reproduction. *Fertil Steril* 71: 282-286.
3. Society for Assisted Reproductive Technology; American Society for Reproductive Medicine (2007) Assisted reproductive technology in the United States: 2001 results generated from the American Society for Reproductive Medicine/Society for Assisted Reproductive Technology registry. *Fertil Steril* 87: 1253-1266.
4. Revel A, Ophir I, Koler M, Achache H, Prus D (2008) Changing etiology of tubal pregnancy following IVF. *Hum Reprod* 23: 1372-1376.
5. Verhulst G, Camus M, Bollen N, Van Steirteghem A, Devroey P (1993) Analysis of the risk factors with regard to the occurrence of ectopic pregnancy after medically assisted procreation. *Hum Reprod* 8: 1284-1287.
6. Dubuisson JB, Aubriot FX, Mathieu L, Foulot H, Mandelbrot L, et al. (1991) Risk factors for ectopic pregnancy in 556 pregnancies after in vitro fertilization: implications for preventive management. *Fertil Steril* 56: 686-690.
7. Centers for Disease Control and Prevention. 2010 Assisted Reproductive Technology National Summary Report. Section 2: ART Cycles Using Fresh, Nondonor Eggs or Embryos (Part A).
8. Pisarska MD, Carson SA, Buster JE (1998) Ectopic pregnancy. *Lancet* 351: 1115-1120.
9. Bouyer J, Coste J, Shojaei T, Pouly JL, Fernandez H, et al. (2003) Risk factors for ectopic pregnancy: a comprehensive analysis based on a large case-control, population-based study in France. *Am J Epidemiol* 157: 185-194.
10. Marcus SF, Brinsden PR (1995) Analysis of the incidence and risk factors associated with ectopic pregnancy following in-vitro fertilization and embryo transfer. *Hum Reprod* 10: 199-203.
11. Becker S, Solomayer E, Homung R, Kurek R, Banys M, et al. (2011) Optimal treatment for patients with ectopic pregnancies and a history of fertility-reducing factors. *Arch Gynecol Obstet* 283: 41-45.
12. Coste J, Bouyer J, Ughetto S, Gerbaud L, Fernandez H, et al. (2004) Ectopic pregnancy is again on the increase. Recent trends in the incidence of ectopic pregnancies in France (1992-2002). *Hum Reprod* 19: 2014-2018.
13. Van Den Eeden SK, Shan J, Bruce C, Glasser M (2005) Ectopic pregnancy rate and treatment utilization in a large managed care organization. *Obstet Gynecol* 105: 1052-1057.
14. Ory SJ, Nnadi E, Herrmann R, O'Brien PS, Melton LJ 3rd (1993) Fertility after ectopic pregnancy. *Fertil Steril* 60: 231-235.
15. Bernoux A, Job-Spira N, Germain E, Coste J, Bouyer J (2000) Fertility outcome after ectopic pregnancy and use of an intrauterine device at the time of the index ectopic pregnancy. *Hum Reprod* 15: 1173-1177.
16. Fernandez H, Gervaise A (2004) Ectopic pregnancies after infertility treatment: modern diagnosis and therapeutic strategy. *Hum Reprod Update* 10: 503-513.

17. Molloy D, Deambrosis W, Keeping D, Hynes J, Harrison K, et al. (1990) Multiple-sited (heterotopic) pregnancy after in vitro fertilization and gamete intrafallopian transfer. *Fertil Steril* 53: 1068-1071.
18. Marcus SF, Macnamee M, Brinsden P (1995) Heterotopic pregnancies after in-vitro fertilization and embryo transfer. *Hum Reprod* 10: 1232-1236.
19. Abou-Setta AM, Mansour RT, Al-Inany HG, Aboulghar MM, Aboulghar MA, et al. (2007) Among women undergoing embryo transfer, is the probability of pregnancy and live birth improved with ultrasound guidance over clinical touch alone? A systemic review and meta-analysis of prospective randomized trials. *Fertil Steril* 88: 333-341.
20. Raziel A, Schachter M, Mordechai E, Friedler S, Panski M, et al. (2004) Ovarian pregnancy-a 12-year experience of 19 cases in one institution. *Eur J Obstet Gynecol Reprod Biol* 114: 92-96.
21. Spiegelberg O (1878) Zur casusistik der ovarial schwangerschaft. *Arch Gynaekal* 13: 73-39.
22. Johnson N, McComb P, Gudex G (1998) Heterotopic pregnancy complicating in vitro fertilization. *Aust N Z J Obstet Gynaecol* 38: 151-155.

Citation: Banys M, Krawczyk N, Henze C, Born S, Spaetling L (2013) A Case of Ovarian Ectopic Pregnancy after In-Vitro-Fertilization. J IVF Reprod Med Genet 1: 102. doi:[10.4172/2375-4508.1000102](https://doi.org/10.4172/2375-4508.1000102)

Submit your next manuscript and get advantages of OMICS Group submissions

Unique features:

- User friendly/feasible website-translation of your paper to 50 world's leading languages
- Audio Version of published paper
- Digital articles to share and explore

Special features:

- 250 Open Access Journals
- 20,000 editorial team
- 21 days rapid review process
- Quality and quick editorial, review and publication processing
- Indexing at PubMed (partial), Scopus, EBSCO, Index Copernicus and Google Scholar etc
- Sharing Option: Social Networking Enabled
- Authors, Reviewers and Editors rewarded with online Scientific Credits
- Better discount for your subsequent articles

Submit your manuscript at: <http://www.omicsgroup.org/journals/submission>