

## Histological Effect of Nitrous Acid with Secondary Products of Nitrogen Dioxide and Nitric Oxide Exposure on Pulmonary Tissue in Mice

Masayuki Ohyama<sup>1\*</sup>, Kenji Oka<sup>2</sup>, Shuichi Adachi<sup>3</sup> and Norimichi Takenaka<sup>4</sup>

<sup>1</sup>Department of Environmental Health, Osaka Prefectural Institute of Public Health

<sup>2</sup>Department of Research Institute of Environment, Agriculture and Fisheries, Osaka Prefectural Government

<sup>3</sup>Department of Public Health, Sagami Women's University

<sup>4</sup>Department of Applied Chemistry, Graduate School of Engineering, Osaka Prefecture University

### Abstract

Numerous epidemiological studies of respiratory effects of nitrogen dioxide may have included exposures to nitrous acid, because conventional assays of nitrogen dioxide measure nitrous acid as nitrogen dioxide. A few epidemiological studies and human inhalation experiments of nitrous acid reported that nitrous acid is associated with decrements in lung function and possibly with respiratory symptoms. Moreover, our guinea pig exposure experiment of nitrous acid demonstrated that nitrous acid inducible the pulmonary emphysema-like disease and the architecture alterations of the alveolar duct centriacinar regions with the thickened interstitium. The purpose of this study was to assess the acute toxicity and the injury of exposure to nitrous acid with histopathological alterations in the respiratory tract in mice. We continuously exposed only filtered air and the filtered air with 8.4 ppm nitrous acid with secondary products of 2.8 ppm nitrogen dioxide and 7.2 ppm nitric oxide (24 hr/day) to two mice groups (n=5) for 3 weeks. We conducted histopathological analyses. We found the hyperplasia of the terminal bronchial epithelial cells with the meandering irregularly and without dysplasia in nitrous acid mice exposure group. In nitrous acid mice exposure group, we did not observe the architectural alterations such as the emphysema-like alterations which we have observed in our guinea pig exposure experiment of 3.6 ppm nitrous acid. Moreover, the collagen bundles and thickened interstitium were also indistinct in the alveolar duct centriacinar regions in this concentration of nitrous acid exposure to mice. These histopathological results suggest that the injury effects of HONO were weak.

**Keywords:** Nitrous acid; Nitrogen dioxide; Environmental pollutant; Asthma; Emphysema

**Abbreviations:** HONO: Nitrous Acid; NO<sub>2</sub>: Nitrogen Dioxide; NO: Nitric Oxide

### Introduction

Nitrous acid (HONO) exists as a gas in the atmosphere [1]. HONO is a primary product in a material combustion as well as nitrogen dioxide (NO<sub>2</sub>) [2]. The significant positive correlation coefficients were found between HONO and NO<sub>2</sub> in homes and offices [3]. Moreover, conventional assays of NO<sub>2</sub> measure HONO as NO<sub>2</sub> [4]. For these reasons, previous studies of respiratory effects of NO<sub>2</sub> may have included exposures to HONO without independent measurement of exposure and effect [5]. Although numerous studies have shown the relationship between NO<sub>2</sub> and the alteration of respiratory function or histopathological changes [6-8], there are few examinations of the biological effects of HONO such as our guinea pig exposure experiment [9]. Our results demonstrated that HONO induced some similar effects with NO<sub>2</sub> at a lower concentration than NO<sub>2</sub> such as the pulmonary emphysema-like disease and the architecture alterations of the alveolar duct centriacinar regions with the thickened interstitium. Although the fibrosis in the alveolar duct centriacinar regions of the animals exposed to NO<sub>2</sub> have been described elsewhere [6], we could not observe the increased collagen bundles in the alveolar duct centriacinar regions in the HONO exposure group. Therefore we considered that the mechanism of similar biological effects of between HONO and NO<sub>2</sub> is different.

The purpose of this study was to assess the acute toxicity and the injuriousness of exposure to nitrous acid with histopathological alterations in the respiratory tract in mice. Because the clinical emphysema does not accompany with fibrosis, we consider that the collagen bundles is an important index in order to examine pulmonary emphysema effect of the environmental pollutant.

### Materials and Methods

#### Chemicals

We purchased charcoal activated granular (a reagent prime class), soda lime No.2 (for CO<sub>2</sub> absorption), sodium nitrite (> 98.5% pure), lactic acid (> 85% pure), sodium hydrogen carbonate (> 99.5% pure), sodium carbonate (> 99.5% pure), glycerol (> 99% pure), methanol (> 99.8% pure), and eosin (> 85% pure) from Wako Pure Chemical Industries, Ltd. (Osaka, Japan). Hematoxylin (Gill's Hematoxylin 2 for HE staining) was purchased from Muto Pure Chemicals Co., Ltd. (Tokyo, Japan).

#### Experimental animals

This study was performed with the approval of the committee on animal care of the Osaka Prefectural Institute of Public Health. Ten male ICR mice (about 50 g body weight and 6 weeks of age) were purchased from SLC, Shizuoka, Japan. The animals were divided into two groups (n = 5/group), and were preliminarily housed for 2 week in each chamber with filtered air before the exposure to HONO.

\*Corresponding author: M. Ohyama, Department of Environmental Health, Osaka Prefectural Institute of Public Health, Osaka 537-0025, Japan, Tel: +81-6-6972-1321; Fax: +81-6-6972-2393; E-mail: [ohyama@iph.pref.osaka.jp](mailto:ohyama@iph.pref.osaka.jp)

Received September 29, 2011; Accepted October 22, 2011; Published October 25, 2011

**Citation:** Ohyama M, Oka K, Adachi S, Takenaka N (2011) Histological Effect of Nitrous Acid with Secondary Products of Nitrogen Dioxide and Nitric Oxide Exposure on Pulmonary Tissue in Mice. J Clin Toxicol 1:103. doi:10.4172/2161-0495.1000103

**Copyright:** © 2011 Ohyama M, et al. This is an open-access article distributed under the terms of the Creative Commons Attribution License, which permits unrestricted use, distribution, and reproduction in any medium, provided the original author and source are credited.

## The exposure chamber system

The exposure chamber system has already been described [9]. In briefly, mice were exposed to filtered air or HONO with NO<sub>2</sub> and NO in hand-made acrylic chambers for stainless cages-hanging structures. The air for the chambers was supplied by the filtration of room air with charcoal activated granular and American air filter for vinyl isolator (Clea Japan, Inc.; Tokyo, Japan). The filtered air flow was controlled by using a mass flow controller (Kojima Instruments Inc. model 8350MC-0-1-1; Kyoto, Japan) with an air flow of 20 L/min. These chambers were operated +1 mm H<sub>2</sub>O relative to atmospheric pressure. The exhaust gas of the blower was passed through a tank of soda lime, and it was discharged to the outdoors.

## HONO generation system

A HONO generation system has already been described [9,10]. In briefly, two tubing pumps (Nikko Engineering Concept, Inc. MRP-1X; Kanagawa, Japan) added two milliQ water solutions of 150 mMol sodium nitrite and 150 mMol lactic acid into one poreflon tube (Sumitomo Electric Fine Polymer, Inc. Osaka, Japan. TB-0201 (of 2 meters length)) in which the gas penetrates to the outside of the tube. The outside gas of the poreflon tube was sent into the exposure chamber with the filtered air.

HONO was continuously supplied by passing the filtered air through the HONO generator for 3 weeks. The HONO exposure was stopped during about 3 hours in every 1 week for the exchanging cages and the cleaning chambers.

## Measurement of nitrogen oxides

We used a noncontinuous method of measuring HONO employing the Harvard EPA Annular Denuder System [11,12] with two denuders in series sampling. The concentration of nitrite ion in the denuder extract was measured by the Saltzman reagent method [13]. The difference of the measured value in the first denuder and second denuder was allowed determination of the total amount of HONO that passed through the denuder system. The chamber HONO concentration was calculated from the sampled volume. Table 1 shows the concentrations of exposure HONO.

The concentrations of the contaminated NO<sub>2</sub> and NO were measured by a NOx analyzer (J-science, Inc. ECL-77A; Kyoto, Japan) after passing into the sodium carbonate annular denuders. Table 2 shows the concentrations of the contaminated NO<sub>2</sub> and NO. NOx concentration of the filtered air chamber was confirmed under the limit of detection by the using a NOx analyzer.

## Histopathological analysis

Tissue sections were affixed to microscope slides and deparaffinized. The slides were stained with hematoxylin and eosin and Elastica van Gieson, and examined under light microscopy.

## Statistical analysis

Differences between the two experimental groups were examined for statistical significance using the student's t-test. Differences associated with P values less than 0.05 were considered significant.

## Results

### Effects of HONO exposure on histopathology

At 3 weeks before and after exposure to 8.4 ppm HONO with secondary products of 2.8 ppm NO<sub>2</sub> and 7.2 ppm NO, no significant

differences were observed in the body weight between the animals in the filtered air group and the HONO exposure group. Macroscopic examination revealed that the hairs of the mice in the HONO group had a deep yellowish orange pigmentation (Figure 1).

Architectural alterations were not clear in all mice in the HONO exposure group such as the diffuse emphysemalike alterations in guinea pigs (Figure 2). The collagen bundles and the thickened interstitium were indistinct in the alveolar duct centriacinar regions in both the HONO exposure group and the filtered air group (Figure 3). However, we observed the slight multi-layering of the bronchial epithelial cells in the HONO exposure group with the meandering irregularly and without dysplasia (Figure 4-6). However, we could not observe cilia damage, goblet cell hyperplasia, and alterations in bronchi smooth muscle cells in the central airways (Figure 7).

## Discussion

The effect of environmental HONO on the health of humans is not well-understood. The effects of environmental HONO may have been considered the effects of environmental NO<sub>2</sub>, since the measurements of environmental HONO and environmental true NO<sub>2</sub> are difficult. Harris et al. suggested that the effects of HONO may have been ignored, because the outdoor ambient concentrations of HONO are less than those of NO<sub>2</sub> [14]. However, the indoor HONO concentrations

Concentration of nitrogen oxides (ppm: mg/L)†			
Sampling Period*	1st Denuder	2nd Denuder	1st Denuder-2nd Denuder
First half	10.9	2.0	8.9
Latter half	9.7	1.9	7.9
Estimate of HONO concentration (ppm:mg/L)			(8.4)

\*The total sampling periods was under 2% in all exposure period.

†The collection efficiency of sodium carbonate annular denuder is different according to type of nitrogen oxides. HONO is perfectly trapped by the coated walls, while nonacidic gases such as NO<sub>2</sub> or NO passed through the coated walls. The first denuders trap all HONO and approximately 2-3% of NO<sub>2</sub> or NO. The second denuders trap only approximately 2-3% of NO<sub>2</sub> or NO

Table 1: Concentrations of exposure HONO.

	NO <sub>2</sub> (ppm)	NO (ppm)
Average of all measured value*	2.81 ± 0.78	7.17 ± 0.96
Estimate of NOx concentration(ppm)†	(2.8)	(7.2)

\*One measured value was an average of the sampling period (30 minutes)

†Since the total sampling periods was under 2%, we estimated the concentrations of NOx

Table 2: Concentrations of the contaminated NO<sub>2</sub> and NO by the NOx analyzer.

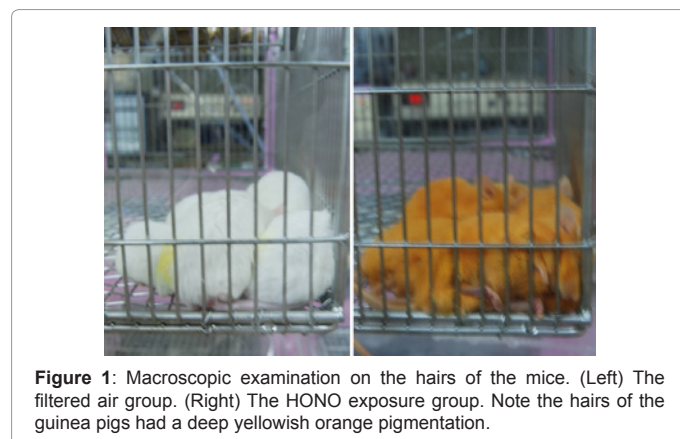
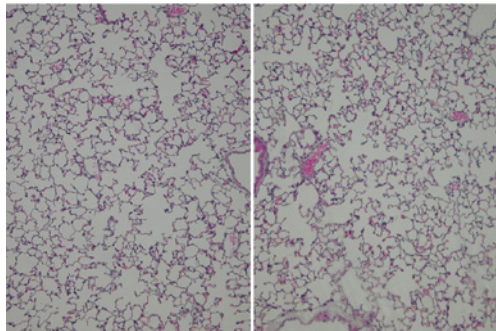
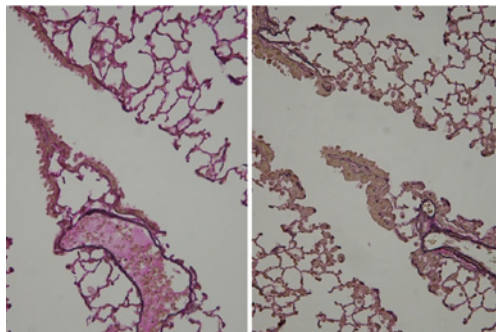


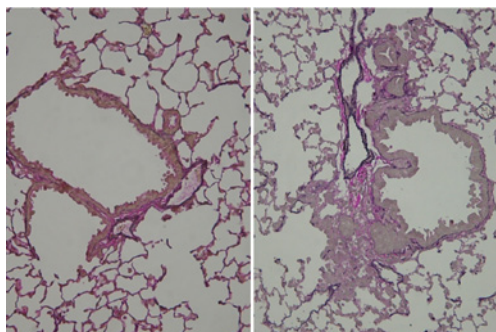
Figure 1: Macroscopic examination on the hairs of the mice. (Left) The filtered air group. (Right) The HONO exposure group. Note the hairs of the guinea pigs had a deep yellowish orange pigmentation.



**Figure 2:** Hematoxylin and eosin stain for alveolus. (Left) The filtered air group. Note the usual air space distribution in the alveolus regions. (Right) The HONO exposure group. Note the similar air space distribution to the filtered air group in the alveolus regions.



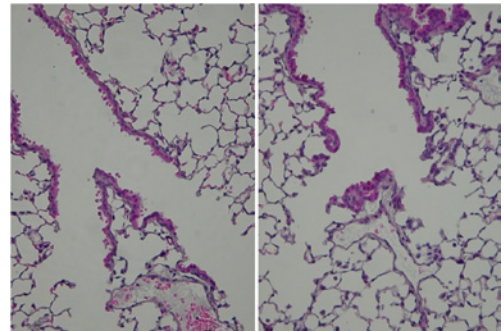
**Figure 3:** Elastica van Gieson stain for the collagen bundles and the interstitium of alveolar duct region. (Left) The filtered air group. Note the centriacinar regions of alveolar ducts were generally straight and less collagen bundles. (Right) The HONO exposure group. Note the similar architecture to the filtered air group in the alveolar duct centriacinar regions. However, we observed the replication of elastic fibers, and the terminal bronchial epithelial cells extended to the alveolar ducts. The collagen bundles were indistinct in both the HONO exposure group and the filtered air group.



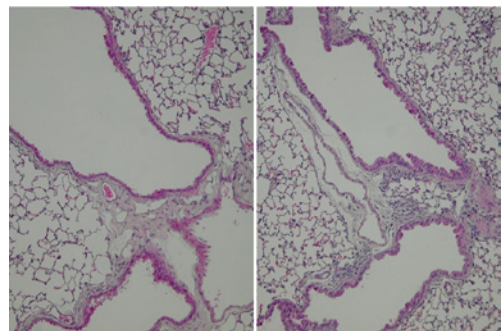
**Figure 4:** Elastica van Gieson stain for the alteration of the bronchial epithelial cells. (Left) The filtered air group. Note the slight invasion of the bronchial epithelial cells to alveolar regions. (Right) The HONO exposure group. Note the intense invasion of the bronchial epithelial cells to alveolar regions. The elastic fibers were distinct in around the invaded epithelial cells.

are not extremely different from those of  $\text{NO}_2$ . For example, in an epidemiological study on HONO, the median indoor concentration of HONO (3.10 ppb) was approximately one-fourth that of  $\text{NO}_2$  (12.76 ppb), and the maximum indoor concentration of HONO (20.55 ppb) was approximately one-third that of  $\text{NO}_2$  (59.12 ppb) [15].

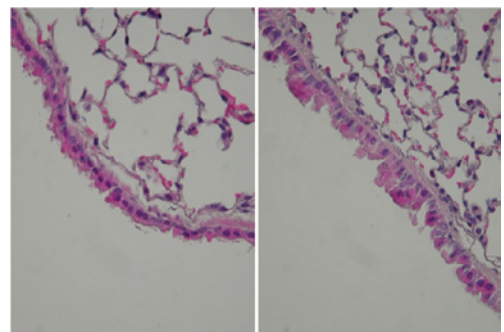
We have demonstrated that 3.6 ppm HONO exposure to guinea pigs with secondary products of 0.3 ppm  $\text{NO}_2$  and 1.6 ppm NO induced pulmonary emphysema-like alterations in the alveolar duct centriacinar regions, distortion of the centriacinar regions of alveolar ducts with extension of the bronchial epithelial cells and smooth muscle cells, and expansion of bronchial lumen [9]. However, we could not observe cilia damage, alterations in goblet cells, and collagen bundles



**Figure 5:** Hematoxylin and eosin stain for the alteration of the epithelial cells of terminal bronchioles. (Left) The filtered air group. Note the centriacinar regions of alveolar ducts were generally straight and thin alveolar walls. (Right) The HONO exposure group. Note the hyperplasia of the terminal bronchial epithelial cells with the meandering irregularly and without dysplasia.



**Figure 6:** Hematoxylin and eosin stain for the alteration of the bronchial epithelial cells. (Left) The filtered air group. Note the bronchial epithelial cells were comparatively single-layering and the compact cell size. (Right) The HONO exposure group. Note the slight multi-layering of the bronchial epithelial cells with the meandering irregularly and without dysplasia.



**Figure 7:** Hematoxylin and eosin stain for the alteration of the bronchial epithelial cells. (Left) The filtered air group. Note the bronchial epithelial cells were comparatively single-layering and the compact cell size. (Right) The HONO exposure group. Note the slight multi-layering of the bronchial epithelial cells with the expanded cytoplasm and without dysplasia.

in alveolar ducts in the guinea pigs HONO exposure experiment. In this mice experiment, we could not observe not only alterations in goblet cells and collagen bundles but also pulmonary emphysema-like alterations in spite of a higher concentration of HONO than the guinea pigs experiment.

These inflammatory alterations of mice exposed to NO<sub>2</sub> have been described elsewhere. For example, in C57BL/6 mice exposed to 20 ppm NO<sub>2</sub> for 14 h each day for up to 25 days, there was a marked progression in the extent of emphysema-like lesions with goblet cell hyperplasia and increased collagen deposition in the central airways [16].

Present indistinct results of alterations of pulmonary emphysema and collagen bundles suggest that the injury effects of HONO were weak. Mouse has no smooth muscle in the peripheral bronchus and few eosinophil granulocytes, and guinea pig has peripheral bronchi smooth muscle and rich eosinophil granulocytes. Therefore we considered that the effects of the HONO on the smooth muscle cells or eosinophil granulocytes might induce the architectural alterations in the exposure HONO.

Some epidemiologic studies have documented that outdoor NO<sub>2</sub> is associated with decreased lung function [17], and an increased number of hospital admissions for asthma [18-22]. However, it has been demonstrated that the emphysema by the animals NO<sub>2</sub> exposure experiments was accompanied with the fibrosis in the centriacinar regions of alveolar ducts. We consider that the NO<sub>2</sub> could induce the pulmonary emphysema by only high concentration such as the accompanying by the fibrosis. In human, clinical pulmonary emphysema has been defined as not accompanying by the fibrosis. Therefore, our results of mice and guinea pigs suggest that the environmental HONO is more effective in the human pulmonary emphysema than the environmental NO<sub>2</sub>.

In the present experiment, the alterations of bronchial epithelial cells might be dependent on HONO and NO<sub>2</sub>. The histopathological alterations have not been recognized in the concentrations of NO which are contaminated by the exposure to HONO gas. We want to discuss the effects of HONO on the bronchial epithelial cells by the purified HONO exposure experiment using improved HONO generator in the future.

In conclusion, the present results suggested that the injury effects of HONO were weak. We consider that the pulmonary emphysema effect of the environmental HONO is a more important than that of the environmental NO<sub>2</sub> in the human. There is still room for improvement on the HONO generator system. We will try to improve HONO generator for the purified HONO exposure experiments in the future.

#### Acknowledgments

This study was supported by a Grant-in-Aid for Scientific Research from the Ministry of Education, Culture, Sports, Science and Technology. Competing interests declaration: The authors declare they have no competing financial interests.

#### References

1. Platt U, Perner D, Harris GW, Winer AM, Pitts JN Jr (1980) Observations of nitrous acid in an urban atmosphere by differential optical absorption. *Nature* 285: 312-314.
2. Gutzwiller L, Arens F, Baltensperger U, Gaggeler HW, Ammann M (2002)

Significance of semivolatile diesel exhaust organics for secondary HONO formation. *Environ Sci Technol* 36: 677-682.

3. Khoder MI (2002) Nitrous acid concentrations in homes and offices in residential areas in Greater Cairo. *J Environ Monit* 4: 573-578.
4. Pitts JN Jr, Winer AM, Harris GW, Carter WP, Tuazon EC (1983) Trace nitrogenous species in urban atmospheres. *Environ Health Perspect* 52: 153-157.
5. Brauer M, Rasmussen TR, Kjaergaard SK, Spengler JD (1993) Nitrous acid formation in an experimental exposure chamber. *Indoor Air* 3: 94-105.
6. Freeman G, Crane SC, Stephens RJ, Furioli NJ (1968) Pathogenesis of the nitrogen dioxide-induced lesion in the rat lung: a review and presentation of new observations. *Am Rev Respir Dis* 98: 429-443.
7. Freeman G, Crane SC, Stephens RJ, Furioli NJ (1969) The subacute nitrogen dioxide-induced lesion of the rat lung. *Arch Environ Health* 18: 609-612.
8. Chitano P, Hosselet JJ, Mapp CE, Fabbri LM (1995) Effect of oxidant air pollutants on the respiratory system: insights from experimental animal research. *Eur Respir J* 8: 1357-1371.
9. Ohyama M, Oka K, Adachi S, Takenaka N (2010) Effects of nitrous acid exposure on pulmonary tissues in guinea pigs. *Inhal Toxicol* 22(11):930-936.
10. Oka K, Ohyama M, Takenaka N (2010) Development of a continuous generation system for gaseous nitrous acid using the porous polytetrafluoroethylene tube. *J Jpn Soc Atomo Environ* 45(2):73-80.
11. Koutrakis P, Wolfson JM, Slater JL, Brauer M, Spengler JD (1988) Evaluation of an annular denuder/filter pack system to collect acidic aerosols and gases. *Environ Sci Technol* 22:1463-1468.
12. Febo A, Perrino C, Cortiello M (1993) A denuder technique for the measurement of nitrous acid in urban atmospheres. *Atmospheric Environment* 27: 1721-1728.
13. Saltzman BE (1954) Colorimetric micro-determination of nitrogen dioxide in the atmosphere. *Anal Chem* 26: 1949-1955.
14. Harris GW, Carter WP, Winer AM, Pitts JN Jr, Platt U, Perner D (1982) Observations of nitrous acid in the Los Angeles atmosphere and implications for predictions of ozone-precursor relationships. *Environ Sci Technol* 16: 414-419.
15. Jarvis DL, Leaderer BP, Chinn S, Burney PG (2005) Indoor nitrous acid and respiratory symptoms and lung function in adults. *Thorax* 60: 474-479.
16. Wegmann M, Fehrenbach A, Heimann S, Fehrenbach H, Renz H, Garn H, Herz U (2005) NO<sub>2</sub>-induced airway inflammation is associated with progressive airflow limitation and development of emphysema-like lesions in C57bl/6 mice. *Exp Toxicol Pathol* 56(6):341-350.
17. Linaker CH, Coggon D, Holgate ST, Clough J, Josephs L, Chauhan AJ, Inskip HM (2000) Personal exposure to nitrogen dioxide and risk of airflow obstruction in asthmatic children with upper respiratory infection. *Thorax* 55:930-933.
18. Villeneuve PJ, Chen L, Rowe BH, Coates F (2007) Outdoor air pollution and emergency department visits for asthma among children and adults: a case-crossover study in northern Alberta, Canada. *Environ Health* 6: 40.
19. Fusco D, Forastiere F, Michelozzi P, Spadea T, Ostro B, Arca M, Perucci CA (2001) Air pollution and hospital admissions for respiratory conditions in Rome, Italy. *Eur Respir J* 17: 1143-1150.
20. Barnett AG, Williams GM, Schwartz J, Neller AH, Best TL, Petroseshevsky AL, Simpson RW (2005) Air pollution and child respiratory health: a case-crossover study in Australia and New Zealand. *Am J Respir Crit Care Med* 171:1272-1278.
21. Tsai SS, Cheng MH, Chiu HF, Wu, T.N. Yang CY (2006) Air pollution and hospital admissions for asthma in a tropical city: Kaohsiung, Taiwan. *Inhal Toxicol* 18:549-554.
22. Hinwood AL, De Klerk N, Rodriguez C, Jacoby P, Runnion T, Rye P, Landau L, Murray F, Feldwick M, Spickett J (2006) The relationship between changes in daily air pollution and hospitalizations in Perth, Australia 1992-1998: a case-crossover study. *Int J Environ Health Res* 16: 27-46.