

A Case of Thrombophlebitis Caused by Carbamazepine

Xiufeng Qi^{1,2#}, Yan Xu^{1#}, Li Yang³, Wenjing Qi¹, Jingyi Liu⁴, Yang Liu¹, Xiping Wang¹, Xuguang Gao¹ and Xianzeng Liu^{1*}

¹The Comprehensive Epilepsy Center & Neural Functional Monitoring Lab, Department of Neurology, Peking University People's Hospital, Beijing, China

²The First Hospital of Handan, China

³Department of Ultrasonology, Peking University People's Hospital, China

⁴The Capital Medical University of China, Beijing, China

[#]Contributed equally

Abstract

Objective

To present a male patient with focal epilepsy and Glanzmann's thrombasthenia who experienced Thrombophlebitis (TP) after oral administration of Carbamazepine (CBZ).

Methods

In an epileptic patient with malacia from intracerebral hemorrhage in left parietal and occipital lobes due to thrombasthenia, TP occurred following treatment of antiepileptic drug CBZ. Based on the dynamic changes of clinical manifestation and dosage of CBZ, in combination with the test results of D-Dimer, fibrinogen, prothrombin degradation products, and other laboratory tests, especially of Adenosine Diphosphate (ADP) and Arachidonic Acid (AA) evoked platelet aggregation tests, the etiology and pathophysiology of TP was explored.

Results

Six months after CBZ application with 200 mg bid, TP in the right lower extremity appeared. TP occurred in the left leg after another 3 months. The comfortlessness lightened when CBZ dosage was decreased to 100 mg bid. Furthermore, the inflammation disappeared after 4 months of cutting CBZ to 50 mg bid. However, inflammation emerged again in both legs following 100 mg bid of CBZ. D-Dimer, fibrinogen and prothrombin degradation products were 2357 ng/mL, 100 mg/dL, and 34.2 µg/mL, respectively. ADP and AA evoked platelet aggregation tests showed 4% and 26% (normal range: 71%-88%), respectively. These results demonstrated that there may be definite correlation between TP in lower extremity and CBZ administration.

Conclusion

CBZ might result in reversible peripheral TP which was associated with its dosage, but the mechanism is still not clear.

Practice implications

This case report reminds of physicians to pay more attention to the rare side effect of CBZ.

Keywords: Glanzmann's thrombasthenia; Epilepsy; Carbamazepine; Thrombophlebitis

Introduction

Carbamazepine (CBZ) has been widely used in the treatment of epilepsy, trigeminal neuralgia, restless leg syndrome, facial spasm, and other psychiatric disease since its foundation in 1960s [1]. Adverse reactions of CBZ include skin lesion, aplastic anemia, hepatic or renal disease, but rarely Thrombophlebitis (TP). Superior sagittal sinus thrombophlebitis after taking CBZ was reported by French and Japanese scholars, respectively [2-4]. In 2009, Liu et al. [5] reported a case who was admitted for carbamazepine-induced toxic epidermal necrolysis combining with thrombophlebitis [5]. Here, we present the first case in epileptic patient of peripheral thrombophlebitis with Glanzmann's thrombasthenia caused by CBZ.

Case Report

A 22-year-old man with episodic acousma and generalized convulsion was diagnosed as focal symptomatic epilepsy with encephalomalacia on the left temporal and occipital lobes 4 years ago and treated with CBZ 200 mg bid, which controlled the seizure. Six months later of CBZ treatment, swelling and pain in the internal side of his right leg and a red line along the pathway of great saphenous vein appeared for no obvious cause. Both traditional Chinese medicine and massages were applied, but without effect. The whole right leg presented with redness, swelling, pain, heat, and mobility problems

while the left leg was normal for another two weeks. Color doppler ultrasound indicated venous thrombosis in the right lower extremity with partial revascularization of the common femoral vein and superficial femoral vein, while left had no apparent abnormality. As the patient also had a case of thrombasthenia, he was unable to receive thrombolytic and anticoagulant therapy. The same symptoms occurred in the left leg and it was too painful to stand up after another 3 months. Dose-time-symptomatology relationship within the first year of CBZ administration was explained in Table 1. Color doppler ultrasound indicated no change in the right lower extremity, while left common femoral vein stasis with possible partial thrombosis could be seen.

***Corresponding author:** Xianzeng Liu, The Comprehensive Epilepsy Center & Neural Functional Monitoring Lab, Department of Neurology, Peking University People's Hospital, No. 11 South Street Xi Zhi Men Wai, Xi Cheng District, Beijing, 100044, P. R. China, Tel: +86-10-88324856; Fax: +86-10-68318386; E-mail: [E-mail: liuxianzeng2004@sina.com](mailto:liuxianzeng2004@sina.com)

Received July 05, 2013; **Accepted** December 16, 2013; **Published** December 19, 2013

Citation: Xiufeng Qi, Yan Xu, Yang Li, Wenjing Qi, Jingyi Liu, et al. (2013) A Case of Thrombophlebitis Caused by Carbamazepine. *Transl Med* 4: 121. doi:[10.4172/2161-1025.1000121](https://doi.org/10.4172/2161-1025.1000121)

Copyright: © 2013 Xiufeng Qi, et al. This is an open-access article distributed under the terms of the Creative Commons Attribution License, which permits unrestricted use, distribution, and reproduction in any medium, provided the original author and source are credited.

Another 1 year later, CBZ dose was decreased to 50 mg bid from 200 mg bid by 50 mg decrement every two weeks in the first month, and then by 50 mg decrement every two months in the following time because the patient himself and his relatives suspected that the above symptoms were probably resulted from CBZ, and the seizures were totally free. The redness, swelling and pain in the two lower limbs were obviously alleviated when the dose was 100 mg bid, and these symptoms completely disappeared when the dose was further decreased to 50 mg bid. However, the lower extremities still became swollen but without redness and pain after walking or standing for a long period of time, which would fade away after rest. Unfortunately, the dose of CBZ had to be added to 100 mg bid from 50 mg bid because epileptic seizures such as auditory hallucination recurred (Table 2), so that the inflammatory symptoms recurred in the internal side of both legs one month later. Whenever the dose was reduced to 50 mg bid, the inflammatory symptoms would go away in two weeks, but the epileptic seizures appeared again. Within the last year, the above time-dose-symptomatology locked-in phenomenon was consistently demonstrated several times by the patient himself. Fluctuation of symptomatology with change of CBZ dose could be seen in Table 2. At present, the CBZ dose was maintained at 50 mg bid, but the seizures are not controlled and mainly composed of simple partial seizures and secondarily generalized seizures. Although the inflammatory symptoms in the bilateral lower limbs have disappeared for 3 to 4 years after oral administration of CBZ, the ultrasonic blood flow imagings showed partial recanalization in some superficial and deep lower limb veins after, but the arteries were not affected with thrombosis (Figures 1-3) [6].

The past histories included intracerebral hemorrhage in left parietal and occipital lobes due to thrombasthenia 10 years ago and febrile convulsion at 2 years old. His brother died of hemorrhage of digestive tract secondary to thrombasthenia.

General physical and neurological examinations were normal except for skin pigmentation and edema seen in both lower legs and rigid calf muscles. Video-Electroencephalogram (V-EEG) showed α -activity disappeared in left occipital region with a poor amplitude modulation, and sharp-slow or spike-slow complexes emerged sporadically at left frontal and central regions. Abnormal discharges increased during sleep.

After admission, D-Dimer test result of 2357 ng/mL, fibrinogen level of 100 mg/dL, and prothrombin degradation products at a level of 34.2 μ g/mL were abnormal. Other laboratory tests, including blood and urine routine tests, biochemical analysis, and electrolyte were all within normal range. HBsAg, TPHP, HIV-Ab and HCV-Ab were all

negative. In addition, Adenosine Diphosphate (ADP) and Arachidonic Acid (AA) evoked platelet aggregation showed 4% and 26% (normal range:71%-88%), respectively.

Brain Magnetic Resonance imaging (MRI) indicated malacia focus with peripheral gliosis in left temporal and occipital lobes. Color doppler ultrasound indicated no abnormality in the bilateral upper limb veins and arteries as well as bilateral lower limb arteries. Chest radiograph showed heavy texture on both lungs. ECG monitoring detected sinus arrhythmia.

Discussion

Thrombasthenia, also called platelet dysfunction or Glanzmann's Thrombasthenia (GT), was first reported by Glanzmann in 1918. It is an autosomal recessive hereditary hemorrhagic disease characterized by an increased bleeding time and caused by low levels of platelet GP IIb/IIIa, or normal expression but absent Glucoprotein (GP) IIb/IIIa function [7]. It shows normal platelet morphology and count, absent or decreased clot retraction, but normal platelet aggregation in the presence of ristocetin. Platelet aggregation is absent in the presence of epinephrine, collagen, ADP, AA due to the dependence of these factors on fibrinogen attachment to the platelet for aggregation [8]. The clinical feature is hemorrhage, the severity of which symptom is not affected by the level of platelet, however, may reduce with age. Platelet aggregation testing shows absent or diminished response to agonists. Laboratory tests include blood routine test (blood smear), platelet function and platelet membrane GP IIb/IIIa measure. Observation of blood smear is the easiest and most direct method to make initial assessment. Blood and/or platelet transfusion as well as marrow transplantation were known as the most effective treatment methods. In recent years, it was found that the recombinant human factor VIIa had great hemostatic effect, and gene therapy is currently under study. In this case, he had intracerebral hemorrhage in left parietal and occipital lobes 10 year ago, and his brother had GT. In addition, no any other explicit causes could be used to explain the hemorrhage at that time. Lab test showed normal platelet count and morphology but obviously lower response to ADP and AA than control value after admission. So GT was diagnosed.

The patient showed episodic acousma and generalized convulsion, brain MRI indicated malacia focus with peripheral gliosis in left temporal and occipital lobes. V-EEG showed α -activity disappeared in left occipital region with a poor amplitude modulation, and sharp-slow or spike-slow wave complexes emerged sporadically at left frontal and central regions and abnormal discharges increased during sleep. This case could be diagnosed as symptomatic focal epilepsy, temporal and occipital lobe epilepsy, simple partial seizures, and secondarily

Dose (mg)	200,bid	200,bid	200,bid	200,bid
Duration (ms)	6	6.5	9	12
TP	RL: R, S, H, P (+)	RL: R, S, H, P (++)	RL & LL: R, S, H, P (++)	RL & LL: R, S, H, P (+++)
Seizure	N	N	N	N

Note: CBZ: carbamazepine; bid, twice per day; m: months; TP: Thrombophlebitis; R: Right leg; LL: Left leg; R: Redness; S: Swelling; H: Heat; P: Pain; +, ++ & +++ , the severity of these symptoms; N: No.

Table 1: Dose-time-symptomatology relationship within the first year of CBZ administration

Dose (mg)	200,bid	100,bid	50,bid	100,bid	50,bid
Step (mg/ws or ms)	0	50/p2w	50/p2m		50/p2m
TP	RL & LL: R, S, H, P (+++)	RL & LL: R, S, H, P (++)	-	RL & LL: R, S, H, P (++)	-
Seizure	N	N	Y	N	Y

Note: CBZ: carbamazepine; bid, twice per day; ws: weeks; ms: months; p2w: per two weeks; p2m: per two months; TP, thrombophlebitis; RL: right leg; LL: Left leg; R: Redness; S: Swelling; H: Heat; P: Pain; +, ++ & +++ , the severity of these symptoms; N: no; Y: yes.

Table 2: Fluctuation of symptomatology with change of CBZ dose

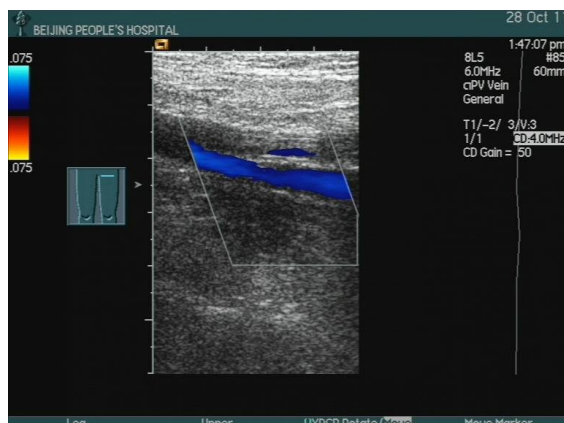


Figure 1: The ultrasonic blood flow imaging of the left superficial and deep femoral veins induced by oral administration of CBZ. The upper short and thin blue strip blood flow imaging showed a small amount of recanalization in the left superficial femoral vein after thrombosis, and the lower long and wide blue strip blood flow imaging showed the quite patency of the left deep femoral vein

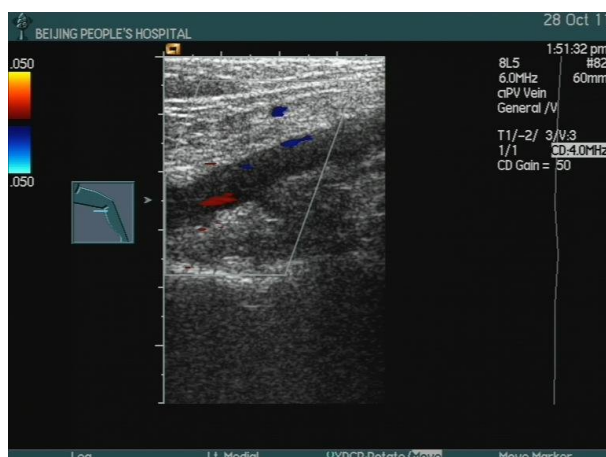


Figure 2: The ultrasonic blood flow imaging of the left popliteal vein with thrombosis induced by oral administration of CBZ. The blue spot- and plaque-like and the red plaque-like blood flow imaging showed a small amount of recanalization in the left popliteal vein

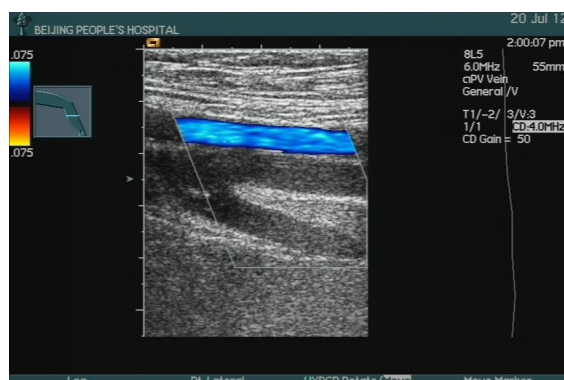


Figure 3: The ultrasonic blood flow imaging of the right femoral artery and femoral veins induced by oral administration of CBZ. The upper wide blue strip blood flow imaging showed the patency of the right superficial femoral artery, and the lower Y-shape black and white areas were right general, superficial and deep femoral veins, respectively, in which there were thrombosis

generalized seizures [9].

In this case, the first color doppler ultrasound indicated venous thrombosis in the right lower extremity with partial revascularization of common femoral vein and superficial femoral vein, while left had no apparent abnormality. 3 months later, another color doppler ultrasound indicated no change in the right lower extremity, while left common femoral vein stasis with possible partial thrombosis. Also according to the intermittent redness, swelling and pain in both legs and accessory examinations, we could make the diagnosis of TP. After admission, the patient had a D-Dimer test result of 2357 ng/mL, which is significantly beyond its normal range of less than 255 ng/ml. His fibrinogen level was at 100 mg/dL, lower than its therapeutic range between 150 mg/dl to 350 mg/dl. This further supports the TP diagnosis, and indicates that the deep venous thrombosis in lower extremity is still progressive, and in need of further treatment. However, the patient is also suffering from GT, and is unable to receive thrombolytic and anticoagulant therapy, which brings more complications to the treatment.

Several cases with combination of TP and GT have been reported within recent years, but the pathophysiology of TP in GT is not clear [10]. TP is a chronic vasculitis and chronic occlusive disease most commonly affecting medium and small vessels of limbs. It rarely occurs in the cerebral, cardiac and archenteric blood vessels. It is generally accepted that vessel wall injury, stagnation of blood flow and a hypercoagulable state are the three major factors of TP [11]. The first two risk factors did not exist in this patient. The hypercoagulable state was also excluded because he did suffer from thrombasthenia, and had a history of decreased fibrinogen, both of which predispose to induce hemorrhagic disease not thrombosis. Other risk factors such as long-term bedridden, surgery, severe internal medicine diseases, trauma, obesity, smoking, cold and damp environments, and malnutrition [12] were also not showed. However, the appearance and evolution of the thrombosis disease in both lower limbs was well correlated with the dose of CBZ and thus suggest a causal relation. Furthermore, this description of the thrombosis evolution and the dose of CBZ, that is to say, the plasmatic level of CBZ, should raise the hypothesis of a CBZ dose threshold in the development of drug induced thrombosis. In the future, larger series are required to validate this hypothesis.

CBZ, also known as Tegretol, is one kind of voltage-gated sodium channel inhibitor to treat epileptic seizures by extending action potential excitability [1]. The CBZ blood concentration of our patient was 4.1 $\mu\text{g}/\text{mL}$, which was in its therapeutic range between 4 $\mu\text{g}/\text{mL}$ and 12 $\mu\text{g}/\text{mL}$. So it is impossible that TP was secondary to CBZ poisoning. Recently, a case of deep vein thrombosis after coronary angiography in a patient using antidepressants and anxiolytics was reported. However, there was neither detailed description on the antidepressants and anxiolytics nor any analysis of the influence of these drugs on TP in this paper [13]. Several reports are now available on the biochemical and clinical effect of antipsychotic drugs on Venous Thromboembolism (VTE) [14]. The underlying biological mechanisms explaining the association between antipsychotic agents and VTE are to a large extent unknown. Numerous underlying mechanisms have been proposed. Neuroleptic drugs are known to increase, directly or indirectly, weight and higher body mass index which are recognized risk factors of VTE. These drugs could also induce sedation and consequently increase the risk of VTE by increasing immobility, and venous stasis. An enhanced aggregation of platelets has also been suggested with conventional agents in previous studies. An indirect pathway via hyperprolactinemia has been proposed. Another hypothesis was the increased levels of lupus anticoagulant and anticardiolipin antibodies induced by conventional antipsychotic agents and clozapine. However, no study demonstrated

that these antibodies were linked with an increased risk of VTE. It is known that the chemical structure of CBZ is similar to that of Tricyclic Antidepressant (TCA) which implies that their underlying mechanisms to induce thrombosis are similar.

In recent years, there have been reports stating the newly developed anti-hematologic neoplasms drug thalidomide may result in thrombus. Clinical research discovered that patients with Huppert's disease suffer with a combination of thrombus after 6 month usage of thalidomide [15]. A tentative inference on this result is that by affecting the vascular endothelial cell function as well as anticoagulant and fibrinolytic activity, the drug increases the risks of thrombus complication [16]. In addition, Bauler et al. [17] reported that CBZ could affect fluindione's anticoagulant activity. However, the mechanism was not explained.

To our knowledge, this is the first case report documenting the peripheral TP induced by CBZ in GT. CBZ is a drug commonly used in the neurology department. Its common side effects contain lesions of dermatological, Central Nervous System (CNS), hematological, cardiovascular, hepatic and renal systems, specifically showing in rash, photosensitive dermatitis, skin pigmentation, Epidermolysis Bullosa, cerebellar ataxia, blurred vision, loss of platelet and leucocyte, agranulocytosis, hypoferric anemia, aplastic anemia, arrhythmia and sinus arrest [1,2]. These symptoms may disappear after drug withdrawal. With the increasing clinical use of CBZ, especially in drug combination, severe side effects are on the rise, risking the lives of patients. Clinicians should get familiar with its pharmacokinetics, pharmacodynamics, pharmacologic features and side effects, increase the dose gradually, and discontinue medication if harmful reactions happened.

References

1. Chen Z, Xu Y, Wu F, Tang Y, Zhang S (2007) Carbamazepine-induced adverse reactions: clinical characteristics and related factors. *China Pharmacy* 18: 864-865.
2. Zhu M, Sun Y, Guo D, Zhang L (2007) Analysis of adverse drug reaction of carbamazepine reported in domestic medical journals within past 12 years. *Chin J Pharmacoepidemiol* 16: 85-87.
3. Nakaso K, Shimoda M, Yasui K, Mori M, Wakutani Y, et al. (2000) [A case of superior sagittal sinus thrombosis following long-term medication with carbamazepine]. *Rinsho Shinkeigaku* 40: 617-620.
4. Simon JP, Hanesse B, Trechot P, Aliot E, Netter P (1993) [Repeated thromboses during treatment with carbamazepine]. *Therapie* 48: 491.
5. Liu WC, Hung CC, Hwang SJ, Chen HC (2009) Extended septic thrombophlebitis in a patient with duplicated inferior vena cava: case report and review of literature. *Int Angiol* 28: 156-160.
6. GLANZMANN E (1951) [Thrombasthenia in the newborn]. *Arch Kinderheilkd* 141: 191-201.
7. Shen W, Wang H (2005) Progress in clinical diagnosis and pathogenesis of Glanzmann Thrombasthenia. *J Diagn Concepts & Pract* 4: 502-504.
8. Sebastiano C, Bromberg M, Breen K, Hurford MT (2010) Glanzmann's thrombasthenia: report of a case and review of the literature. *Int J Clin Exp Pathol* 3: 443-447.
9. Commission on Classification, and Terminology of the International League against Epilepsy (1989) Proposal for revised classification of of epilepsies and epileptic syndromes. *Epilepsia* 30: 389-399.
10. Nurden A, Mercié P, Zely P, Nurden P (2012) Deep Vein Thrombosis, Raynaud's Phenomenon, and Prinzmetal Angina in a Patient with Glanzmann Thrombasthenia. *Case Rep Hematol* 2012: 156290.
11. Esmon CT (2009) Basic mechanisms and pathogenesis of venous thrombosis. *Blood Rev* 23: 225-229.
12. Barba R, Zapatero A, Losa JE, Marco J, Plaza S, et al. (2010) Venous thromboembolism in acutely ill hospitalized medical patients. *Thromb Res* 126: 276-279.
13. Min SY, Shin JH, Lee SW, Doo E, Kim BK, et al. (2013) A case of deep vein thrombosis after coronary angiography in a patient using antidepressants and anxiolytics. *Korean Circ J* 43: 132-134.
14. Tromeur C, Couturaud F (2012) Antipsychotic drugs and venous thromboembolism. *Thromb Res* 130 Suppl 1: S29-31.
15. Bennett CL, Schumock GT, Desai AA, Kwaan HC, Raisch DW, et al. (2002) Thalidomide-associated deep vein thrombosis and pulmonary embolism. *Am J Med* 113: 603-606.
16. Wang L, Hu Y, Ye W (2010) Preliminary Inquiry of thalidomide on thrombosis function in patients with hematologic tumors. *Chin J Thrombosis and Hemostasis* 16: 124-126.
17. Bauler S, Janoly-Dumenil A, Sancho PO, Fromager F, Gouraud A, et al. (2012) Effect of carbamazepine on fluindione's anticoagulant activity: a case report. *Therapie* 67: 488-489.