

Genetic Similarities between Ethmoidal Adenocarcinoma and Colorectal Adenocarcinoma: Towards a New Targeted Therapy?

Olivier Choussy^{1,*}, Alexandre Paviot¹, Olivia Abramovici², Aude Lamy², Danièle Dehesdin¹ and Jean-Christophe Sabourin²

¹Departments of Head and Neck Surgery, Rouen University Hospital, Rouen, France

²Departments of Pathology, Rouen University Hospital, Rouen, France

Abstract

Background: To compare the genetic profile and phenotype of sinonasal Intestinal Type AdenoCarcinoma (ITAC) and colorectal adenocarcinoma.

Methods: Between 1983 and 2001, 41 patients were treated for ethmoidal adenocarcinoma at Rouen University Hospital. All pathologic specimens were reassigned according to the new 2005 World Health Organization classification. Immunohistochemical study was carried out to evaluate EGFR and CDX2 expression. Thirty-eight out of the 41 tumor specimens had sufficient DNA for *KRAS* and *EGFR* mutation analysis. SNaPshot[®] multiplex system was used to determine presence of the most common mutations (located in exons 18, 19, 20 and 21 for *EGFR* and in exon 2 [codon 12 and 13] for *KRAS*).

Results: Of the 41 patients, there were 37 men and four women. Mean age at presentation was 63.6 years (range: 40.7-86.4 years). Occupational exposure was documented for 32 patients, with 31 cases of wood exposure and one of leather exposure. Of the 38 tumors genotyped, 35 were ITAC (33 men and two women) and wood exposure was found in 29 (85%) of these patients. CDX2 expression was present in 31 out of the 35 ITAC (89%) and absent in the 3 non-intestinal adenocarcinomas. EGFR was expressed in 29 out of the 35 ITAC (83%) with different expression: 19 (56 %) 1+, 7 (21%) 2+ and 3 (6%) 3+ immunopositivity and the 3 non ITAC disclosed 1+ EGFR positivity. No *EGFR* mutation was found in the series. For *KRAS*, 5 out of the 35 ITAC (14%) disclosed *KRAS* exon 2 mutation and the 3 non-intestinal adenocarcinomas were *KRAS* wild type.

Conclusion: CDX2 immunohistochemistry could be a useful tool for discriminating ITAC. Phenotype and genotype similarities between ITAC and colorectal carcinomas could lead to clinical trials using anti-EGFR therapy in patients with locally advanced or metastatic ITAC.

Keywords: EGFR; CDX2; *KRAS*; Sinonasal adenocarcinoma; Intestinal type adenocarcinoma

Introduction

Nasoethmoidal adenocarcinomas are rare tumors with an incidence of 0.19/100 000 in Western Europe [1]. Risk factors for development of these tumors are well defined [2]. For the past 30 years, the standard treatment reported in the literature has been a combination of surgery and post-operative radiotherapy [3-24]. Five-year survival rate is currently around 60% and has not improved since the nineties [3-24].

Sinonasal Intestinal Type Adeno Carcinoma (ITAC) is histologically similar to colorectal adenocarcinoma [25]. The genetic characterization of colorectal adenocarcinoma has enabled new targeted treatments. Since 2004, numerous studies have demonstrated the efficacy of monoclonal antibodies (mAbs) targeting the Epidermal Growth Factor Receptor (EGFR) in patients with metastatic colorectal adenocarcinoma [26-29]. The efficacy of these recent targeted therapies in colorectal adenocarcinoma is restricted to patients with no somatic mutation of *KRAS* [30].

The aim of this study was to investigate molecular similarities between ITAC and colorectal adenocarcinoma in order to offer new targeted therapies for ITAC.

Patients and Methods

Forty-one cases of patients with ethmoidal carcinoma occurring between 1983 and 2007 were retrieved from the database at Rouen University Hospital. Of the 41 patients included, there were 37 men and four women. Mean age at presentation was 63.6 years (range: 40.7-86.4

years). Occupational exposure was documented for 32 patients, with 31 cases of wood exposure and one of leather exposure. Distribution was 1 T1, 18 T2, 6 T3 and 16 T4 according to the 2002 TNM classification of the American Joint Committee on Cancer. There were no patients with metastatic neck lymph node (N0) or distant visceral metastasis.

To ensure uniform tumor classification, all patient biopsies and/or surgical specimens were reassigned according to the new 2005 World Health Organization classification for ethmoidal adenocarcinoma.

Thirty-eight out of the 41 tumor specimens had sufficient tissue for immunohistochemistry and mutation analysis.

Immunohistochemical study was performed on 5 micron deparaffinized tissue sections from formalin-fixed and paraffin-embedded (FFPE) tissue with antibodies directed against CDX2 (rabbit monoclonal antibody (MoAb), EPR2764Y, Cell Marque[®]), CK20 (mouse MoAbKs20.8, Dako[®]), CK7 (mouse MoAb OV-TL 12/30, Dako[®])

***Corresponding author:** Olivier Choussy, Department of Head and Neck Surgery, Rouen University Hospital-Charles Nicolle, rue de Germont, 76031 Rouen, France, Tel: 33-232 886 614; Fax: 33-232 888 359; E-mail: olivier.choussy@chu-rouen.fr

Received January 27, 2014; **Accepted** February 20, 2014; **Published** February 22, 2014

Citation: Choussy O, Paviot A, Abramovici O, Lamy A, Dehesdin D, et al. (2014) Genetic Similarities between Ethmoidal Adenocarcinoma and Colorectal Adenocarcinoma: Towards a New Targeted Therapy? J Cell Sci Ther 5: 157. doi:10.4172/2157-7013.1000157

Copyright: © 2014 Choussy O, et al. This is an open-access article distributed under the terms of the Creative Commons Attribution License, which permits unrestricted use, distribution, and reproduction in any medium, provided the original author and source are credited.

and EGFR (mouse MoAb, CONFIRM anti-EGFR 3C6, Ventana®). Immunolabeling was revealed with Ultraview DAB revelation kit (Ventana Medical Systems®) using automated BenchMark® XT PLC (Ventana Medical Systems®).

KRAS c.34 G, c.35G, c.37G, c.38G, and *EGFR* c.2155G, c.2156G, c.2369C, c.2573T, and c.2582T mutation hot spots were assessed with a single multiplex primer extension assay with SNaPshot® technology. Briefly, tumor genomic DNA was isolated using the RecoverAll™ Total Nucleic Acid Isolation Kit for FFPE Tissues (Applied Biosystems®) as recommended by the manufacturer. *KRAS* exon 2 and *EGFR* exons 18, 20 and 21 were then simultaneously PCR amplified using specific primers, and after purification of PCR products, hot spot mutation specific primers (listed in Table 1) were extended with fluorescently labeled dideoxynucleotides using ABI PRISM SNaPshot® Multiplex Kit. Extended primers were finally separated in an automated sequencer

(ABI PRISM 3130xl Genetic analyzer) and data analysis was performed using GeneMapper® software version 4.0 (Applied Biosystems®).

Deletions, insertions, and duplications in *EGFR* exons 19 and 20 were detected using a fragment analysis assay. In short, *EGFR* exons 19 and 20 were PCR amplified in multiplex using 5' fluorescently labeled specific primers to allow PCR product separation in an automated sequencer (ABI PRISM 3130xl Genetic analyzer). Data analysis was then performed using GeneMapper® software version 4.0 (Applied Biosystems®).

Results

Three out of the 38 tumors analyzed were non-intestinal ethmoidal adenocarcinomas and the remaining 35 tumors were classified as ITAC (33 men and two women) and wood exposure was found in 29 (85%) of these patients.

Non-intestinal adenocarcinomas

CDX 2 immunohistochemistry was negative for all three tumors. EGFR positivity was low (1+) for all three tumors. All three cases were CK20 negative and two of the three cases disclosed CK7 immunostaining. No *EGFR* or *KRAS* mutation was observed.

Intestinal type adenocarcinomas

Immunohistochemistry showed CDX2 positivity in 31 of the 35 ITAC tumors (89%) (Figure 1). There was no difference in CDX2 expression since all positive ITAC disclosed the same high level of positivity. Of the four ITAC samples with no CDX2 expression, one was decalcified introducing artefact in the immunohistochemistry technique.

EGFR was positive in 29 of the 35 ITAC tumors (83%). Five cases disclosed no EGFR expression and one case was non-evaluable. EGFR expression was 1+, 2+, and 3+ respectively in 19 (56%), 7 (21%), and 3 (9%) cases (Figure 2). Thirty-three out of the 35 ITAC cases expressed CK20 (Figure 3). CK7 immunostaining was positive in 15 out of 35 ITAC cases.

EGFR genotyping was successful in all patients and no mutation was found. The same investigation for *KRAS* revealed mutations in five patients (14%): 1 C34G, 3 C35G and 1 C38G (Figure 4). All five patients with mutations had undergone wood exposure.

Discussion

Ethmoidal adenocarcinomas are rare lesions with low incidence [2]

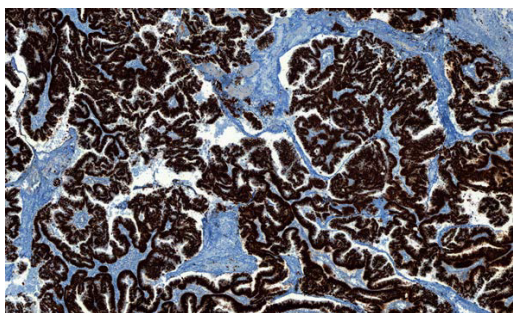


Figure 1: strong and diffuse CDX 2 immunostaining in ethmoidal intestinal type adenocarcinoma (Obj X20).

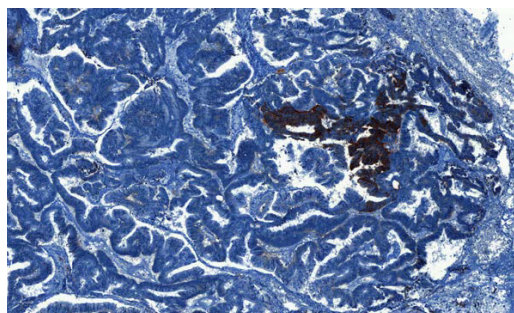


Figure 2: Strong (3+) and focal EGFR immunostaining in ethmoidal intestinal type adenocarcinoma (Obj X20).

Position of the extended nucleotide	Sequence	Strand	[c] μM
<i>EGFR</i> c.2155	5'-TGGTTAGATGGAACGCACCCGGAGC-3'	antisense	0.05
<i>EGFR</i> c.2156	5'-TAGATG TGGTTAGATGCGAACGCACCCGGAG-3'	antisense	0.09
<i>EGFR</i> c.2369	5'-TGGTTAGATG TGGTTAGATG GAAGGGCATGAGCTGC-3'	antisense	0.01
<i>EGFR</i> c.2573	5'-ATG TGGTTAGATGTGGTTAGATG AAGATCACAGATTTTGGGC-3'	sense	0.015
<i>EGFR</i> c.2582	5'-GATGTGGTTAGATGTGGTTAGATGTGGTTAGATGTGGCTGGCCAAAC-3'	sense	0.02
<i>KRAS</i> c.34	5' – TTAGATG TGGTTAGATGTGGTTAGATG TGGTTAGATGACTCTTGCCTACGCCAC – 3'	antisense	0.03
<i>KRAS</i> c.35	5' –ATGTGGTTAGATGTGGTTAGATGTGGTTAGATGTGGTTAGATGCACTCTTGCCTACGCCA – 3'	antisense	0.03
<i>KRAS</i> c.37	5' – GGTTAGATG TGGTTAGATGTGGTTAGATGTGGTTAGATGTGGTTAGATGGCACTCTTGCCTACGC – 3'	antisense	0.04
<i>KRAS</i> c.38	5' – AGATG TGGTTAGATGTGGTTAGATGTGGTTAGATGTGGTTAGATGTGGTTAGATG AGGCACTCTTGCCTACG – 3'	antisense	0.09

Table 1: List of SNaPshot® primers.

estimated at 0.19/100 000 in Western Europe [31]. Our study population with ethmoidal carcinomas was similar to that investigated in the most important series reported in the literature [2]. In most cases, our patients were 63-year-old men who had been exposed to toxic wood. At first diagnosis, the majority of lesions had large extensions (40% T4).

The new 2005 WHO classification separates ethmoidal adenocarcinomas into non-intestinal type and intestinal type adenocarcinomas (ITAC) due to the latter's histologic similarity with colorectal adenocarcinomas [32]. ITAC are more common in woodworkers [1], and this characteristic was present in our series.

CDX 2

As recently reported [33], CDX 2 is a highly specific and sensitive marker of ITAC. In our study, this marker was present in 89% of ITAC and was missing in all non-intestinal ethmoidal adenocarcinomas. Therefore, CDX 2 could be a useful tool for the diagnosis of ITAC.

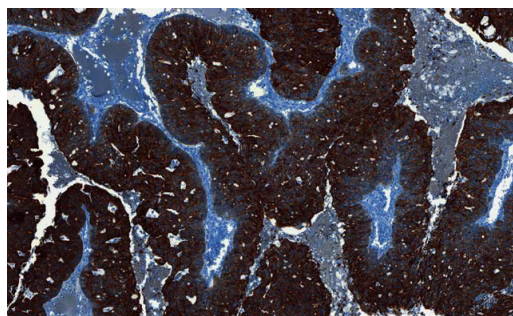


Figure 3: CK 20 expression.

Cytokeratin expression: Cytokeratin 20 is a strong marker of colorectal origin and is routinely used to discriminate metastatic tumors [34]. In contrast, CK7 is expressed in gynecological, lung, breast and genitourinary tract tissues, but can also be expressed in rectal adenocarcinoma [35]. In our series, 94% of ITAC disclosed CK20 positivity and 42% were CK7 positive like some colorectal carcinomas. The possibility of the double CK7-CK20 positivity of ITAC favors use of CDX2, which appears to be more specific.

EGFR

According to the literature, EGFR is expressed in 60 to 80% of colorectal adenocarcinomas [26,30,36-41]. In our study, EGFR expression, evaluated by immunohistochemistry, was present in 83% of ITAC. This value is similar to that observed in colorectal adenocarcinomas. For Franchi et al. [42], EGFR expression by immunohistochemistry was found in only one third of ITAC. Nevertheless, patients with intestinal type compared to non-intestinal type adenocarcinomas are more exposed to toxic wood. Exposure to wood was present in 75% of our study population, whereas only 25% of the Franchi et al. population were woodworkers. However, in the latter study, EGFR expression increased to 43% in those patients with wood exposure. The differences reported regarding intestinal type compared to non-intestinal type adenocarcinomas could be explained by exposure to toxic wood. Thus, based on immunohistochemistry EGFR expression, we suggest that similarities might exist between patients previously exposed to toxic wood products, resulting in the development of intestinal type adenocarcinomas.

In all our cases, tumor genotyping disclosed wild type *EGFR* gene status. To the best of our knowledge, we report this data on ITAC for the first time. In colorectal adenocarcinoma, *EGFR* mutations are rare and incidence is below 5% [33].

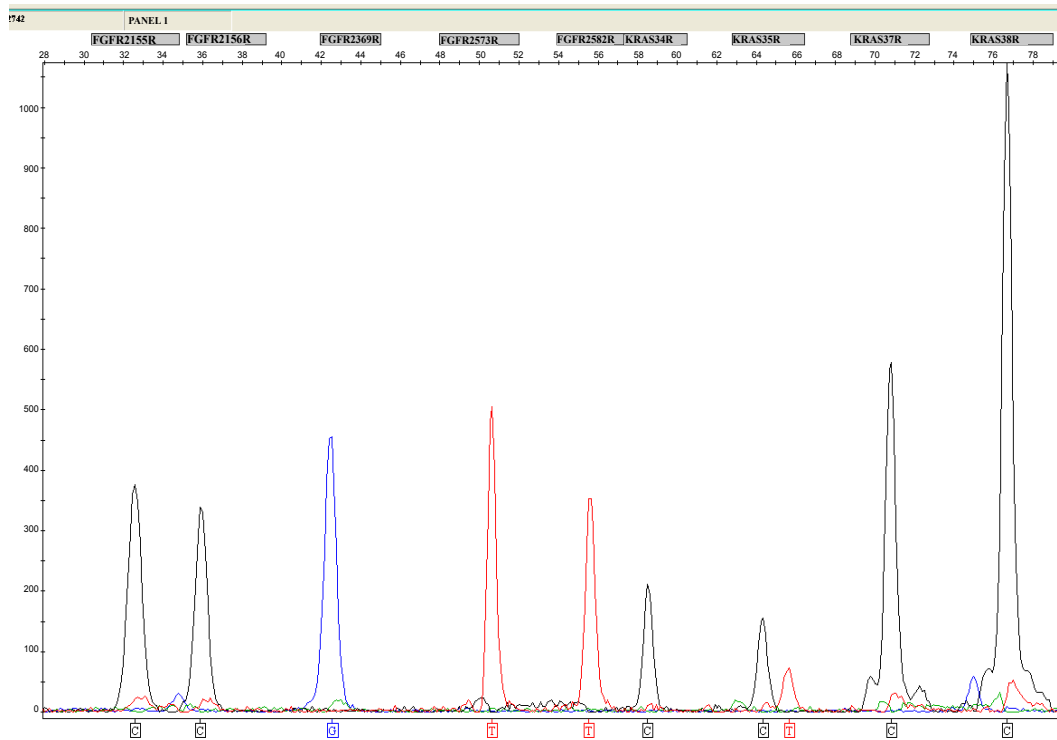


Figure 4: 35G>A; p.G12D KRAS mutation in ethmoidal intestinal type adenocarcinoma shown by SNaPshot® Technique.

	Year of publication	KRAS mutations (%)	Number of cases	Country
Bornhold [42]	2008	13	58	Denmark
Yom [46]	2005	29	15	USA
Perez [44]	1999	4	31	Spain
Saber [45]	1998	4	28	Denmark
Frattoni [43]	2006	50	17	Italy
Our series	2012	14	38	France

Table 2: distribution of KRAS mutations in ethmoidal intestinal type adenocarcinoma according to the literature.

If KRAS mutations (in codon 12 or 13) in colorectal adenocarcinoma are well known occurring in 40% of cases [43], there is a paucity of literature (Table 2) for KRAS mutations in ITAC [44-48]. The findings in the literature are diverse, probably due to the differences in the populations studied. In most recent articles KRAS mutation rate is evaluated at around 15%. This incidence of mutation is lower than in colorectal adenocarcinoma, which is around 40%.

The histopathologic similarity between ITAC and colorectal adenocarcinoma is well established. We report here, phenotype (CDX2) and genotype (EGFR and KRAS) similarities between these two types of adenocarcinoma.

Given the efficacy of anti-EGFR antibodies in the treatment of patients with wild type KRAS metastatic colorectal adenocarcinoma, we could expect similar efficiency in ITAC. Therefore, anti-EGFR targeted therapy could be proposed in order to enhance both overall survival and progression free survival in patients with wild type KRAS metastatic ITAC. New therapeutic trials are warranted to validate the strength of anti-EGFR targeted therapy in ITAC.

Acknowledgement

The authors are grateful to Nikki-Sabourin-Gibbs, Rouen University Hospital, for editing the manuscript.

References

- Hyrans VJ, Michaels LM (1988) Nonepidermoid epithelial neoplasms of the upper respiratory tract. Tumors of the upper respiratory tract and ear. AFIP, Washington, USA.
- Choussy O, Ferron C, Védrine PO, Toussaint B, Liétin B, et al. (2008) Adenocarcinoma of Ethmoid: a GETTEC retrospective multicenter study of 418 cases. Laryngoscope 118: 437-443.
- Breheret R, Laccourreye L, Jeufroy C, Bizon A (2011) Adenocarcinoma of the ethmoid sinus: retrospective study of 42 cases. Eur Ann Otorhinolaryngol Head Neck Dis 128: 211-217.
- Choussy O, Lerosey Y, Marie JP, Dhermain F, Seng SH, et al. (2001) [Adenocarcinoma of the ethmoid sinuses: results of a retrospective study in Rouen]. Ann Otolaryngol Chir Cervicofac 118: 156-164.
- Dilhuydy JM, Lagarde P, Allal AS, Bécouarn Y, Soubeyran P, et al. (1993) Ethmoidal cancers: a retrospective study of 22 cases. Int J Radiat Oncol Biol Phys 25: 113-116.
- Dulguerov P, Jacobsen MS, Allal AS, Lehmann W, Calcaterra T (2001) Nasal and paranasal sinus carcinoma: are we making progress? A series of 220 patients and a systematic review. Cancer 92: 3012-3029.
- George B, Salván D, Lubinski B, Boissonnet H, Lot G (1997) [Malignant tumors of the ethmoid sinuses. A homogeneous series of 41 cases operated on by mixed approaches]. Neurochirurgie 43: 121-124.
- Guillotte-van Gorkum ML, Nasser T, Mérol JC, Legros M, Rousseaux P, et al. (2003) [Ethmoid adenocarcinoma: a series of 17 cases]. Ann Otolaryngol Chir Cervicofac 120: 296-301.
- Harbo G, Grau C, Bundgaard T, Overgaard M, Elbrønd O, et al. (1997) Cancer of the nasal cavity and paranasal sinuses. A clinico-pathological study of 277 patients. Acta Oncol 36: 45-50.
- Heffner DK, Hyams VJ, Hauck KW, Lingeman C (1982) Low-grade adenocarcinoma of the nasal cavity and paranasal sinuses. Cancer 50: 312-322.
- Moreau JJ, Bessede JP, Heurtebise F, Moufid A, Veysset P, et al. (1998) adenocarcinome de l'ethmoïde chez les travailleurs du bois. Etude rétrospective de 25 cas. Rev Soc Fr ORL, 51: 21-26.
- Jegoux F, Ferron Ch, Malard O, Cariou G, Faure A, et al. (2004) [Ethmoid adenocarcinoma: trans-facial approach for anterior skull base resection. a series of 80 cases]. Ann Otolaryngol Chir Cervicofac 121: 213-221.
- Klintonberg C, Olofsson J, Hellquist H, Sökjer H (1984) Adenocarcinoma of the ethmoid sinuses. A review of 28 cases with special reference to wood dust exposure. Cancer 54: 482-488.
- Kraus DH, Sterman BM, Levine HL, Wood BG, Tucker HM, et al. (1992) Factors influencing survival in ethmoid sinus cancer. Arch Otolaryngol Head Neck Surg 118: 367-372.
- Liétin B, Mom T, Avan P, Llompard X, Kemeny JL, et al. (2006) [Adenocarcinomas of the ethmoid sinus: retrospective analysis of prognostic factors]. Ann Otolaryngol Chir Cervicofac 123: 211-220.
- Moreau JJ, Bessede JP, Heurtebise F, Moufid A, Veysset P, et al. (1997) [Adenocarcinoma of the ethmoid sinus in woodworkers. Retrospective study of 25 cases]. Neurochirurgie 43: 111-117.
- Shidnia H, Hornback NB, Saghafi N, Sayoc E, Lingeman R, et al. (1984) The role of radiation therapy in the treatment of malignant tumors of the paranasal sinuses. Laryngoscope 94: 102-106.
- Cantu G, Solero CL, Mariani L, Lo Vullo S, Riccio S, et al. (2011) Intestinal type adenocarcinoma of the ethmoid sinus in wood and leather workers: a retrospective study of 153 cases. Head Neck 33: 535-542.
- Claus F, Boterberg T, Ost P, Huys J, Vermeersch H, et al. (2002) Postoperative radiotherapy for adenocarcinoma of the ethmoid sinuses: treatment results for 47 patients. Int J Radiat Oncol Biol Phys 54: 1089-1094.
- Dirix P, Nuyts S, Geussens Y, Jorissen M, Vander Poorten V, et al. (2007) Malignancies of the nasal cavity and paranasal sinuses: long-term outcome with conventional or three-dimensional conformal radiotherapy. Int J Radiat Oncol Biol Phys 69: 1042-1050.
- Dirix P, Nuyts S, Vanstraelen B, Nulens A, Hermans R, et al. (2007) Post-operative intensity-modulated radiotherapy for malignancies of the nasal cavity and paranasal sinuses. Radiother Oncol 85: 385-391.
- El Ayoubi A, Poizat F, Garrel R, Costes V, Guerrier B, et al. (2009) Sinonasal adenocarcinomas reviewed. Prognostic value of WHO 2005 histological classification. Ann Otolaryngol Chir Cervicofac 126: 175-181.
- Hoppe BS, Stegman LD, Zelefsky MJ, Rosenzweig KE, Wolden SL, et al. (2007) Treatment of nasal cavity and paranasal sinus cancer with modern radiotherapy techniques in the postoperative setting--the MSKCC experience. Int J Radiat Oncol Biol Phys 67: 691-702.
- Myers LL, Nussenbaum B, Bradford CR, Teknos TN, Esclamado RM, et al. (2002) Paranasal sinus malignancies: an 18-year single institution experience. Laryngoscope 112: 1964-1969.
- Franchi A, Gallo O, Santucci M (1999) Clinical relevance of the histological classification of sinonasal intestinal-type adenocarcinomas. Hum Pathol 30: 1140-1145.
- Cunningham D, Humblet Y, Siena S, Khayat D, Bleiberg H, et al. (2004) Cetuximab monotherapy and cetuximab plus irinotecan in irinotecan-refractory metastatic colorectal cancer. N Engl J Med 351: 337-345.
- Bokemeyer C, Bondarenko I, Makhson A, Hartmann JT, Aparicio J, et al. (2009) Fluorouracil, leucovorin, and oxaliplatin with and without cetuximab in the first-line treatment of metastatic colorectal cancer. J Clin Oncol 27: 663-671.
- Jonker DJ, O'Callaghan CJ, Karapetis CS, Zalcberg JR, Tu D, et al. (2007) Cetuximab for the treatment of colorectal cancer. N Engl J Med 357: 2040-2048.
- Van Cutsem E, Peeters M, Siena S, Humblet Y, Hendlisz A, et al. (2007) Open-label phase III trial of panitumumab plus best supportive care compared with best supportive care alone in patients with chemotherapy-refractory metastatic colorectal cancer. J Clin Oncol 25: 1658-1664.
- Di Fiore F, Sesboué R, Michel P, Sabourin JC, Frebourg T (2010) Molecular determinants of anti-EGFR sensitivity and resistance in metastatic colorectal cancer. Br J Cancer 103: 1765-1772.

31. Schwaab G, M Julieron, Janot F (1997) [Epidemiology of cancers of the nasal cavities and paranasal sinuses]. *Neurochirurgie* 43: 61-63.
32. Luce D, Leclerc A, Bégin D, Demers PA, Gérin M, et al. (2002) Sinonasal cancer and occupational exposures: a pooled analysis of 12 case-control studies. *Cancer Causes Control* 13: 147-157.
33. Metzger B, Chambeau L, Begon DY, Faber C, Kayser J, et al. (2011) The human epidermal growth factor receptor (EGFR) gene in European patients with advanced colorectal cancer harbors infrequent mutations in its tyrosine kinase domain. *BMC Med Genet* 12: 144.
34. Hernandez BY, Frierson HF, Moskaluk CA, Li YJ, Clegg L, et al. (2005) CK20 and CK7 protein expression in colorectal cancer: demonstration of the utility of a population-based tissue microarray. *Hum Pathol* 36: 275-281.
35. Zhang PJ, Shah M, Spiegel GW, Brooks JJ (2003) Cytokeratin 7 immunoreactivity in rectal adenocarcinomas. *Appl Immunohistochem Mol Morphol* 11: 306-310.
36. Goldstein NS, Armin M (2001) Epidermal growth factor receptor immunohistochemical reactivity in patients with American Joint Committee on Cancer Stage IV colon adenocarcinoma: implications for a standardized scoring system. *Cancer* 92: 1331-1346.
37. Herbst RS (2004) Review of epidermal growth factor receptor biology. *Int J Radiat Oncol Biol Phys* 59: 21-26.
38. Laurent-Puig P, Cayre A, Manceau G, Buc E, Bachet JB, et al. (2009) Analysis of PTEN, BRAF, and EGFR status in determining benefit from cetuximab therapy in wild-type KRAS metastatic colon cancer. *J Clin Oncol* 27: 5924-5930.
39. Meyerhardt JA, Fuchs CS (2004) Epidermal growth factor receptor inhibitors and colorectal cancer. *Oncology (Williston Park)* 18: 35-38.
40. Saltz LB, Meropol NJ, Loehrer PJ Sr, Needle MN, Kopit J, et al. (2004) Phase II trial of cetuximab in patients with refractory colorectal cancer that expresses the epidermal growth factor receptor. *J Clin Oncol* 22: 1201-1208.
41. Spindler KL, Pallisgaard N, Lindebjerg J, Frifeldt SK, Jakobsen A (2011) EGFR related mutational status and association to clinical outcome of third-line cetuximab-irinotecan in metastatic colorectal cancer. *BMC Cancer* 11: 107.
42. Franchi A, Fondi C, Paglierani M, Pepi M, Gallo O, et al. (2009) Epidermal growth factor receptor expression and gene copy number in sinonasal intestinal type adenocarcinoma. *Oral Oncol* 45: 835-838.
43. De Roock W, Claes B, Bernasconi D, De Schutter J, Biesmans B, et al. (2010) Effects of KRAS, BRAF, NRAS, and PIK3CA mutations on the efficacy of cetuximab plus chemotherapy in chemotherapy-refractory metastatic colorectal cancer: a retrospective consortium analysis. *Lancet Oncol* 11: 753-762.
44. Bornholdt J, Hansen J, Steiniche T, Dictor M, Antonsen A, et al. (2008) K-ras mutations in sinonasal cancers in relation to wood dust exposure. *BMC Cancer* 8: 53.
45. Frattini M, Perrone F, Suardi S, Balestra D, Caramuta S, et al. (2006) Phenotype-genotype correlation: challenge of intestinal-type adenocarcinoma of the nasal cavity and paranasal sinuses. *Head Neck* 28: 909-915.
46. Pérez P, Dominguez O, González S, González S, Triviño A, et al. (1999) ras gene mutations in ethmoid sinus adenocarcinoma: prognostic implications. *Cancer* 86: 255-264.
47. Saber AT, Nielsen LR, Dictor M, Hagmar L, Mikoczy Z, et al. (1998) K-ras mutations in sinonasal adenocarcinomas in patients occupationally exposed to wood or leather dust. *Cancer Lett* 126: 59-65.
48. Yom SS, Rashid A, Rosenthal DI, Elliott DD, Hanna EY, et al. (2005) Genetic analysis of sinonasal adenocarcinoma phenotypes: distinct alterations of histogenetic significance. *Mod Pathol* 18: 315-319.