

Ten-year Long-term Endothelial Cell Changes after Iris-fixed Phakic Intraocular Lens Implantation in Korean Patients

Bong Joon Choi¹, Ja Kyun Lee² and Jong Soo Lee^{2*}

¹Lee Eye Hospital, Pusan, South Korea

²Department of Ophthalmology, School of Medicine, Pusan National University & Medical Research Institute, Pusan National University Hospital, Pusan, South Korea

*Corresponding author: Jong-Soo Lee, MD, PhD., Department of Ophthalmology, School of Medicine, Pusan National University & Medical Research Institute, Pusan National University Hospital, 1-10 Ami-Dong, Seo-Gu, Pusan 602-739, Republic of Korea, Tel: 82-51-240-7321; Fax: 82-51-242-7341; E-mail: jongsool@pusan.ac.kr; jongsooluw@gmail.com

Received date: July 01, 2014, Accepted date: August 28, 2014, Published date: August 30, 2014

Copyright: © 2014 Choi BJ, et al. This is an open-access article distributed under the terms of the Creative Commons Attribution License, which permits unrestricted use, distribution, and reproduction in any medium, provided the original author and source are credited.

Abstract

Background: To investigate quantitative and morphometric endothelial changes in phakic eyes implanted with an iris-fixed phakic intraocular lens in Korean patients during the long term follow up period.

Design: A prospective interventional case series

Participants: Sixty six eyes of 37 patients undergoing iris-fixed phakic intraocular lens (Artisan, Ophtec B.V., Groningen, The Netherlands) surgery.

Methods: We prospectively examined endothelial cell density, coefficient variations, frequency of hexagons, and endothelial cell loss in 66 phakic eyes implanted with an iris-fixed phakic intraocular lens. The effect of the anterior chamber depth and intraocular lens power were also statistically analyzed between preoperative and postoperative periods.

Main Outcome Measure: endothelial cell density, coefficient variations, frequency of hexagons.

Results: The follow-up period lasted up to 10 years. The preoperative mean ECD was 2853 ± 249 cells/mm². After postoperative 5 years, there was a significant loss of approximately 3.0% in the endothelial cell density. Eight years after the operation, there was also a significant change in the CV. There was no significant change in the hexagonality during postoperative 10 years. The preoperative anterior chamber depth and diopter of the iris-fixed phakic intraocular lens did not affect the change in the endothelial cell morphology.

Conclusions: This 10 year follow-up study of changes in endothelial cells after the implantation of an iris-fixed phakic intraocular lens showed the cell density significantly decrease first, and then the coefficient of variation in cell size changed sequent, but the hexagonality of cell was not changed from the preoperative corneal morphology. Endothelial specular microscopy examinations during regular intervals during the follow-up period are mandatory.

Keywords: Coefficient variations; Endothelial cell density; Frequency of hexagons; Endothelial cell loss; Iris-fixed phakic intraocular lens

Introduction

Iris-fixed phakic intraocular lenses (pIOLs) are used worldwide to correct high myopia, hyperopia, and astigmatism. Iris-fixed phakic intraocular lenses are used to correct severe high myopia in patients for whom laser excimer refractive surgery is not indicated [1,2]. Several studies show that the visual results of pIOLs are better than the results of refractive surgery in high myopic patients [3-7].

In 1986, refractive surgeons began to implant iris-fixed lens in phakic myopic eyes and some reports showed that persistent endothelial cell loss occurs without any intraoperative complications and results in corneal edema [8,9]. The Artisan lens (Ophtec B.V., Groningen, The Netherlands) is designed to minimizing less contact

between the iris and the IOL resulting in less halo and glare from the prism effect [10]. Several clinical studies show that the visual results of the Artisan lens are stable and predictable. The long-term effect of pIOLs on the corneal endothelium is nevertheless a point of discussion [11-15]. Therefore, we investigate to evaluate the long-term (10 year) endothelial cell changes occurring in Korean eyes with characteristic of dark pigmented iris eyes compared with less pigmented western people, after undergoing implantation of iris-fixed pIOLs to correct myopia. The effect of the anterior chamber depth (ACD) and the diopter of iris-fixed phakic intraocular lens on endothelial cell density (ECD) were statistically analyzed.

Methods

Sixty-six eyes of 37 myopic patients who were implanted with the rigid Artisan (Ophtec B.V., Groningen, The Netherlands) iris-fixed pIOL were evaluated. The inclusion criteria were an age greater than 18 years, stable myopia with a variation in spherical equivalent of less

than -0.50 diopter (D) during the 12 month preoperative period, a normal anterior segment with an ACD (i.e., the area between the corneal endothelium and the central anterior lens capsule) greater than 3.00 mm, an endothelial cell count of 2000 cells/mm² or greater, unsuccessful attempts to wear contact lenses, having contraindications to laser in situ keratomileusis based on pachymetric data or other corneal shape characteristics, and an intraocular pressure of 20 mm Hg or less. Patients with any of the following features preoperatively were considered unsuitable for iris-fixated pIOL implantation: an ACD less than 3.0 mm; chronic systemic diseases such as diabetes or hypertension; or history of ocular surgery, glaucoma, chronic uveitis, or preexisting ocular pathologic features or abnormalities. The preoperative examination included uncorrected visual acuity, best spectacle-corrected visual acuity, manifest and cycloplegic refractions, slit lamp examination, tonometry, keratometry, scotopic and mesopic pupillary diameters, videokeratography, elevation and curvature corneal maps, central corneal ultrasound pachymetry, axial length and ACD, confocal microscopy, iris evaluation (e.g., vaulting, position, color, and thickness), and indirect ophthalmoscopy.

The Artisan lenses (Ophtec B.V., Groningen, The Netherlands) have an overall length of 8.5 mm. The thickness depends on the refractive power and increases with negative power from -3.00 D to -5.50 D and has a 6.0-mm diameter optic. Surgery was performed using subtenon anesthesia with 1.5 cc of 2% lidocaine. In all patients, a 6 mm diameter optic Artisan iris-fixated pIOL was inserted through a superior 6.2 mm corneoscleral incision. The power of the pIOL was chosen to achieve emmetropia. A two-plane corneoscleral incision was centered at 12 o'clock. Two stab incisions were performed at 2 o'clock and at 10 o'clock; these incisions were directed towards the enclavation sites. After the intracameral injection of acetylcholine (Miochol-E; Bournonville Pharma, The Hague, The Netherlands) and the insertion of a viscoelastic substance (Healon GV; Pharmacia, Uppsala, Sweden), the lens was introduced using Budo forceps (Duckworth and Kent, Ltd., Baldock, United Kingdom). After subtle rotation, the lens was fixated in the horizontal axis by using a disposable enclavation needle (Ophtec B.V., Groningen, The Netherlands). The viscoelastic substance was replaced with a balanced salt solution (Alcon Laboratories Inc, Ft. Worth, TX). The wound was sutured with 5 interrupted 10-0 nylon sutures. Two weeks before surgery, neodymium-doped yttrium aluminum garnet laser iridotomy was performed at 11 o'clock to prevent the development of pupillary-block glaucoma. After each operation, topical 0.5% levofloxacin (Cravit; Santen, Osaka, Japan) and 1% prednisolone acetate (PredForte; Allergan, Irvine, CA) were applied 4 times daily for 4 weeks, and subsequently tapered. Selective suture removal was performed, depending on subjective refraction.

All patients were examined on the first postoperative day, and then at 1 month, 3 months, and 6 months after surgery. Subsequent examinations were performed annually. Each postoperative examination included visual acuity, manifest refraction and cycloplegic refraction, tonometry, slit lamp examination, endothelial specular microscopy, and indirect ophthalmoscopy. Endothelial images of the center of the cornea were obtained by the noncontact specular microscope (Noncon Robo SP-8000; Konan Medical Inc., Hyogo, Japan). The cells were analyzed using the dot method in which the centers of approximately 100 contiguous cells are marked. The mean ECD, percentage of hexagonal cells (6A), polymorphism, coefficient of variation (CV), and polymegethism were also evaluated. Endothelial cell count data were based on the average of 3 measurements obtained during each visit, including the preoperative

examinations and all postoperative examinations. We received approval from the institutional review board/ethics committee of our institution for this study. Microsoft Excel program (Microsoft, Redmond, WA) was used to compile the data. Statistical analysis was performed with a paired t test for differences between the preoperative and the postoperative ECDs. A mixed model analysis of variance was applied to assess the relationship between endothelial cell loss and the ACD, while correcting for the factors of age, gender, left or right eye, and refractive error (higher power IOLs are thicker). Differences with a p value less than 0.05 were considered statistically significant. SAS for Windows software (SAS Institute, Cary, NC) and SPSS statistical software (version 20.0, SPSS Inc., Chicago, IL) were used for data analysis.

Results

This study included 66 eyes of 37 patients (23 eyes, 12 male patients; 43 eyes, 25 female patients) who had undergone Artisan pIOL implantation for moderate to high myopia, and number of eyes and patients are demonstrated in Figure 1. The mean patient age was 28.7 years (range, 20~52 years). The mean ACD was 3.76 ± 0.22 mm (range, 3.35~4.17 mm). The mean power of the implanted pIOLs was -10.67 ± 3.84 D (range, -3.0 D to -22.0 D). Table 1 shows the patients' demographics. The mean ECD count preoperatively was 2853 ± 249 cells/mm². The changes in the ECD were 0.78%, 1.42%, 0.33%, 0.52%, 1.32%, 2.14%, 3.44%, 3.00%, 3.33%, 5.43%, 4.91%, 7.38%, 22.5% from postoperative 1 month to 10 years compared to preoperative ECD count; there was a significant mean ECD loss postoperatively at 5 years and thereafter which is not very significant with regard to the physiologic reduction rate of the cells (Table 2). At 8 years postoperatively, there was a significant decrease in the coefficient of variation (Table 3). There was no significant change in the frequency of hexagons (6A) value (Table 4).

Age (years)	28.7 ± 7.8
Male/Female (eyes)	23/43
IOL power (diopters)	-10.67 ± 3.84 (-3.0~-22.0)
Mean anterior chamber depth(mm)	3.76 ± 0.22 (3.35~4.17)
Mean preop ECD (cells/mm ²)	2853 ± 249
Coefficient variation (%)	33.9 ± 3.8
Hexagonal frequency (%)	59.3 ± 7.9

Table 1: Preoperative demographics of Korean patients implanted with an iris-fixed phakic intraocular lens.

	Eyes (Pt)	mean ECD (cells/mm ²)	Changes from Baseline (%)	P-value
Preop	66 (37)	2853 ± 249	NA	NA
Postop				
1 mo	63 (34)	2830 ± 299	-0.78	0.321
3 mo	51 (28)	2812 ± 289	-1.42	0.321
6 mo	62 (33)	2843 ± 266	-0.33	0.207
1 y	61 (32)	2838 ± 253	-0.52	0.369

2 y	63 (34)	2815 ± 252	-1.32	0.195
3 y	53 (27)	2792 ± 292	-2.14	0.325
4 y	53 (31)	2755 ± 366	-3.44	0.110
5 y	52 (26)	2767 ± 257	-3.00	0.035*
6 y	42 (21)	2758 ± 311	-3.33	0.039*
7 y	45 (23)	2698 ± 300	-5.43	<0.001*
8 y	43 (22)	2713 ± 355	-4.91	<0.001*
9 y	20 (10)	2642 ± 434	-7.38	<0.001*
10 y	6 (3)	2211 ± 146	-22.5	<0.001*
*P<0.05; NA: Not Applicable				

Table 2: Changes of endothelial cell density (ECD) after an iris-fixed phakic intraocular lens implantation.

	Eyes (Pt)	Coefficient Variation (%)	Changes from Baseline (%)	P-value
Preop	66 (37)	33.9 ± 3.8	NA	NA
Postop				
1 mo	63 (34)	33.5 ± 3.7	-0.977	0.306
3 mo	51 (28)	33.3 ± 3.0	-1.710	0.187
6 mo	62 (33)	33.4 ± 4.0	-1.498	0.229
1 y	61 (32)	33.0 ± 3.1	-2.657	0.067
2 y	63 (34)	33.2 ± 3.6	-2.066	0.156
3 y	53 (27)	33.5 ± 3.5	-1.181	0.302
4 y	53 (31)	33.9 ± 3.4	-0.000	0.458
5 y	52 (26)	34.9 ± 3.0	2.952	0.059
6 y	42 (21)	34.3 ± 3.8	1.181	0.082
7 y	45 (23)	32.9 ± 3.0	-2.952	0.077
8 y	43 (22)	32.5 ± 3.0	-4.133	0.022*
9 y	20 (10)	31.4 ± 2.5	-7.380	<0.001*
10 y	6 (3)	28.1 ± 2.2	-17.122	<0.001*
*P<0.05; NA: Not Applicable				

Table 3: Changes of coefficient variation (CA) after an iris-fixed phakic intraocular lens implantation.

	Eyes (Pt)	Hexagonal frequency (%)	Changes from Baseline (%)	P-value
Preop	66 (37)	59.3 ± 7.9	NA	NA
Postop				
1 mo	63 (34)	59.4 ± 7.2	+0.17	0.470

3 mo	51 (28)	60.5 ± 6.8	+2.00	0.196
6 mo	62 (33)	60.1 ± 7.6	+1.31	0.283
1 y	61 (32)	59.7 ± 8.5	+0.56	0.409
2 y	63 (34)	59.8 ± 8.2	+0.86	0.359
3 y	53 (27)	59.5 ± 6.7	+0.36	0.437
4 y	53 (31)	59.6 ± 5.4	+0.47	0.414
5 y	52 (26)	57.7 ± 6.9	-2.67	0.126
6 y	42 (21)	57.5 ± 8.1	-3.00	0.128
7 y	45 (23)	58.4 ± 6.7	-1.57	0.258
8 y	43 (22)	60.0 ± 5.7	+1.14	0.313
9 y	20 (10)	61.6 ± 6.1	+3.88	0.116
10 y	6 (3)	64.3 ± 6.9	+8.31	0.072

Table 4: Changes of hexagonality of cell (6A) after an iris-fixed phakic intraocular lens implantation.

Discussion

Artisan pIOLs provides precise predictability [8,11], and provides a better quality of vision without the risk of haze or corneal ectasia, compared to excimer laser refractive surgery [3,16]. The removal of a pIOL is also relatively easy if there are complications [3]. There have been concerns that the anterior chamber lens could damage the endothelial cell layer because of its proximity to the cornea. The manufacturer advises using the Artisan lens only in eyes with an ECD greater than 2000 cells/mm² and an ACD greater than 2.6 mm. Furthermore, patients are advised not to rub their eyes after lens implantation because possible warping of the peripheral cornea may cause the endothelial cell layer to rub against the IOL. Some studies have not revealed significant endothelial cell loss [14,15]. Most studies have relatively short follow-up periods and have used Caucasian patients, whereas few studies have focused on long-term endothelial cell changes in Asians [11-15]. Asian eyes have distinct characteristics (e.g., small corneal diameter and dark pigmentation of the iris that can lead to pigment dispersion during surgery) that may make IOL fixation difficult during surgery [17]. Furthermore, the enclavation points are situated more peripherally than in Caucasian eyes, which can lead to IOL movement with accompanying pupil movement and eventually lead to corneal endothelial damage [18].

This prospective study evaluated the long-term (up to 10 years) endothelial cell changes occurring in Korean eyes after the implantation of iris-fixed pIOLs to correct myopia. The effect of the ACD and the diopter of the iris-fixed phakic intraocular lens on ECD were statistically analyzed. Budo et al. [13] report a mean cell loss of 4.8% after 6 months, a mean cell loss of 1.7% after 1-2 years, and a 0.7% physiologic loss at 2-3 years. A U.S. Food and Drug Administration report by Pop and Payette [19] and a report on Asian eyes by Asano-Kato et al. [19] found no significant endothelial cell loss after 2 years of follow up. Bartels [19] and Guell et al. [20] report an increase in the ECD after 1 year of follow up. Saxena et al. [21] found an increase in the ECD after 2 years, a mean cell loss of 0.4% after 3 years, a mean cell loss of 5.3% after 5 years, and a mean cell loss of 8.5% at 7 years; the loss of the ECD was correlated with a shallow

ACD. Bourne et al. [22] report a mean cell loss of $0.6\% \pm 0.5\%$ per year over 10 years in a longitudinal study of normal un-operated eyes, correlated with the values found in previous studies conducted over shorter periods. Our long-term 10 year follow-up study showed a significant decrease of 3.0% in the ECD 5 years after pIOL implantation. Our results were opposite of those previously reported by Asano-Kato et al. [18] in their 2 year study of Asian eyes. Our results indicate the necessity of long-term evaluation of changes in ECD. Endothelial cell density is an important factor providing information about the corneal endothelium; however, the most sensitive factor that determines the function of the corneal endothelium is morphological changes such as CV and frequency of hexagons [23]. The percentage of hexagonal cells in an expression of the degree of polymorphism. The CV is an index of variability in cell

size and the mean cell size. A high CV of cell area may be an early sign of continuing endothelial cell loss. Injuries of endothelial cell density result not only loss of endothelial cell density, but also changes of morphological patterns and CV, frequency of hexagons representing this morphological patterns change independently from endothelial cell density. Endothelial cell density decreases in accordance with changes occurring with aging [24,25]. The value of 0.6% per year was used to estimate natural endothelial cell loss [22]. Hoffer et al. [26] found that the ECD decreases with age, but there is a great gap between individuals. Other changes in the corneal endothelium occurring with aging are polymegathism and pleomorphism [25,27]. Menezes et al. [14] report no morphological changes in the corneal endothelium after implantation of the pIOL.

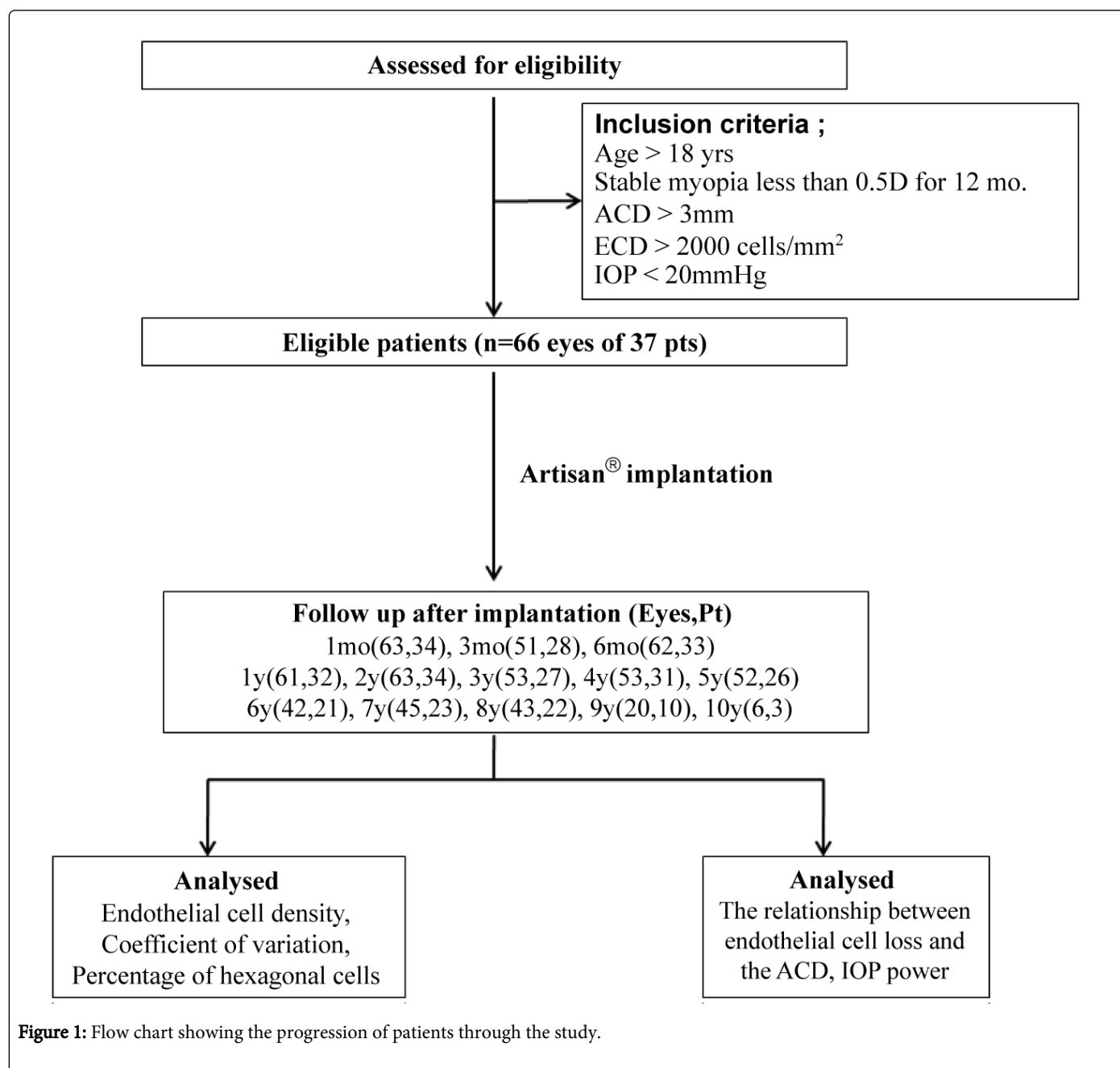


Figure 1: Flow chart showing the progression of patients through the study.

Lee et al. [28] found an increase in CV 1 month after implantation. Eight years after implantation, our study showed a significant decrease in CV and no significant change in frequency of hexagons. This reflects the increasing stability of corneal endothelial cells over time. This pattern is more compatible with corneal remodeling than with chronic cell loss, which is characterized by CV increases and finally hexagonality decreases over time. Early in the postoperative period, the frequency of hexagons can be decreased as a possible consequence of intraoperative endothelial damage and endothelial cell remodeling during the wound healing process, as reported by Lee et al. [28]; however, from 1 year after implantation there is little effect on the endothelium, which led to no significant changes. In conclusion, this 10-year follow-up study of changes occurring in endothelial cells after implantation iris-fixated phakic intraocular lens showed statistically significant changes in the cellular morphologic and density for the postoperative 10 years, which is not very significant with regard to the physiologic reduction rate of the cells. The study is further limited by the small number of patients available for long term follow-up examinations; for example at 5 years, data from 52 eyes of the 26 patients were available, but at 10 years, from only 6 eyes of 3 patients. Further studies with a larger number of patients with longer follow-up period are needed to determine the long term effects of Artisan pIOLs. In conclusion this study, endothelial specular microscopy examinations before surgery and during regular intervals during the follow-up period are mandatory when using this type of pIOL.

Acknowledgement

In this study, there is no conflict of interest, commercial affiliations, consultations, stock or equity interests, source of financial grants and other funding.

References

1. Kim SH, Kim IC, Chung YT (2001) Results of Nuvita Phakic Anterior Chamber Intraocular Lens for High Myopia. *J Korean Ophthalmol Soc* 42: 1721-1728.
2. Menezo JL, Peris-Martínez C, Cisneros AL, Martínez-Costa R (2004) Phakic intraocular lenses to correct high myopia: Adatomed, Staar, and Artisan. *J Cataract Refract Surg* 30: 33-44.
3. Malecaze FJ, Hulin H, Bierer P, Fournié P, Grandjean H, et al. (2002) A randomized paired eye comparison of two techniques for treating moderately high myopia: LASIK and artisan phakic lens. *Ophthalmology* 109: 1622-1630.
4. Applegate RA, Howland HC (1997) Refractive surgery, optical aberrations, and visual performance. *J Refract Surg* 13: 295-299.
5. Alió JL, de la Hoz F, Pérez-Santonja JJ, Ruiz-Moreno JM, Quesada JA (1999) Phakic anterior chamber lenses for the correction of myopia: a 7-year cumulative analysis of complications in 263 cases. *Ophthalmology* 106: 458-466.
6. Baikoff G, Joly P (1990) Comparison of minus power anterior chamber intraocular lenses and myopic epikeratoplasty in phakic eyes. *Refract Corneal Surg* 6: 252-260.
7. Colin J, Mimouni F, Robinet A, Conrad H, Mader P (1990) The surgical treatment of high myopia: comparison of epikeratoplasty, keratomileusis and minus power anterior chamber lenses. *Refract Corneal Surg* 6: 245-251.
8. Fechner PU, Worst JF (1989) A new concave intraocular lens for the correction of high myopia. *European Journal of Implant and Refractive Surgery* 1: 41-43.
9. Fechner PU, Strobel J, Wichmann W (1991) Correction of myopia by implantation of a concave Worst-iris claw lens into phakic eyes. *Refract Corneal Surg* 7: 286-298.
10. Izak MG, Izak A (2004) Inflammatory reaction associated to Artisan phakic refractive IOL implantation. In: Budo CJR (ed), *The ARTISAN Lens*, (1stedn), Highlights of Ophthalmology, Panama.
11. Menezo JL, Aviño JA, Cisneros A, Rodriguez-Salvador V, Martinez-Costa R (1997) Iris claw phakic intraocular lens for high myopia. *J Refract Surg* 13: 545-555.
12. Landesz M, van Rij G, Luyten G (2001) Iris-claw phakic intraocular lens for high myopia. *J Refract Surg* 17: 634-640.
13. Budo C, Hessloehl JC, Izak M, Luyten GP, Menezo JL, et al. (2000) Multicenter study of the Artisan phakic intraocular lens. *J Cataract Refract Surg* 26: 1163-1171.
14. Menezo JL, Cisneros AL, Rodriguez-Salvador V (1998) Endothelial study of iris-claw phakic lens: four year follow-up. *J Cataract Refract Surg* 24: 1039-1049.
15. Benedetti S, Casamenti V, Benedetti M (2007) Long-term endothelial changes in phakic eyes after Artisan intraocular lens implantation to correct myopia: five-year study. *J Cataract Refract Surg* 33: 784-790.
16. Maloney RK, Nguyen LH, John ME (2002) Artisan phakic intraocular lens for myopia: short-term results of a prospective, multicenter study. *Ophthalmology* 109: 1631-1641.
17. Matsuda LM, Woldorff CL, Kame RT, Hayashida JK (1992) Clinical comparison of corneal diameter and curvature in Asian eyes with those of Caucasian eyes. *Optom Vis Sci* 69: 51-54.
18. Asano-Kato N, Toda I, Hori-Komai Y, Sakai C, Fukumoto T, et al. (2005) Experience with the Artisan phakic intraocular lens in Asian eyes. *J Cataract Refract Surg* 31: 910-915.
19. Pop M, Payette Y (2004) Initial results of endothelial cell counts after Artisan lens for phakic eyes: an evaluation of the United States Food and Drug Administration Ophtec Study. *Ophthalmology* 111: 309-317.
20. Güell JL, Vázquez M, Malecaze F, Manero F, Gris O, et al. (2003) Artisan toric phakic intraocular lens for the correction of high astigmatism. *Am J Ophthalmol* 136: 442-447.
21. Saxena R, Boekhoorn SS, Mulder PG, Noordzij B, van Rij G, et al. (2008) Long-term follow-up of endothelial cell change after Artisan phakic intraocular lens implantation. *Ophthalmology* 115: 608-613.
22. Bourne WM, Nelson LR, Hodge DO (1997) Central corneal endothelial cell changes over a ten-year period. *Invest Ophthalmol Vis Sci* 38: 779-782.
23. Waring GO 3rd, Bourne WM, Edelhauser HF, Kenyon KR (1982) The corneal endothelium. Normal and pathologic structure and function. *Ophthalmology* 89: 531-590.
24. Laule A, Cable MK, Hoffman CE, Hanna C (1978) Endothelial cell population changes of human cornea during life. *Arch Ophthalmol* 96: 2031-2035.
25. Laing RA, Sanstrom MM, Berrospi AR, Leibowitz HM (1976) Changes in the corneal endothelium as a function of age. *Exp Eye Res* 22: 587-594.
26. Hoffer KJ, Kraff MC (1980) Normal endothelial cell count range. *Ophthalmology* 87: 861-866.
27. Mishima S (1982) Clinical investigations on the corneal endothelium-XXXVIII Edward Jackson Memorial Lecture. *Am J Ophthalmol* 93: 1-29.
28. Lee ES, Cho YJ, Kim EK (2005) Short-term change in corneal endothelium after iris-fixed phakic intraocular lens insertion. *J Korean Ophthalmol Soc* 46: 410-415.