

## Case Report of Tadalafil-Induced Central Serous Chorioretinopathy

Ugur Acar<sup>1\*</sup>, Bekir Kucuk<sup>1</sup>, Abdullah Agin<sup>1</sup>, Mustafa Koc<sup>2</sup> and Gungor Sobaci<sup>1</sup>

<sup>1</sup>Department of Ophthalmology, Hacettepe University, Faculty of Medicine, Ankara, Turkey

<sup>2</sup>Department of Ophthalmology, Ulucanlar Research and Education Hospital, Ankara, Turkey

\*Corresponding author: Ugur Acar, Department of Ophthalmology, Hacettepe University, Faculty of Medicine, Ankara, Turkey, Tel: +90532 548 8893; Fax: +90312 36377 78; E-mail: druguracar@gmail.com

Received date: Aug 17, 2014, Accepted date: Sep 16, 2014, Published date: Sep 19, 2014

Copyright: © 2014 Acar U, et al. This is an open-access article distributed under the terms of the Creative Commons Attribution License, which permits unrestricted use, distribution, and reproduction in any medium, provided the original author and source are credited.

### Abstract

We aimed to report a case of central serous chorioretinopathy (CSC) in a 47 year-old man who used tadalafil 20 mg, three times on alternate days for erectile dysfunction. Since the patient's incidental ophthalmologic examination two weeks before the drug intake was entirely normal, our case report strongly supported that the tadalafil had caused CSC.

**Keywords:** Central serous chorioretinopathy; PDE-5 inhibitors; Side-effect; Tadalafil.

### Introduction

Central serous chorioretinopathy (CSC) is a retinal disorder in which there is a serous exudative retinal detachment, although exact etiopathogenesis is unknown [1-3]. In typical clinical presentation, patients with CSC have complaints of micropsia, metamorphopsia, moderate to severe impairment of visual acuity and/or central relative scotoma, hyperopic shift in refraction and color and contrast sensitivity reduction [3]. Visual acuity of the patients usually resolves spontaneously; however, some patients have recurrent episodes that can lead to permanent visual loss [3].

Tadalafil (Cialis®, Lilly, Ortaköy, İstanbul) is a relatively new phosphodiesterase (PDE)-5 inhibitor which is one of the most commonly used in the case of male erectile dysfunction. However, PDE-5 inhibitors have been associated with some ocular side effects such as eyelid edema, subconjunctival hemorrhage, photophobia, mydriasis, dyschromatopsia, and nonarteritic anterior ischemic optic neuropathy [4]. Although CSC was reported in patients taking tadalafil [5-7], there are some reported studies [8-10] that supporting the PDE-5 inhibitors do not cause the CSC.

In this case report, we aimed to present a patient with CSC which occurred after using tadalafil and started to resolve right after terminating of the drug intake.

### Case Report

A 47 year-old male patient was admitted to our clinic with the complaint of a blurred vision in his left eye especially in the near vision. On a detailed ophthalmologic examination of the patient; the best corrected visual acuity (BCVA) was 20/20 in the right eye, 5/20 (with +0.75+0.25x55° correction) in the left eye, color vision was 12/12 in the right eye, 2/12 in the left eye. The anterior segment of both eyes and the fundus examination in the right eye were normal, whereas there was an exudative retinal detachment in the left eye's macula (Figure 1).

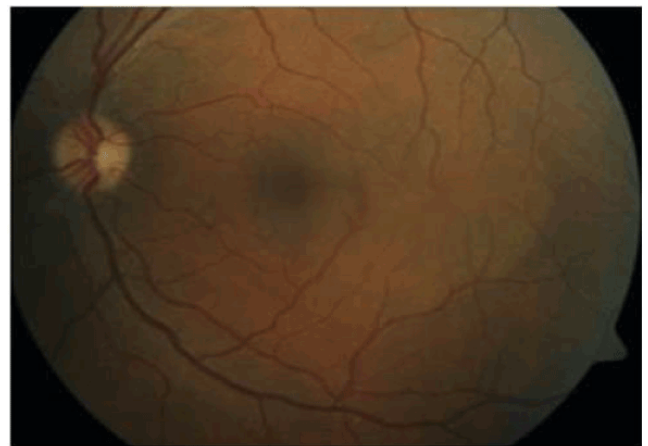
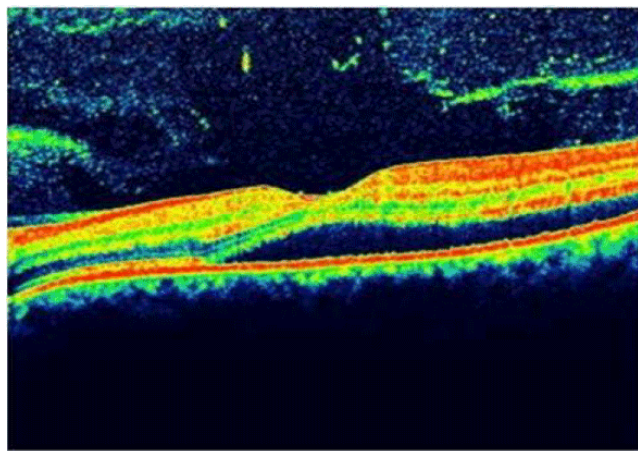


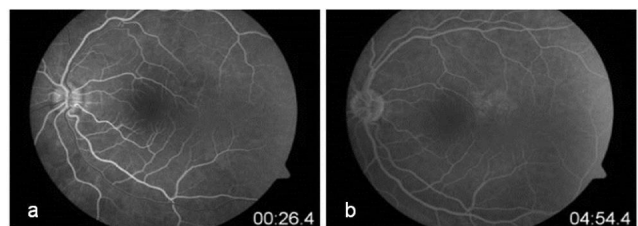
Figure 1: View of the fundus photography of the left eye.

Spectral domain optical coherence tomography (SD-OCT, Heidelberg Engineering, Germany) and early and late phase of the fundus fluorescein angiography (Carl Zeiss Model FF 450 Plus) imagings of the patient's left eye demonstrated that subretinal fluid accumulation was compatible with CSC (Figure 2 and 3).

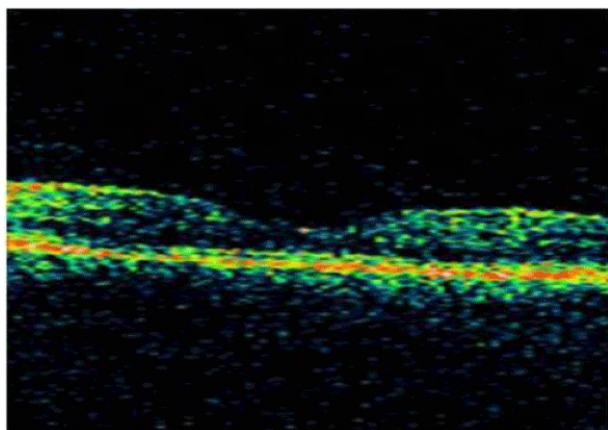
We noticed that the patient had come to our department two weeks before for examination of refraction without any other complaint. On ophthalmic examination of that day; BCVA was 20/20 in left eye with -1.00 -0.25x145° correction, anterior and posterior segments of the both eyes were normal, and entirely incidental captured (by a research assistant for improving own experience) time domain optical coherence tomography (Stratus OCT, Carl Zeiss Meditec, Dublin, CA, USA) imagings were entirely normal (Figure 4). That day, only glasses for distance were prescribed to the patient.



**Figure 2:** Image of the spectral domain optical coherence tomography of the left eye. It is seen that the exudative retinal detachment and the subretinal fluid accumulation in the macula.



**Figure 3:** Images of early (a) and late (b) phase of the fundus fluorescein angiography of the left eye.



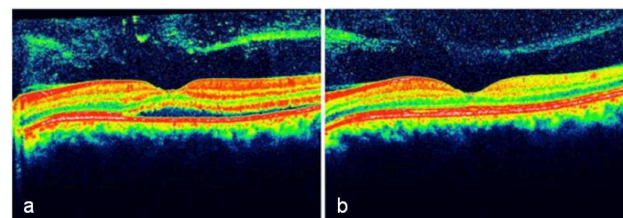
**Figure 4:** View of the incidentally captured time domain optical coherence tomography of the left eye, two weeks before the presentation for blurred vision in the left eye.

We found out that the patient's complaints began after taking tadalafil 20 mg, three times on alternate days for erectile dysfunction, despite his urologist recommended 20 mg two times per week. During

this two week period of the two ophthalmic examinations, he did not take any other medications.

He has never smoked or drunk, the remaining systemic examination findings were normal, and type A personality was not detected in his psychometric analysis which was conducted by the Psychiatry Department.

Based on all these findings, we warned the patient that he should stop taking the drug. Two weeks after the discontinuation of the drug, BCVA was 10/20 (with -0.25 -0.25x145° correction), and there was a remarkable reduction in the subretinal fluid (Figure 5A). Four weeks later BCVA was 16/20 (with -0.50 -0.25x145° correction) and six weeks later, BCVA reached the level of 20/20 (with -0.75 -0.25x145° correction) and the subretinal liquid completely disappeared (Figure 5B). The patient's complaint of blurred vision also completely terminated.



**Figure 5:** Views of the spectral domain optical coherence tomography of the left eye A) two weeks and B) six weeks after the discontinuation of the drug.

## Discussion

CSC is a condition characterized by the accumulation of subretinal fluid at the posterior pole of the fundus, causing single or multiple areas of serous retinal detachment [1-3]. Although the exact mechanism of CSC is not understood, it is thought to be associated with type A personality and elevated glucocorticoid levels. Other factors associated with CSC include the usage of systemic steroid, antibiotics, and antihistaminic medications, pregnancy, use of alcohol and tobacco, autoimmune diseases, and untreated hypertension [1]. When our patient was admitted to our clinic due to a complaint of blurred vision, none of the conditions mentioned above which are thought to initiate the CSC could be detected in our patient. The only positive sign to be associated with the CSC in his history was that the patient had received the third dose of tadalafil last night.

However, in literature, there are some reported studies [8-10] supporting the idea of PDE-5 inhibitors are safe drugs with no visual disturbance. Cordell et al. [8] investigated whether the daily use of tadalafil (n=85) or sildenafil citrate (n=77) for 6 months led to any changes in the retinal function or not. They found out that the daily administration over a prolonged time of tadalafil or sildenafil did not lead to any abnormalities in electroretinographic variables or visual functions and anatomic assessments of retina.

French and Margo [9] did not determine any association between the usage of PDE-5 inhibitor and CSC, in their post-marketing surveillance series which had 577 men with newly diagnosed CSC. However post-marketing studies have some limitations. For instance, they cannot assure if the patients have taken the drug regularly. Even if

they have, the studies still cannot provide any posology, or information on other medical conditions.

Damar et al. [10] assessed the short-term effects of the recommended starting dose of sildenafil citrate on visual functions and CSC development in 43 patients who used the drug at the dosage of 50 mg, 2-3 times per week for a month. It was concluded that the therapeutic dose of sildenafil citrate therapy did not cause CSC or any other visual disorder. We thought that this study did not contain sufficient numbers of patients to achieve a certain result.

Although, among the urologist there is no consensus on the dosage of tadalafil, individual dose adjustment is usually recommended. The prospectus information of tadalafil as follows: the recommended initial dose of tadalafil for use as needed is 10 mg, and it may be increased to 20 mg or decreased to 5 mg, based on individual efficacy and tolerability. The recommended initial dose of tadalafil for once daily use is 2.5 mg and it may be increased to 5 mg, based on individual efficacy and tolerability. Tadalafil 5 mg once daily or 20 mg two times per week has been proposed by his urologist to our patient. Since tadalafil has the longest half-life (approximately 18 hours) among the PDE-5 inhibitors, use of 20 mg dose of tadalafil on alternate days is generally not recommended [11].

Our patient's complaints immediately began after receiving the third dose of tadalafil 20 mg on the fifth day and his symptoms and pathological fundus findings resolved completely six weeks after stopping the drug intake. There was not a history of medication containing corticosteroid.

It is well-known that CSC generally affects middle-aged men. It is the same age group with the patient who use PDE-5 inhibitors. It is thought that the PDE-5 inhibitors also partly have an inhibitory effect on PDE-6 enzyme which is located in the retinal photoreceptors and acts photo transduction cascade [10]. Another aspect is that they cause a decrease in the retinal and choroidal blood flow, which is also believed to occur in the pathogenesis of CSC [3]. In the fact that the eyes with CSC have thicker subfoveal choroidal thickness compared to fellow eyes and healthy eyes of age matched normal patients, supports this opinion [12,13]. Enhanced depth imaging OCT (EDI-OCT) is an extremely useful device that shows the difference of the choroidal thickness in retinal pathologies such as CSC [12,13].

The power of our case report and its superior aspect compared with the other case reports were thanks to the findings of the patients's ophthalmic examination carried out two weeks earlier and the incidentally captured images of Stratus OCT (SD-OCT is not available in our clinic, so we took the patient's follow-up macular images with SD-OCT in another eye clinic) were completely normal and changing objective refraction errors throughout the disorder were well-documented. However, if EDI-OCT could be used in follow-up examinations it could be better.

In the fact that our patient didn't have any of the known risk factors of CSC, and his detail ophthalmologic examination two weeks before

tadalafil intake was entirely normal, and he received the third dose of tadalafil 20 mg last night, and the symptoms, and findings of CSC resolved spontaneously immediately after ceasing the drug intake, tadalafil seems to be most likely caused CSC.

In conclusion, urologists should advise the patients who receive a PDE-5 inhibitor, not to use more than the recommended dose as in our case and when the patient happen to experience negative visual symptoms, the drug intake must be ceased and they should seek a medical help.

## References

1. Haimovici R, Koh S, Gagnon DR, Lehrfeld T, Wellik S; Central Serous Chorioretinopathy Case-Control Study Group (2004) Risk factors for central serous chorioretinopathy: a case-control study. *Ophthalmology* 111: 244-249.
2. Regillo C, Chang TS, Johnson MW, et al. (2007) Retina and Vitreous. Section 12. Basic and Clinical Science Course. San Francisco, American Academy of Ophthalmology pp-51-54.
3. Gemenetzi M, De Salvo G, Lotery AJ (2010) Central serous chorioretinopathy: an update on pathogenesis and treatment. *Eye (Lond)* 24: 1743-1756.
4. Laties AM (2009) Vision disorders and phosphodiesterase type 5 inhibitors: a review of the evidence to date. *Drug Saf* 32: 1-18.
5. Türkçü FM, Yüksel H, Şahin A, Murat M, Bozkurt Y, et al. (2013) Central serous chorioretinopathy due to tadalafil use. *Int Ophthalmol* 33: 177-180.
6. Gordon-Bennett P, Rimmer T (2012) Central serous chorioretinopathy following oral tadalafil. *Eye (Lond)* 26: 168-169.
7. Aliferis K, Petropoulos IK, Farpour B, Matter MA, Safran AB (2012) Should central serous chorioretinopathy be added to the list of ocular side effects of phosphodiesterase 5 inhibitors? *Ophthalmologica* 227: 85-89.
8. Cordell WH, Maturi RK, Costigan TM, Marmor MF, Weleber RG, et al. (2009) Retinal effects of 6 months of daily use of tadalafil or sildenafil. *Arch Ophthalmol* 127: 367-373.
9. French DD, Margo CE (2010) Central serous chorioretinopathy and phosphodiesterase-5 inhibitors: a case-control postmarketing surveillance study. *Retina* 30: 271-274.
10. Damar E, Toklu Y, Tuncel A, Balci M, Aslan Y, et al. (2013) Does therapeutic dose of sildenafil citrate treatment lead to central serous chorioretinopathy in patients with erectile dysfunction? *Am J Mens Health* 7: 439-443.
11. Eardley I, Cartledge J (2002) Tadalafil (Cialis) for men with erectile dysfunction. *Int J Clin Pract* 56: 300-304.
12. Oh JH, Oh J, Togloom A, Kim SW, Huh K (2014) Biometric characteristics of eyes with central serous chorioretinopathy. *Invest Ophthalmol Vis Sci* 55: 1502-1508.
13. Baltmr A, Lightman S, Tomkins-Netzer O (2014) Examining the choroid in ocular inflammation: a focus on enhanced depth imaging. *J Ophthalmol* 2014: 459136.