

## Can We Prevent the Post-Cholecystectomy Recurrent Pancreatitis?

Marco Basile<sup>1</sup>, Francesca Mazzarulli<sup>1</sup>, Giuseppe Di Martino<sup>2</sup>, Velia Di Resta<sup>2\*</sup> and Roberto Lattanzio<sup>3</sup>

<sup>1</sup>1st Division of General Surgery, Santo Spirito Civil Hospital, Pescara, Italy

<sup>2</sup>G.D Annunzio University of Chieti-Pescara, Chieti, Italy

<sup>3</sup>Department of Surgical Endoscopy, Popoli General Hospital, Pescara, Italy

\*Corresponding author: Velia Di Resta, G.D Annunzio University of Chieti-Pescara, Chieti, Italy, Tel: 00393297851705, E-mail: [velia.88@hotmail.it](mailto:velia.88@hotmail.it)

Rec date: Apr 4, 2014, Acc date: July 5, 2014, Pub date: July 7, 2014.

Copyright: © 2014 Basile, M, et al. This is an open-access article distributed under the terms of the Creative Commons Attribution License, which permits unrestricted use, distribution, and reproduction in any medium, provided the original author and source are credited.

### Abstract

Laparoscopic Cholecystectomy is an essential part of treatment of so called pancreatitis. It seems a necessary but not sufficient therapeutical act as demonstrated by the biliary still high incidence of post-cholecystectomy pancreatitis. There is no means of knowing which patient affected by biliary pancreatitis with no diagnosable abnormalities of the biliary main tract will develop a recurrent pancreatitis. This study supports the concept that by adding a "clearance" of the biliary tract at the cholecystectomy (so called rendezvous technique), a prevention of recurrent pancreatitis can be obtained. This observational study includes 39 hospitalized patients suffering from an acute biliary pancreatitis episode. None of them had serum bilirubin elevation or jaundice, and 27 had no instrumental evidence of bile duct obstruction while 12 had minor stones in the main bile duct. Rendezvous technique revealed undiagnosed bile duct abnormalities either functional or organic in 13 cases. During a 5 years follow-up period after the procedure no recurrent pancreatitis were observed. Our experience has shown that the technique of Rendezvous can reveal and treat obstructions of the bile duct that have not been diagnosed with instrumental examinations; furthermore, this technique seems to prevent the development of recurrent acute pancreatitis.

**Keywords:** Acute Pancreatitis; Cholecystectomy; Sphincterotome; Bile Duct

technique) in preventing recurrent pancreatitis in patient threatened for AP.

### Introduction

Laparoscopic Cholecystectomy is considered as an essential part of treatment of acute pancreatitis in cases labelled as affected by "acute biliary pancreatitis (ABP)" [1,2]. Appropriate timing of video laparoscopic cholecystectomy (VLC) is estimated to minimize the risk of recurrent pancreatitis [3] during the waiting time for operation. Nevertheless, the incidence of Recurrent Acute Pancreatitis after cholecystectomy still reaches high incidences (up to 17%) [4]. As recently demonstrated, it is very hard to differentiate during the hospitalization for a pancreatitis attack between patients destined to be cured by the simple cholecystectomy and patients bound to recur after the cholecystectomy. Even liver enzyme elevation [5] during the pancreatic attack surprisingly shows no correlation with future post-cholecystectomy recurrence [6]. Therefore there is no means to foresee which patient among those affected by biliary pancreatitis will need a bile duct clearance after the cholecystectomy. Known causes of recurrent ABP are choledocholithiasis, alteration of Wirsung duct, and papillary dysfunction [7] among those the only which can be easily diagnosed is choledocholithiasis, classically treated by ERCP either before, together, or after VLC. For the other two conditions, frequently encountered during ERCP, diagnosis is hard, and could at least partially explain the incidence of recurrent AP after VLC.

### Objectives

The aim of this work was to demonstrate the efficacy of simultaneous association of VLC and ERCP (so called Rendezvous

### Materials and Methods

This observational study included patients after one AP episode from January 2006 to December 2011 hospitalized in the Department of Surgical Endoscopy of popoli General Hospital, Pescara, Italy. The group consisted of 39 patients: 19 females (age 58,5 ± 3,5) and 20 males (age 63,5 ± 26,5). All patients were hospitalized after an episode of AP: all patients were first subjected to an ultrasound scan of the abdomen. In 11 patients was performed a CT of the abdomen with contrast, in 5 was performed MR cholangiography and 5 patients came from other Institute with instrumental examinations performed elsewhere. In all patients studied by instrumental tests was diagnosed mild acute pancreatitis, according to the classification criteria of Atlanta Classification [8]. The surprising thing is that only in 12 patients (30.8%), instrumental tests have shown the common bile duct stones, so 27 patients (69.2%) had no instrumental evidence of bile duct obstruction (Figure 1).

Even if there is not a certain guide on treatment for patients without clear signs of bile duct obstruction, we decided to submit all patients to VLC and simultaneous ERCP by the following method: patients were placed in the supine position on the operating table; after creating the pneumoperitoneum, accurate dissection of the Calot triangle was performed and the cystic duct was dissected. The cystic duct was proximally closed using a clip and it was cut to accommodate the cholangiography catheter. Intraoperative cholangiography (IOC) was then performed. A guide wire was introduced into the cystic duct via the IOC catheter and advanced through the sphincter of Oddi and into the duodenum. The endoscopic procedure was then started by

catching the guide wire by means of a polypectomy snare, and pulled through the working channel of the endoscope. A sphincterotome was introduced over the guide wire; the latter greatly facilitates cannulation of the bile duct. Retrograde cholangiography was done, and sphincterotomy was performed when the common bile duct was identified. Stones and debris were flushed out by injection of saline solution through the cholangi catheter. A retrieval balloon or stone retrieval basket was used to remove the retained stone (s). At the end of sphincterotomy, all stomach gas was carefully removed to facilitate VLC completion [8]. At the end of the endoscopic procedure the VLC was concluded.

This anomalies disappeared after the sphincterotomy (Figure 3), thus implying the presence of some kind of biliary obstacle different from stones.

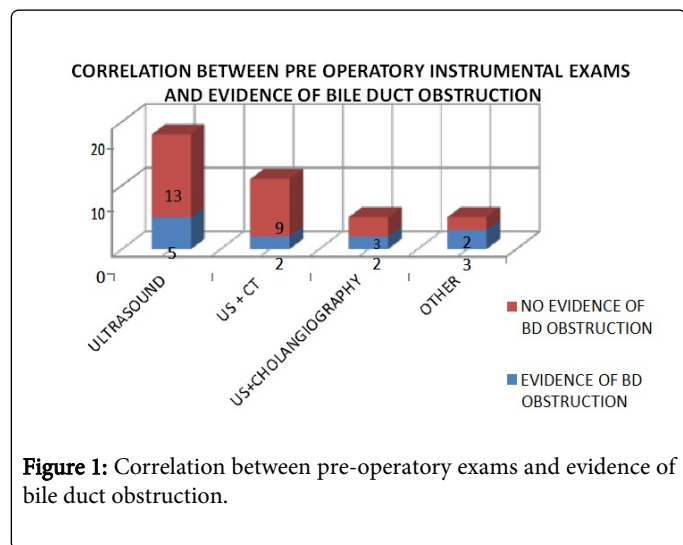


Figure 1: Correlation between pre-operative exams and evidence of bile duct obstruction.

Follow-up program else from direct clinical check within 1 month from discharge, was based on telephone interview. Patients were questioned about symptoms and/or sign of pancreatic origin and/or new admission to the hospital. Depending of the time of the operation the follow-up ranged from 12 to 60 months, average 42, and median 32. All patients were interviewed.

## Results

### VLC phase

In three cases the laparoscopic procedure was converted into open surgery: in one case a big hiatal hernia and partial pancreas necrosis were found; in one case severe adhesions from previous surgery forced to open surgery; in one case a pre-existing pancreatic abscess from pancreatitis was found and drained via open technique. In 2 cases a postoperative haemorrhage led to a second operation.

### ERCP phase

Performing the treatment we founded anomalies regarding papilla and bile duct in 13 patients (30%) that were not known in the instrumental exam. The anomalies of papilla (8 cases) represented an added difficulty during the treatment, forcing the surgeon to pre-cut the papilla.

In 2 cases the papilla was small, in 1 case it was hidden by a mucosal fold, in 3 cases it was located on a *perivaterian diverticulum*, in one case there was a flogosis of papillae, in one case the hole was hidden by mucosa. In 5 cases during the IOC we founded a dilatation of the pancreatic duct (Figure 2), in absence of any visible bile duct obstacles.

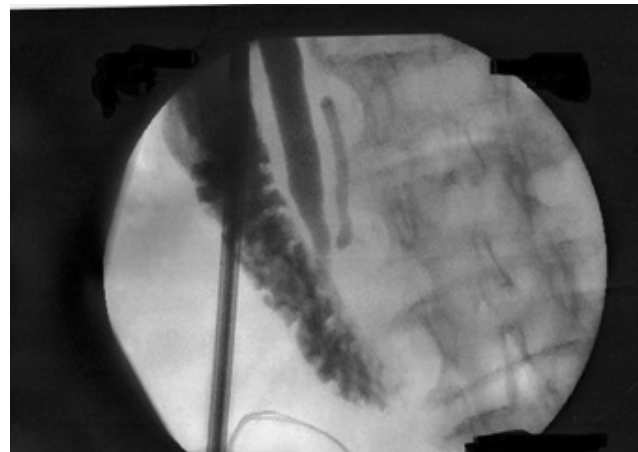


Figure 2: Dilatation of the bile duct (during the IOC).

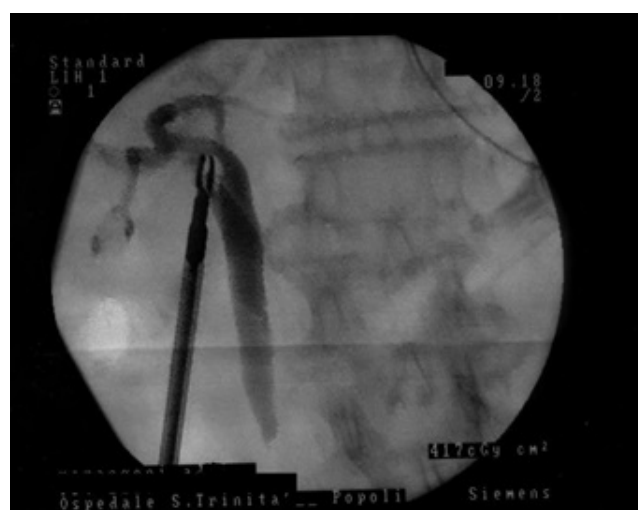

Figure 3: Anomalie disappeared after the IOC.

In 2 cases prothesis were applied due to an unsatisfactory clearance of bile ducts. We observed post-treatment pancreatitis in one case during the same hospitalization. The event occurred in the 8th postoperative day. Residual *bile duct lithiasis* was found and solved by a second ERCP.

In one case, symptoms of infected pancreatic pseudocyst with no evidence of acute pancreatitis appeared 47 days after the treatment and were confirmed by CT scan. The episode was solved by conservative treatment.

During the follow-up no episodes of recurrent pancreatitis were observed. In particular all the patients interviewed referred no hospitalization or recurrence of symptoms that can be referred to acute pancreatitis.

## Discussion

The so called "target cholecystectomy" represents an efficient option for the treatment of acute biliary pancreatitis whenever ABP gallstones are associated with bile duct stones, both VLC and ERCP are mandatory, although the timing and sequence of the two procedures are still debated [9]. When in cases of AP no detectable obstacle of the bile flux in the BD exists, treatment options are less straightforward. Target cholecystectomy can solve the gallstone problem, but there is no way of anticipating who will develop a postcholecystectomy ABP in the future. A relevant proportion (up to 17%) of patients treated with VLC for AP, will develop a recurrent AP. Cases of ABP without signs of biliary stasis are a clinical challenge. In fact as it is in the case of the majority of our study population (27/39 cases), in which the only sign of ABP is represented by the gallbladder lithiasis are not definitively cured by the cholecystectomy alone. In such cases clinical or instrumental evidence of bile duct obstruction is observed and the question of who will develop a post-cholecystectomy AP remains open. Even serum elevations of hepatocellular enzymes during the AP episode show no correlation with the possibility of a subsequent (post-surgical) AP episode [4]. On this ground is based our proposal to apply the rendezvous approach in all cases in which the diagnosis of ABP is certain, even if no signs of bile duct obstruction are present. It should be underlined that among the cases in which no bile duct obstruction was found preoperatively, the ERCP phase of the procedure unveiled biliary abnormalities in 13 cases, thus giving a reason for the AP episode. Another strong element in our opinion is the relatively safety of guided endoscopic sphincterotomy compared to blind ERCP [10]. The guide wire insertion via the cystic in the duodenum during the laparoscopic phase, allows the endoscopist to avoid the blind pailla cannulation and the consequent potential for complications. These advantages are confirmed in our experience, it looks like the adoption of rendezvous technique in all case of AP with no evidence of BD obstacle, shields the patients from the recurrence of pancreatitis, which is confirmed by some evidence in the literature [11]. In our experience there is no evidence of recurrent acute pancreatitis after rendezvous techniques, in disagreement with the literature that shows a significant number of recurrent pancreatitis (from 3 to 17%) in patients already treated for stones in the gallbladder. This incidence could partly be assigned to the possibility of a underdiagnosed residual main duct lithiasis or to abnormal biliary flux or to recurrent lithiasis, or all of them. The true mechanism of recurrent pancreatitis in cholecistomized patients is unclear and probably connected with all the above mentioned causes it is to be underlined however, that a one-time approaches to both the districts (gallbladder and main bile duct) holds a protective effect toward the possibility of a subsequent AP episode as demonstrated in our study. This could be an interesting clinical data, for the high mortality in patients with recurrent pancreatitis. As already discussed in the result session, the two cases that needed a reintervention in our group of patients are not to be considered as recurrence of pancreatitis: in the first case there was an incomplete BD clearance due to technical failure, so a second ERCP solved the matter. In the second case there

was no recurrent ABP but an infection of a residual pseudo cyst that was not diagnosed during the first laparoscopy.

## Conclusions

Our experience demonstrates that the Rendezvous technique can prevent the development of recurrent acute pancreatitis. Besides this technique is safer than simple ERCP and can avoid a second intervention on the same patients after a cholecystectomy and does not present specific contraindications. It is important to highlight that the technique of Rendezvous can show and treat obstructions of the bile duct that have not been diagnosed with instrumental examinations. By avoiding recurrent pancreatitis, this procedure can also produce substantial cost savings by avoiding rehospitalization and reintervention due to recurrent pancreatitis.

## References

1. De Rai P, Zerbi A, Castoldi L, Bassi C, Frulloni L, et al. (2010) Surgical management of acute pancreatitis in Italy: lessons from a prospective multicentre study. *HPB (Oxford)* 12: 597-604.
2. Alimoglu O, Ozkan OV, Sahin M, Akcakaya A, Eryilmaz R, et al. (2003) Timing of cholecystectomy for acute biliary pancreatitis: outcomes of cholecystectomy on first admission and after recurrent biliary pancreatitis. *World J Surg* 27: 256-259.
3. Ito K, Ito H, Whang EE (2008) Timing of cholecystectomy for biliary pancreatitis: do the data support current guidelines? *J Gastrointest Surg* 12: 2164-2170.
4. Trna J, Vege SS, Pribramska V, Chari ST, Kamath PS, et al. (2012) Lack of significant liver enzyme elevation and gallstones and/or sludge on ultrasound on day 1 of acute pancreatitis is associated with recurrence after cholecystectomy: a population-based study. *Surgery* 151: 199-205.
5. Pezzilli R, Zerbi A, Di Carlo V, Bassi C, Delle Fave GF (2010) Working Group of the Italian Association for the Study of the Pancreas on Acute Pancreatitis Practical guidelines for acute pancreatitis. *Pancreatology* 10: 523-535.
6. Jones HG, Jardine N, Williamson J, Puntis MC, Morris-Stiff GJ (2012) Patients with non-diagnostic hyperamylasaemia must be investigated and managed as per acute pancreatitis. *JRSM Short Rep* 3: 7.
7. Yadav D, Lowenfels AB (2006) Trends in the epidemiology of the first attack of acute pancreatitis: a systematic review. *Pancreas* 33: 323-330.
8. Bollen TL, van Santvoort HC, Besselink MG, van Leeuwen MS, Horvath KD, et al. (2008) The Atlanta Classification of acute pancreatitis revisited. *Br J Surg* 95: 6-21.
9. Erwin-jan M, Van Geenen, Chris J.J. Mulder, Donald L, Van Der Peet, Paul Fockens & Marco J. Bruno. Endoscopic treatment of acute biliary pancreatitis: A national survey among Dutch gastroenterologists.
10. Tekin A, Ogetman Z, Altunel E (2008) Laparoendoscopic "rendezvous" versus laparoscopic antegrade sphincterotomy for choledocholithiasis. *Surgery* 144: 442-447.
11. Morino M, Baracchi F, Miglietta C, Furlan N, Ragona R, Garbarini A. (2006) Preoperative endoscopic sphincterotomy versus laparoendoscopic rendezvous in patients with gallbladder and bile duct stones. *Annals of Surgery* 244: 889-96.