

## Management of the Aging Nail

Eckart Haneke\*

Department of Dermatology, University of Berne, Switzerland

### Abstract

The nails have important functions such as being extremely versatile tools in daily life – they protect the tip of the digit and enhance the sensory capabilities of the finger tip. They are also of enormous aesthetic importance. Their real and assumed weaknesses are often embarrassing and motivate the patients to seek medical advice. However, whereas many nail diseases can now be effectively treated such common ailments that are particularly frequent in advanced age like brittle and fragile nails still resist most therapies.

**Keywords:** Nails; Aesthetic aspects; Nail diseases; Brittle nails; Habit tic; Nail aging

### Introduction

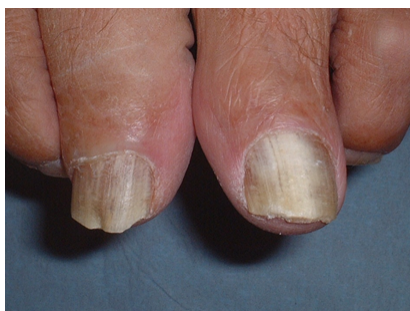The hands attract a lot of attention, probably next to the face and the female breast. They are difficult to hide during daily activities in contrast to the face that can be masked with a make-up, a veil, or a wide-brimmed hat. This has ignited recent interest in rejuvenation procedures for the hands, which all too often give information on the true age of an elderly person. The nails are an important part of attractive hands, and although they can be partially hidden by nail varnish many imperfections are still visible. Sometimes, colored nails even attract attention when the person does not want it. Unsightly, ungroomed, dirty nails impair the entire impression of a person. In addition to their aesthetic function, the nails are extremely versatile tools for scratching and defense, they enhance the dexterity of the fingers, protect the tip of the digits and increase the function of the digital tip as a sensory organ, which is said to be as important as vision.

The beauty of the nails is defined by their shape, size, shine, consistency, integrity of the periungual tissues and the entire distal phalanx (Figure 1).

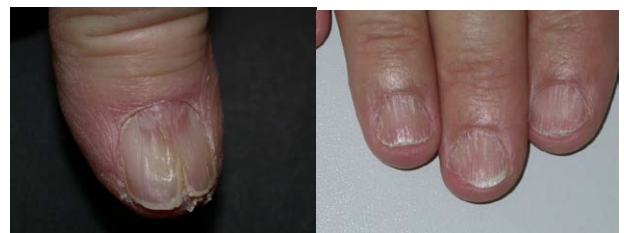The nail shape can be disbalanced when it is too wide, too narrow, too flat, curved too much or visibly deformed (Figures 2a, 2b, 3a and 3b).

### Brittle nails

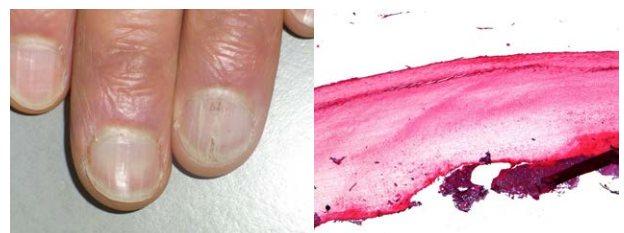Brittle and fragile nails are common in females, and the frequency of this condition increases with wet work and age. Nails may also be felt to be too soft or too hard. There is a plethora of different remedies offered in drugstores for the treatment of brittle nails, but the most important fact is to know the commonest cause, repeated maceration and dehydration. This is probably the reason why women complain 10



**Figure 1:** Lack of nail shine in a 67-year-old patient who was suspected to have onychomycosis. No fungal elements could be shown.



**Figure 2:** 2a. Severe onychorrhexis (longitudinal splitting) of the nail in an elderly woman. 2b. Ridging and surface splits in the nails of a 62-year-old man.



**Figure 3:** 3a. Lamellar splitting of the right ringfinger nail. 3b. The histological picture shows a split formation in the superficial nail plate layer.

times more often to have brittle nails than men; however, male chefs, other kitchen workers, butchers, fish-mongers etc. suffer less frequently from fragile nails than women with the same profession.

### Habit tics and psychopathological behaviours

It is often wrongly said that habit tics are a condition of the young. The periungual tissue, mainly the proximal and lateral nail folds, gives support to the nail plate. Lack of the lateral nail folds as is often seen after wedge excisions for ingrown nails frequently lead to misdirection of the growing nail with thickening, yellow discoloration and finally onycholysis and onychogryposis in the elderly. Many persons

\*Corresponding author: Dr. Eckart Haneke, Department of Dermatology, University of Berne, Freiburg Kaiser-Joseph-Straße 262 D-79098 Freiburg, Germany Tel: +49 761 8978368; Fax: +49-761-3837-400; E-mail: [haneke@gmx.net](mailto:haneke@gmx.net)

Received September 27, 2014; Accepted October 24, 2014; Published October 29, 2014

Citation: Haneke E (2014) Management of the Aging Nail. J Women's Health Care 3: 204. doi:10.4172/2167-0420.1000204

Copyright: © 2014 Haneke E. This is an open-access article distributed under the terms of the Creative Commons Attribution License, which permits unrestricted use, distribution, and reproduction in any medium, provided the original author and source are credited.

habitually push the proximal nail fold back in an attempt to make the nails appear more slender by giving them a longer appearance – which leads to loss of the cuticle, thickening of the free margin of the proximal nail fold, weakening of the attachment of the nail fold's ventral surface to the underlying nail plate thus creating a space under the nail fold where foreign substances may be trapped giving rise to a toxic or allergic dermatitis exacerbating the condition and leading to chronic or chronic relapsing paronychia.

Others press with the nail of the opposite thumb on the lunula region causing a median longitudinal depression with a rough, wash-board like surface, which is often misdiagnosed as Heller's median canaliform nail dystrophy. Still other subjects pick and tear the periungual skin; this habit – also called perionychotillomania – may be initiated by hangnails, but also causes them. It is a characteristic feature of these habit tics that the patients strongly reject this etiology [1].

Treatment is as simple as difficult: First, the patient has to be made aware of the mechanism of the damage to the periungual skin, second they have to be encouraged to quit this habit. As patients do often not agree with this pathomechanism a family member should be activated to help and make the patient aware whenever he or she does it. If they cannot stop their habit a trial with N-acetyl cysteine (NAC) can be made at a dose of 1200 to 1800 (to 2400) mg/d. NAC is widely known and used as a mucolytic drug and very well tolerated; it has no psychotropic action but influences the brain's glutamine metabolism helping to cope with obsessive-compulsive behavior [2]. When the patients manage to stop their habit the nail will slowly return to normal if the damage was not too harsh.

Onychophagia is another common habit, more often observed in children, but also not rare in adults. More serious onychodestructive habits are: onychotillomania – where the patients pull out all the nail (this may be an exaggerated form of perionychotillomania). Some cut all the nail down to the real beginning in the depth of the nail pocket, this is called onychotemnomania and may also be seen in the elderly. Onychoteiromania is when the patient rubs the finger nails until they virtually disappear; the bidet nail [3] may be seen as a variant of this phenomenon. Onychodaknomania is when the patient bites on single nails to gain a lustful pain; this is a psychopathologic behavior and requires psychiatric help [1].

When discussing the role of hormones, the physiology of the nails must be known. They exhibit a continuous non-cyclical growth in contrast to scalp hair. There is no androgen or estrogen hormone dependency and no alopecia-like nail loss nor greying – to the contrary, in darkly pigmented individuals the nails tend to become more pigmented with age.

### Nail discolorations

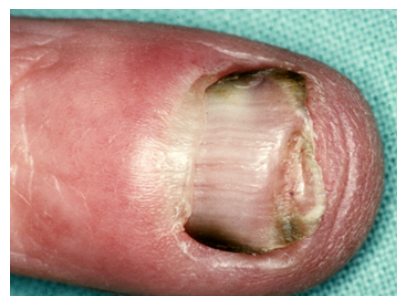Nail dyschromias are frequent. They always require first an exact diagnosis with identification of the nature of the pigment and its exact localization within the nail unit, which then allows an effective treatment to be instituted. Green nails are commonly due to *Pseudomonas aeruginosa*. Dirty grey nails are often caused by Enterobacteria. Yellow nails are seen in psoriasis, onychomycosis, nail thickening, retronychia and many other conditions leading to nail thickening. They are the leading sign of the yellow nail syndrome which may affect any age group but is more frequent in the second half of life. The triad of yellow, thick, extremely slow growing nails, lymphedema of the extremities plus a chronic infection of the respiratory tract are characteristic, but particularly in the elderly a search for a malignant tumor is indicated (Figure 4).

Brown nails require particular attention as this may be the sign of a nail melanoma. Human melanin is granular whereas most microbial melanins are soluble and cause a diffuse stain that appears yellowish to light brown in histological sections. Another reason for diffuse brown nail staining is potassium permanganate, which is still widely used for disinfective foot baths, and to povidone iodine (Figure 5).

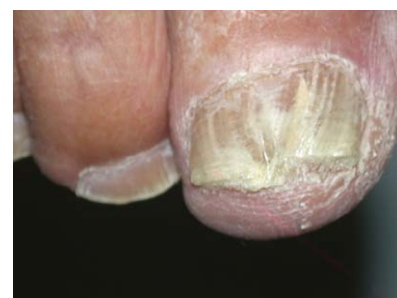Reddish-brown-black color may represent blood. It is easily distinguished from melanin as it forms small and large globules and accumulations. Dermatoscopy aids to diagnose this pigment (Figure 6).

Blood never reaches the free margin of the nail plate in contrast to melanin, which is incorporated into the nail substance and therefore appears as a longitudinal band reaching from the matrix into the distal margin of the nail (Figure 7).

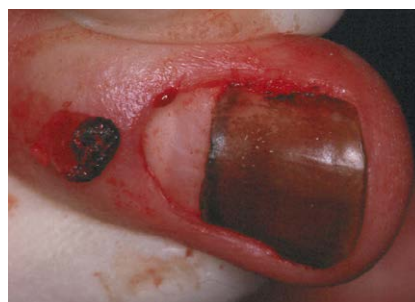Silver nitrate causes jet-black stains. Orange-brown nails were observed in Kawasaki syndrome and light red nails in *Serratia marcescens* infection. White color may occur as spots, lines or be



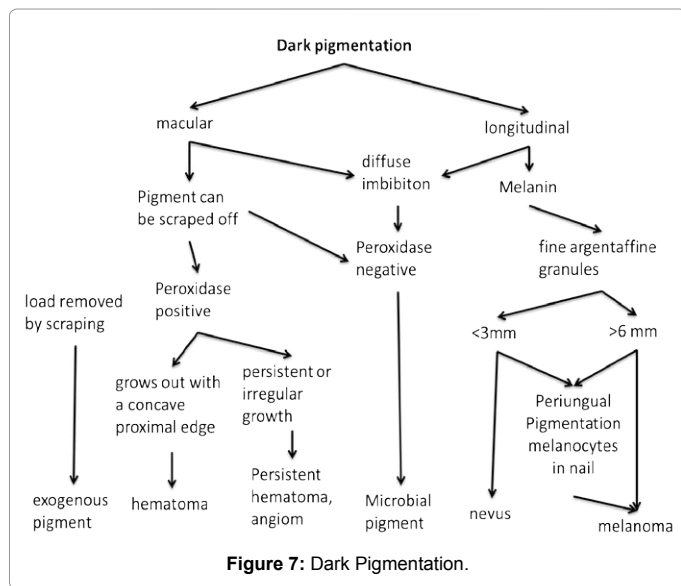
**Figure 4:** Greenish-black discoloration of the lateral margins of the nail in a 64-year-old housewife.



**Figure 5:** Thick yellowish nails of an 85-year-old man with onychomycosis.



**Figure 6:** Diffuse brown stain of the nail plate due to povidone-iodine.



diffuse. Small white spots are often seen in young girls, but may occur in anyone at any age (Figure 8).

A white transverse line parallel to the lunula border is a hint at a systemic event that has taken place some weeks before; it is analogous to Beau's lines and called Reil's sign who described it in 1798 in patients who had had a severe febrile illness. Repeated transverse white lines were also observed in women corresponding to their menstruation and in individuals receiving chemotherapy cycles (Figure 9). A longitudinal white streak is often due to a narrow subungual longitudinal hyperkeratosis as seen in subungual filamentous tumors and onychopapillomas, but sometimes also subungual seborrheic keratosis and Bowen's disease. A diffuse milky white color is seen in chronic liver disease. Some genetic defects also cause white nails. White superficial onychomycosis, in temperate climates mainly due to *Trichophyton mentagrophytes*, in the (sub) tropics due to a variety of mold fungi, represents fungal infections of the nail plate surface. In contrast, proximal white subungual onychomycosis exhibits fungal elements in the nail plate changing the optical properties of the nail (Figures 10, 11).

**Treatments to improve nails condition**

**Onychosupplements and onychocosmeceuticals:** The normal nail is relatively poor in essential elements. Most of those found in highly sensitive atomic spectrum investigations are found on the surface and derive from the environment. They have no known effect on nail growth and/or quality.

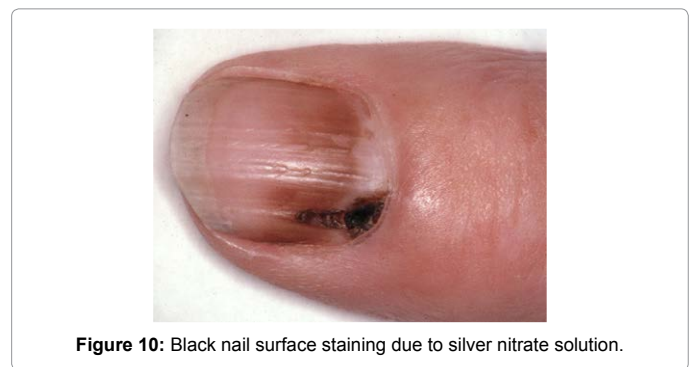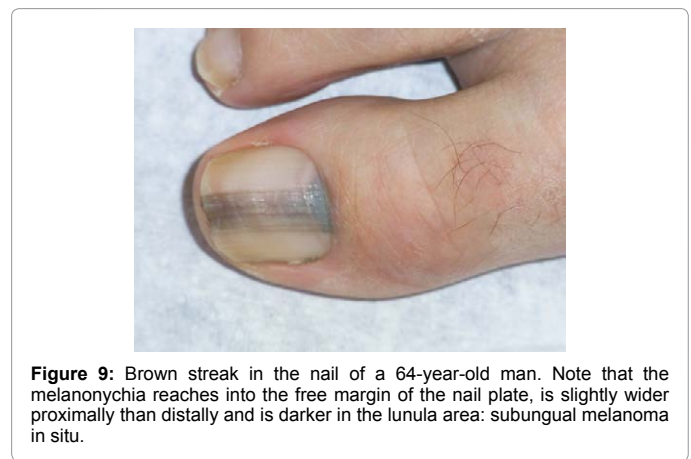
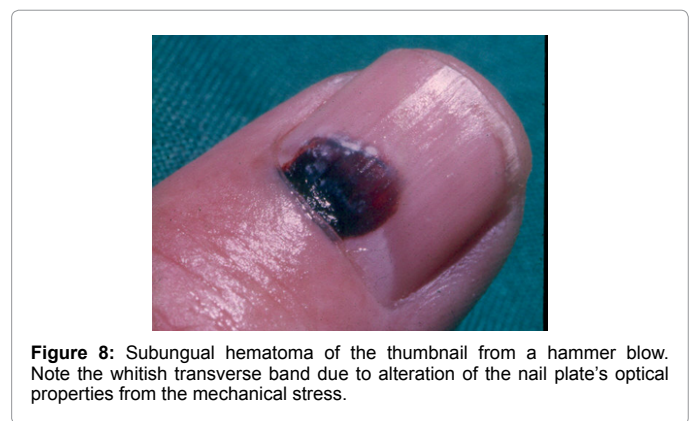Calcium, iron, and zinc are only present in very low concentrations in the nail. Iron deficiency is known to cause microcytic anemia and both brittle nails and koilonychia. High doses of iron in non-deficient persons are of no advantage. Although zinc deficiency impairs hair and nail growth and quality zinc substitution has no proven beneficial effect on the nails in non-deficient persons. In most studies, calcium application was disappointing although a study from Finland showed a positive effect on nail hardness.

The normal nail is poor in silicium. Traces of silicium are necessary for the maturation and differentiation of keratinocytes. This element is, however, one of the most abundant in nature and it is virtually impossible to suffer from silicium deficiency. There was no proof of a

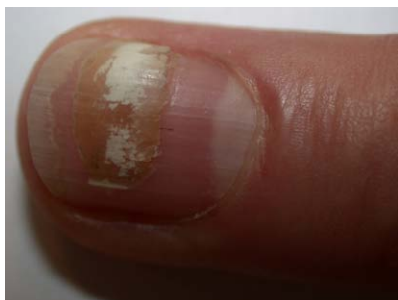positive effect in any controlled study. Further, varnishes containing silicium are applied on the already formed nail and have no effect on the nail formation.

Innumerable preparations are sold with promises "to help the body build up normal or better nails". Unfortunately, there are almost no facts, but lots of fictions and many unproven claims. Most are based on the assumption that when a defined deficiency disturbs normal nail formation the substitution of such substances would further increase the quality of the nails even without a proven deficit. It is, however, well known that this is not the case, neither for hair nor for nail problems.

A variety of substances may be called onychocosmeceuticals [4]: Biotin, vitamin A, vitamin E, gelatine, sulfur-containing amino acids, other sulfur-rich proteins, hormones, essential rare elements, calcium, iron, zinc, selenium, silicium, or urea.







**Figure 11:** Transverse leukonychia due to a crush injury in a 62-year-old man.

Biotin is often called the “hair and nail vitamin”. It was shown to improve the quality of horse hoofs, but there are very few sound studies in humans. The author’s own experience is very variable with some patients coming back with enthusiastic report of almost miraculous improvement of their nail quality within a very short time, but most taking the drug for months and years without apparent beneficial effect. One problem is the dose as it is not known whether the treatment is a substitution of the vitamin or if we need pharmacological doses [5].

Vitamin E is the classical lipid-soluble antioxidant. Some observations found it to be beneficial in the yellow nail syndrome. Due to the rarity of this condition, no controlled studies have been carried out until now. Perhaps, it is more effective when given together with a drug that increases the nail growth rate, such as itraconazole or fluconazole.

Vitamin A has no proven positive effect on nails. To the contrary, high dose vitamin A is onychodestructive as seen in patients who received megadoses for cancer treatment. Synthetic retinoids also do not improve the quality of the nails.

Fluor was said to be important for the hardness and resilience of nails. There is apparently a misunderstanding between nails and teeth. Normal nails have very little fluor and there is no study convincingly showing a positive effect of fluor on nail hardness.

Gelatin is said to improve the nail quality and growth. However, despite these claims there is no rationale for giving gelatin as it is made from dermis and bone and is poor in sulfur-containing amino acids.

Sulfur-rich compounds such as keratin fibers of nails and hair contain large amounts of sulfur, but their chemistry is genetically regulated. That is why application of cysteine, cystine, methionine etc is without proven benefit.

Other proteins whatever their origins have no proven benefit on the quality of the nails.

“Organic food” is another of the magic bullets recommended by ignorant self-proclaimed healers. Examining the poorest people from 4<sup>th</sup>-world countries shows that most of them have magnificent hair and nails. Thus it can be concluded that food has little influence. Even grotesque diets usually remain without consequences for the nails if not pursued for too long a period [6].

Why are all these remedies and procedures so disappointing? The nail is a plaque-like structure made up of keratin fibers, which are imbedded in a sulfur-rich amorphous matrix. The chemical structure of both of them is genetically defined. “Substitution” of sulfur has no influence on this genetically fixed structure unless there is a clear-

cut deficiency or a disease of sulfur metabolism. The slow growth rate of nails in certain deficiency states does not mean that uncritical “substitution” of these substances in non-deficient individuals would improve the quality and/or growth rate of the nails.

However, there are some measures that may, within narrow limits, increase the nail growth rate. Itraconazole in a dose of 400 mg/d or fluconazole ~150 mg/d were observed to speed up nail growth, which is particularly useful for the treatment of fungal nail infections. Physical activity, warm temperatures and possibly sun light also increase the nail growth rate whereas the nails grow slower at night, in cold weather or high altitude. Physical activity improves the nail quality, makes them harder as is seen in manual workers who have thicker and harder nails.

Diseased nails often have an irregular surface, they are fragile and brittle, may be malformed, too small or too big. When dealing with such nails the causative condition has to be treated first. Certain changes can be effectively camouflaged. Rough nails and pits due to lichen planus or psoriasis may become invisible when transparent or lightly colored nail varnish is used. Artificial nails when used rationally may also be beneficial [7].

### Surgical methods

Some traumatic nail damage can be repaired with reconstructive nail surgery.

The tip of the digit may deviate from the norm by being too short, too thick or too broad. One such example is the racket thumb, which a hereditary dominant trait is caused by premature ossification of the epiphysis of the distal phalanx of the thumb, rarely another finger or exceptionally a toe [8]. It starts being visible at the age of 12 to 15 years. Many aged persons consult us for their improvement. Treatment is surgical with bilateral longitudinal excisions. The first incision starts at the distal dorsal interphalangeal skin crease and is carried down to the bone through the proximal nail, the nail plate, matrix and bed till the hyponychium approximately 3 to 5 mm medial to the lateral nail margin, the second incision starts 1 mm lateral of the lateral nail margin again at the level of the distal interphalangeal joint and performed through the lateral nail sulcus along the lateral nail margin. This gives a 3 to 5 mm wide tissue block on each side narrowing the nail to restore a harmonious length-to-width ratio. It is important to slant the excision slightly laterally in its most proximal part in order not leave remnants of the lateral matrix horn behind.

The genetically programmed nail quality, physico-chemical properties, consistency, hardness, flexibility, and shine of the nails cannot be improved by surgical measures. Nail avulsion makes almost everything even worse. Lasers have no positive influence.

However, a beautiful nail with a harmonious shape balanced with the tip of the digit may be created in case of developmental or traumatic abnormalities. Intact periungual tissue, shiny and transparent nails, normal thickness and length are often impaired by habit tics (see above) and their treatment is necessary.

Young nails are elastic and transparent, not fragile, rapidly growing with normal thickness. Particularly toenails are often subject to trauma. When the big toenail was lost or avulsed or cut too short a false distal nail fold often develops that cannot be overgrown by the re-growing nail; since the matrix continues to produce nail substance this nail is getting thicker, yellowish and intransparent. Depending on the duration and degree of the distal nail fold redressing massage, consistent taping or even its surgical removal may be necessary.

## Conclusion

Everybody wants to have beautiful nails. Many embarrassing nail disorders can now be treated, however, some seemingly banal conditions are difficult to improve. In-depth knowledge of the biology, physiology and growth pattern of nails helps to treat unsightly nails and avoids useless but expensive therapies. The knowledge of self-inflicted nail alterations is essential as these are often the reason of ugly nails particularly in cosmetically over-concerned females.

## References

1. Haneke E (2013) Autoaggressive nail disorders. *Dermatol Rev Mex* 57:225-234 .
2. Berk M, Jeavons S, Dean OM, Dodd S, Moss K, et al. (2009) Nail-biting stuff? The effect of N-acetyl cysteine on nail-biting. *CNS Spectr* 14: 357-360.
3. Baran R, Moulin G (1999) The bidet nail: a French variant of the worn-down nail syndrome. *Br J Dermatol* 140: 377.
4. Haneke E (2006). Onychocosmeceuticals. *J Cosm Dermatol* 5:101-106
5. Haneke E (1994) [Biotin as a therapeutic nail and hair substance?]. *Med Monatsschr Pharm* 17: 187.
6. Haneke E, Baran R (2011) Micronutrients for hair and nails. In: Krutmann J, Humbert P (Eds.) *Nutrition for Healthy Skin*. Springer, Berlin-Heidelberg P: 149-163.
7. Jefferson J, Rich P (2012) Update on nail cosmetics. *Dermatol Ther* 25: 481-490.
8. Farster W , Haneke E (2000) clinic and pathogenesis des Racket - Nagel . *Z Ärsth up Dermatol* 2: 51-53.