

Treatment of Behçet's Disease with Subcutaneous Testosterone: A Case Report

Sonja Sokolovska^{1*}, Moira J Finlay², George A Varigos³ and Susan R Davis⁴

¹Scholarly Selective Research Student as part of the Doctor of Medicine at the University of Melbourne, Australia

²Anatomical Pathologist, Royal Melbourne Hospital, Australia

³Head of Dermatology Unit, Royal Melbourne Hospital, Grattan Street, Parkville, VIC 3050 Australia

⁴Women's Health Research Program, School of Public Health and Preventive Medicine, Monash University, Melbourne, Australia

*Corresponding author: Sonja Sokolovska, Scholarly Selective Research Student as part of the Doctor of Medicine at the University of Melbourne, Australia, Tel: 0423353696; E-mail: sonja.sokolovska@gmail.com

Received date: August 16, 2014, Accepted date: October 07, 2014, Published date: October 14, 2014

Copyright: © 2014, Sokolovska S, et al. This is an open-access article distributed under the terms of the Creative Commons Attribution License, which permits unrestricted use, distribution, and reproduction in any medium, provided the original author and source are credited.

Abstract

A 64 year old Caucasian lady living with Behçet's disease since 1984 presented with recurrent oral and genital ulceration refractory to colchicine, nicotinamide, and topical corticosteroids. The patient reported in the early years of her disease, that her ulcers worsened premenstrually and tended to heal around the middle of her menstrual cycle. She was commenced on testosterone therapy for the management of loss of libido, administered as a 50 mg subcutaneous implant (Organon, Netherlands) every 6 months, in combination with an estradiol patch releasing 75 mcg/day. Incidentally, the patient found marked improvement in the distribution and severity of her oral ulcers within weeks of the insertion of each testosterone implant, with concomitant resolution of all genital ulcers and a marked improvement in her overall quality of life. The treatment of Behçet's disease remains largely anecdotal at present. The use of subcutaneous testosterone implants could thus potentially serve as a safe and effective treatment option to improve oral and genital ulceration in females who suffer from this debilitating inflammatory condition. However, further investigation regarding the use of subcutaneous testosterone in the management of autoimmune diseases in women could be the subject of future research.

Keywords: Behçet's disease; Oral ulceration; Genital ulceration; Testosterone; Autoimmune diseases

Introduction

Behçet's disease is a rare, chronic inflammatory syndrome defined clinically by the presence of recurrent oral ulceration within a 12 month period, in addition to at least two secondary criteria consisting of genital ulceration, uveitis or retinal damage, skin lesions, and a positive pathergy test result. Vasculitic damage to arteries and veins may also be present on histopathologic examination. At present, therapeutic options for the treatment of Behçet's disease are limited to relieving symptomatology, and preventing associated complications, including secondary infection, gastrointestinal perforation and vascular aneurysms. Evidence favouring specific treatment modalities is largely anecdotal, with few randomised clinical trials and no treatment consensus.

Case Report

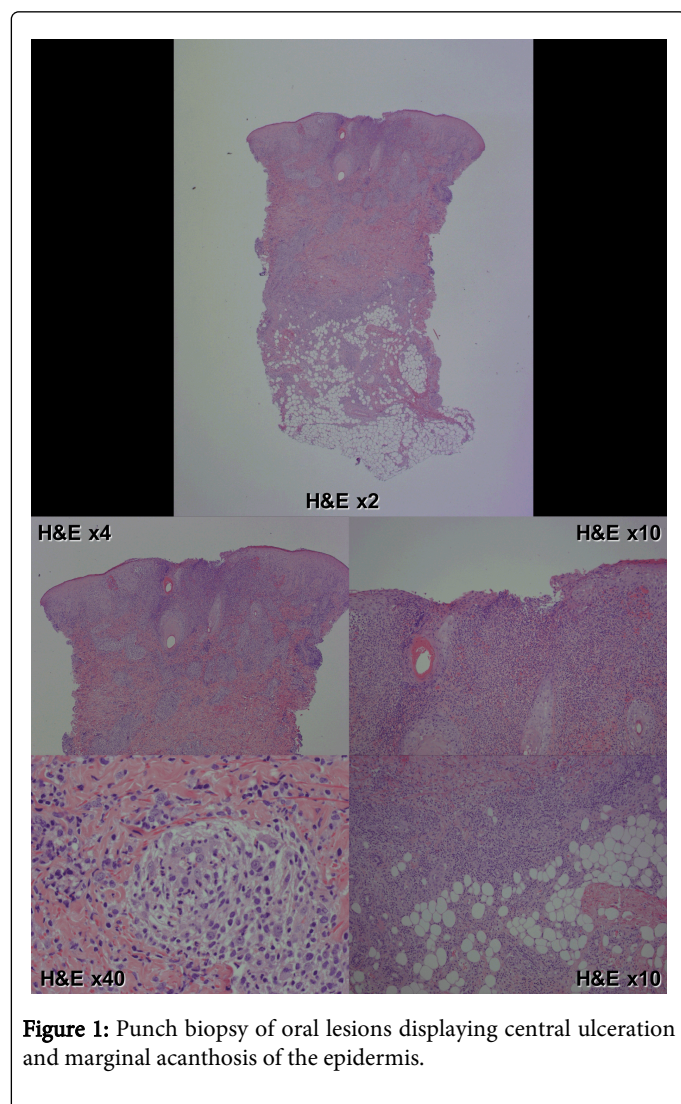
A 64 year old Caucasian lady living with Behçet's disease since 1984 presented with recurrent oral and genital ulceration refractory to colchicine, nicotinamide, and topical corticosteroids. Microscopically, a punch biopsy of her oral and genital lesions displayed central ulceration and marginal acanthosis of the epidermis. The ulceration was associated with a mixed inflammatory cell infiltrate in the dermis and fat, with numerous neutrophils, including neutrophils in the hair follicles and sweat glands. A small vessel vasculitis could also be seen, possibly occurring secondary to the erosion (Figure 1).

Together with these histopathologic findings, the patient's clinical history of pathergy and associated symptomatology was found to be most consistent with Behçet's disease. The patient also reported intense detriment to her overall quality of life, largely attributable to the presence of orogenital ulceration and subsequent secondary infection.

The patient reported in the early years of her disease, when she was first seen by SRD, that her ulcers worsened premenstrually and tended to heal around the middle of her menstrual cycle. She underwent a hysterectomy for prolapse in 1997, and was commenced on oral, and then transdermal estradiol. She was commenced on testosterone therapy for the management of loss of libido, administered as a 50 mg subcutaneous implant (Organon, Netherlands) every 6 months, in combination with an estradiol patch releasing 75 mcg/day [1]. Incidentally, the patient found marked improvement in the distribution and severity of her oral ulcers within weeks of the insertion of each testosterone implant, with concomitant resolution of all genital ulcers and a marked improvement in her overall quality of life. In early in 2009, when a different endocrinologist did not agree to continue her testosterone therapy, she experienced an exacerbation of her Behçet's with ulcers lasting several months. In October 2009 another 50 mg testosterone subcutaneous implant was inserted by her previous endocrinologist (SRD) and her ulcers healed over the next 3 weeks.

She then continued to have 6 monthly 50 mg testosterone implants in addition to nicotinamide and 500 mg of colchicine daily for several years. She had a rejection reaction to a testosterone pellet inserted in January 2014, and the implant expelled. This was followed by a severe flare of her oral and genital ulceration. Reinsertion of a testosterone

implant in May 2014 subsequently resulted in complete resolution of all the patient's ulcerated lesions within a two week period.



Discussion

To date, there have been no reports of the use of testosterone for the treatment of the symptoms of Behçet's disease, despite a range of immunomodulatory therapies being reviewed in prior literature.

Saleh et al. [2] reported that the etiology of Behçet's disease remains multifactorial, predominantly due to genetic susceptibility and infectious triggers in combination with immune dysregulation. The pathogenesis of Behçet's disease was investigated prior to this by Tursten [3], in which he highlighted the potential significance of testosterone in the activation of neutrophils with subsequent oxidative burst. It was noted that male patients with Behçet's disease manifested increased burst response before testosterone treatment compared with females.

Interestingly, Aksu et al. [4] reported two cases of Behçet's disease without neurological findings, but with erectile dysfunction. The authors argued that the erectile dysfunction of their patients was most likely attributable to venous leak, rather than neuro Behçet's disease,

given that the erectile dysfunction was adequately managed with deep dorsal vein ligation in response to the venous leak. Similar to our case report, both of these patients were on long duration colchicine for the management of oral and genital ulceration, and had no other iatrogenic or pathologic risk factors for peripheral neuropathy. There is a possibility that testosterone insufficiency may be either a cause or a manifestation of Behçet's disease in patients who present with oral and genital ulceration, and are managed with colchicine. Unfortunately, the case reports of Aksu et al. did not mention measurements of the patient's testosterone levels at time of presentation. Although there is a lack of clinical evidence and randomised clinical trials for the use of testosterone in Behçet's disease, there may be a potential therapeutic role of testosterone in the minimisation of apoptosis and ulceration, with resultant optimisation of quality of life.

The earliest use of testosterone in the treatment of orogenital apthae was reported by Misra and Anderson [5] in 1989, whereby a dramatic improvement in cyclical premenstrual orogenital apthuous ulceration was noted in a case of a 29 year old female. This markedly improved after each of the three monthly injections of 100 mg of subcutaneous testosterone she received. Although the patient in question was diagnosed with generalised orogenital apthae rather than Behçet's disease, there was no report of the histopathology such that it could be compared with our current case.

Within a separate review, Malkin et al. [6] advocate that androgens have been shown to suppress pro-inflammatory cytokine activity, inhibit apoptosis and enhance vascular smooth muscle cell proliferation with respect to the development of atherosclerotic plaques. Past research also suggests androgens suppress both cell-mediated and humeral immune responses, and it has been proposed that higher testosterone levels, as seen in men, may be protective against autoimmune disease [7-9].

The most recent analysis of treatment modalities pertaining to Behçet's disease by Saleh and colleagues [2] reviewed a series of randomized clinical trials from 1988-2010 inclusive, in which improvement in oral ulceration was noted with various systemic therapies including colchicine, etanercept, rebamipide, dapsone, thalidomide, and Interferon 2 α . Colchicine and thalidomide were found to result in clinical improvement of genital ulceration also. Evidence for the use of infliximab and etanercept in managing mucocutaneous involvement in Behçet's disease is limited to case reports, and would be anticipated to be less favourable within the clinical setting due to cost. The use of subcutaneous testosterone implants would thus potentially serve as a more economically preferable treatment regimen. However, further investigation regarding the use of subcutaneous testosterone in the management of autoimmune diseases in women could be the subject of future research.

References

1. Davis SR, McCloud P, Strauss BJ, Burger H (2008) Testosterone enhances estradiol's effects on postmenopausal bone density and sexuality. *Maturitas* 61: 17-26.
2. Saleh Z, Arayssi T (2014) Update on the therapy of Behcet disease. *Ther Adv Chronic Dis* 5: 112-134.
3. Tursten U (2012) Pathophysiology of the Behcet's Disease. *Pathology Research International* 2012: 493015.
4. Aksu K, Keser G, Gunaydin G, Ozbek SS, Colakoglu Z, et al. (2000) Erectile dysfunction in Behcet's disease without neurological involvement: two case reports. *Rheumatology* 39: 1429-1431.

-
5. Misra R, Anderson DC (1989) Treatment of recurrent premenstrual orogenital aphthae with implants of low doses of testosterone. *BMJ* 299: 834.
 6. Malkin CJ, Pugh PJ, Jones RD, Jones TH, Channer KS (2003) Testosterone as a protective factor against atherosclerosis--immunomodulation and influence upon plaque development and stability. *J Endocrinol* 178: 373-380.
 7. Cutolo M, Serio B, Sulli A, Accardo S (1995) Androgens in rheumatoid arthritis. In: Bijlsma JWJ (ed), *Rheumatology highlights 1995*. Eular Publ., Amsterdam, pp: 211-214.
 8. Masi AT, Feigenbaum SL, Chatterton RT (1995) Hormonal and pregnancy relationships to rheumatoid arthritis: convergent effects with immunologic and microvascular systems. *Semin Arthritis Rheum* 25: 1-27.
 9. Wilder RL (1996) Adrenal and gonadal steroid hormone deficiency in the pathogenesis of rheumatoid arthritis. *J Rheumatol Suppl* 44: 10-12.