

Penile Strangulation with Metallic Objects in Adults: 2 Case Reports and Literature Review

Choudhary SK^{1*}, Taraphdar T² and Thomas AJ³

¹The Mission Hospital, Durgapur, West Bengal, India

²Department of Accident and Emergency Medicine, The Mission Hospital, Durgapur, West Bengal, India

³The Mission Hospital, Durgapur, West Bengal, India

***Corresponding author:** Choudhary Dr. Sunil Kumar, MBBS, MEM (International), Head of the Department of Accident and Emergency Medicine, The Mission Hospital, Durgapur, West Bengal, India, E-mail: ayushimaurititus@yahoo.com

Received date: September 10, 2014, **Accepted date:** September 15, 2014, **Published date:** September 22, 2014

Copyright: © 2014 Choudhary SK, et al. This is an open-access article distributed under the terms of the Creative Commons Attribution License, which permits unrestricted use, distribution, and reproduction in any medium, provided the original author and source are credited.

ABSTRACT

Background: Penile strangulation by various metallic and non-metallic objects poses real challenge to the physicians in the Emergency Department. The removal of the offending objects requires imaginative mind, innovative thought process, improvised skill and resources often outside the department and even outside the hospital. Cases have been reported from across the globe and among various age groups ranging from adolescents to geriatric.

The underlying motive is usually autoerotic stimulation or sometimes psychiatric disturbances. The incarcerating injury results in reduced blood flow distal to the injury, leading to edema, ischemia, and sometimes gangrene. Unfortunately, patients often present late, when the damage has progressed quite far.

Two cases of penile strangulation by metallic objects that resulted in penile edema and were treated successfully are presented here.

A search was made for available papers and publication in English language for various methods of management of such cases using keywords "penile strangulation" on PUBMED and PMC database and 72 relevant articles were retrieved.

Objective: These cases present lessons to be learned for Accident and Emergency Department doctors in particular and even primary care physicians in general.

Conclusion: The cases should be approached and managed on an emergent basis in order to preserve normal function and prevent or minimize further complications.

Keywords: Penile strangulation; Autoerotic; Constricting devices; Vascular obstruction; Craft instruments

Introduction

Many Emergency Departments, receive cases of penile strangulation by different devices for sustained erection. The cause may range from psychological illness to Schizophrenia and Parkinsonism. The motive is, often, to obtain autoerotic satisfaction. It has been seen that the patients report to Emergency Departments after several hours of strangulation, when penile swelling increases out of proportion.

The removal of such devices in Emergency Departments under conscious sedation is a real challenge for Emergency physician. They often apply some novel idea to remove the devices or they seek Urology/orthopedic consultation.

There is no standard protocol for removal of such objects due to varied nature (metallic, plastic of different shapes and sizes) of the devices used.

Penile strangulation is an unusual clinical condition and the consequences can be severe. The commonest presentation is urinary obstruction. The delay in seeking medical help results in aggravation of complications, thus making the task more difficult for emergency physicians. Rare cases of death have also been reported. [1]

We report here 2 such cases which we had encountered in our department during 2010-12.

Case Reports

Case 1

A 55 year old patient presented to our Emergency Department with penile swelling, difficulty in micturation, and inability to stand or walk properly for last 22 hours, following insertion of a metallic hammer-head over penis for auto erotic purposes and thus resulting in strangulation as shown in figure 1.

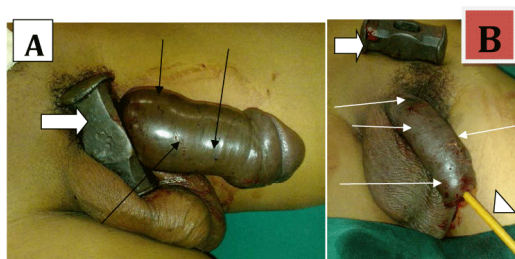


Figure 1: A. Metallic head of hammer at the base of penis (white thick arrow). The penile shaft is swollen. Multiple marks of needle prick [trial for decompression] seen on the shaft (thin black arrows). B. The metallic hammer head has been removed & kept aside (white thick arrow). The penile shaft is now decompressed. Multiple marks of needle prick seen on the shaft (thin white arrows). Foley's catheter is seen in situ (white arrowhead).

He was in severe pain, [pain score 9/10 on Visual Analog Scale] and not very co-operative. Trials for removal with lubricant anaesthetic jelly failed and needle decompression of corpora cavernosa resulted in bleeding.

He was taken to operating theatre and under general anaesthesia penis was decompressed after multiple punctures of corpora cavernosa and extracting of the edema fluid. The obstructing foreign body was removed thereafter.

This was a unique case, as a metallic object of such dimensions has rarely been previously reported in the literature we have reviewed.

Case 2

A 27 year old patient presented with history of insertion of a metallic curtain ring over the base of penis about 48 hours ago as shown in figure 2. He complained of penile pain and swelling and non-passage of urine for last 18 hours. Vitals were stable.

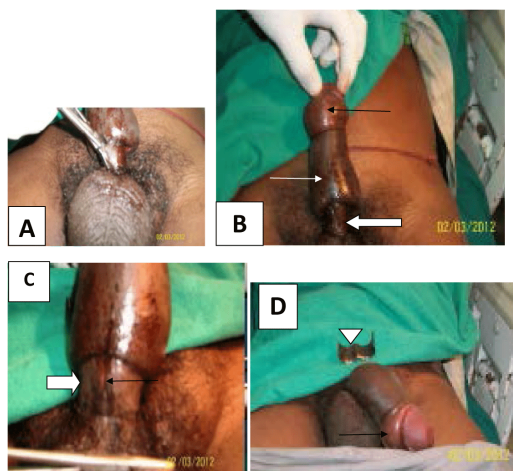


Figure 2: A metallic curtain ring at the base of penis

The ring being cut with metal cutter.

The ring has been removed. Indentation at the base of penis (white thick arrow), swollen penile shaft (white thin arrow), swollen prepuce with Paraphimosis (black thin arrow).

Enlarged view of B. Indentation at the base of penis (white thick arrow) and a midline thin cut injury (black thin arrow).

After removal of the ring: the cut ring has been set aside (white arrowhead), Paraphimosis yet to be relieved (black thin arrow).

1 inch long and 0.2 cm thick metallic ring was seen at the base of the penis. The penis was swollen, cold. No bleeding was noted per urethra. Lower abdomen was slightly distended. Paraphimosis was also seen. The metal ring was cut with metal cutting pliers, under Inj. Fentanyl [sedative analgesia].

The penis was decompressed with needle, and ice pack, Paraphimosis was corrected manually. After removal of the externally compressing metallic ring, per urethral oozing of blood was noted. Foley's catheterization was performed with clear urine output. Position of the catheter bulb was confirmed by ultrasonography. Color Doppler study suggested adequate vascular flow in the shaft of penis.

The patient was admitted under Urologist. The initial findings were: swollen penis with shallow, dark ulceration around the base. Clear flow of urine was noted. The patient was treated with IV antibiotics, analgesics, Proton Pump Inhibitors, daily magnesium sulfate dressing, fluid & electrolyte balance and other supportive care.

No rise in temperature was noted during his hospital stay. Urinary catheter was removed after 48 hours. There was no further hematuria. There was no difficulty in micturation, or burning sensation after removal of catheter. The penile swelling subsided within 48 hours. The patient was discharged in stable condition after 3 days of hospital stay.

During follow up at the Out Patient Department after 5 days, the patient complained of difficulty in erection and fibrosis of the shaft of penis was noted.

Literature Review

An online search was made for available literature in English in PUBMED and PubMed Central databases using keyword "penile strangulation". One hundred and three articles were found in PUBMED database, of which forty seven were of relevance. Two hundred and eighty-three articles were found listed in PMC, but only twelve were relevant, seven being common with PUBMED articles. The authors also searched for articles mentioned in references of these papers and were further able to obtain names of sixteen more articles of these. However three were not in PUBMED, only headlines were available for another six, and two abstracts were available. Further search in Google helped us to recover four full texts (one of whose abstract was available earlier) and two more headlines from their references.

Most articles were published in Urological journals, only four were published in any Emergency Medicine journal of repute.

The authors retrieved seventy two articles, of which we were able to get full texts of only twenty three articles, abstracts of another thirty nine articles and only headlines of ten articles.

Of these sixty four were case reports including six with literature review and two case series. Literature review and retrospective analysis made up the rest (1each).

The authors found 24 types of objects, both metallic and non-metallic in medical literature reviewed. Various types of metal rings were by far the most common metallic object used; being 33 out of 69 [47.82%] strangulating objects. Another 6 were metal nuts. The authors also came across 3 reports of hammer head being used as the strangulating object [1 report is from India in 1978] [2].

Age groups: Age of 45 patients were available, ranging from 7 years to 81 years, the age distribution shows maximum frequency in the age group 41 to 50 years.

The presenting symptoms and signs have been observed in 38 patients however it has been noted that pain, swelling, voiding difficulties and diminished sensation distal to obstruction appeared early. Necrosis could develop as early as 14 hours.

Psychological and neuropsychological problems were reported for 7 patients, 6 had been diagnosed either previously or during admission and 1 was diagnosed later. These are:-

Bipolar disorder 1, schizophrenia 1, psychotic depression 1, Parkinsonism 2 (1 of whom had drug overdoses), Meidcation induced hypersexuality 1, and sexual anxiety 1 (diagnosed later during hospital stay.)

Outcome of 34 patients were available. Death occurred in 1 case and 1 did not turn up for follow up. 27 patients had good recovery including those who had surgery.

Limitations

Our review was limited by paucity of full texts and we could not make any comparison among the various methods and procedures. There was also no uniformity in follow up of patients as these are mainly different case reports from different places and over a long period of time.

Discussion & Conclusion

The first case report of penile strangulation available was as early as 1755. [3,4] Dakin had reported the largest series in 1948 [4].

There has been an increase of penile gangrene incidents induced by penile strangulation resulting from either chronic use or acute obstruction by constricting devices for sexual stimulation purposes. [5]

The strangulating objects in pediatric and adult age groups differ considerably. While hair tourniquets are common offending agents in children, adults are often self-strangled by a variety of metallic and non-metallic objects. Adolescents as young as 13 years to geriatric cases as old as 81 years have been reported. [6,7] Children can also sustain such injuries out of curiosity [8].

Non-metallic, thin objects are easy to remove but can cause severe injury. Metallic objects are difficult to remove but the injuries are usually less severe. [9,10].

Consequences can be severe in cases of penile strangulation. It can lead to different degrees of vascular obstruction. Consequently, several clinical syndromes can occur: from mild non-significant vascular obstruction that resolves after decompression to severe gangrene of the penis accompanied with impaired renal function, [3] dry gangrene in diabetics and even auto-amputation. They can also lead to edema, maceration, and even local infections up to Fournier gangrene or penile necrosis with or without involvement of the urethra [11]. Late complications include penile shaft fibrosis and erectile dysfunction.

Death, though rare, has also been reported. In this case there was delay in seeking medical help which resulted in necrosis of penis, sepsis with multi organ involvement. The adult male had presented about 10 to 14 days after incarceration; autopsy findings were: penile strangulation, necrosis of penis, acute pyelonephritis, and bronchopneumonia [1].

Bhat Al et al. (1991) has graded such injuries in five types according to increasing severity as follows: [9]

Grade I: Edema of distal penis. No evidence of skin ulceration or urethral injury.

Grade II: Injury to skin and constriction of corpus spongiosum but no evidence of urethral injury. Distal penile edema with decreased penile sensation.

Grade III: Injury to skin and urethra but no urethral fistula. There is loss of distal penile sensation.

Grade IV: Complete division of corpus spongiosum leading to urethral fistula and constriction of corpus cavernosa with loss of distal penile sensation.

Grade V: Gangrene, necrosis, or complete amputation of distal penis.

Delayed presentations with incarceration, after 72 hours, are more likely to sustain higher-grade injuries than timely treatment [10]. Xu.T et al. (2009) have found a positive correlation between the time of incarceration and the length of hospitalization [12]. Again, Detweiler (2001) has shown, that the higher the grade of injury, the longer the time for removal and recovery, as well as a rise in the necessity of administration of anesthesia, either general or spinal [13].

Therefore emergent attention, prompt diagnosis and early treatment are essential to prevent penile necrosis and urethral injury and to avoid the potential complications of ischemic necrosis and auto-amputation, as well as to preserve erectile function [4,14].

The treatment consists, primarily, of an immediate decompression of the strangulated penis to ensure a free blood flow and an uninhibited micturition [11]. If the urethra is intact, a Foley catheter is recommended for Grades I and II, while suprapubic catheterization is recommended for Grades III-V. [4]

Penile decompression may be necessary before the offending foreign body is cut/ severed.

With rapid intervention and removal of the foreign body, most patients do extremely well and need no further intervention [10]. Removal of the constricting devices can become impossible secondary to a hefty swelling of the penis [3].

The methods may be either non-invasive or invasive. Treatment for penile incarceration can generally be divided into four groups: [4]

The string technique and its variants, with or without aspiration of blood from the glans;

Aspiration techniques;

Cutting devices; and

Surgery

Surgical techniques are reserved for the advanced grades (Grades IV and V) [4].

The authors also noted from the literature that:-

Lubrication, usually by anaesthetic jelly, is used to facilitate removal.

Removal of such devices can be challenging and often requires craft instruments, resourcefulness and a multidisciplinary approach [10,11]. The cutting process may be tedious with the possibility of iatrogenic penile injury [15]. Cutting instruments include various tools like ring cutters, bolt cutters, orthopedic saw and drills and even some improvised instruments. We have obtained:

4 instances of the use of “Dremel Moto-Tool”, the first being as early as 1982 by Greenspan L.

Angel / Angle cutters were used in 2 cases. In another case it was kept as stand-by.

4 instances of use of cutting instruments from fire department.

Orthopedic instruments were used in 11 cases, 9 of them were successful.

Dental drills were used in 3 cases.

These can be used alone or in combination. Conscious sedation may be needed in emergency department procedures, while more invasive procedures in operating theatre may require even general anesthesia.

The choice of methods for removal and strategies for extrication depend upon type of device used, size, incarceration time, trauma grade, the patient's ability to remain calm, and the tools available and accessible to the presenting physicians. [3,6] Sometimes, “it requires no particular skill but does require resourcefulness to perform the removal simply and effectively, and with as little discomfort for the patient as possible” [16]. In these situations these procedures might need resources not usually available in the hospital [17]. A hospital-based Emergency Medical Services and Rescue program is a valuable resource to provide the tools needed for management of penile strangulation [19].

Personal protective equipment (PPE) should be worn by all staff during the process of removal in order to prevent self-harm. These materials, varied in nature, have unpredictable property. Conjunctivitis from metal sparks injury in the operating physician has been reported [19,20].

The approach in the Emergency Department: The Emergency department approach should also focus on finding out any psychological involvement, sexual-psychological factors, as well as concomitant medical co morbidities and drug history; especially drug (dopaminergic) associated hyper sexuality. Pain management and tetanus prophylaxis should also receive adequate attention. Persistent priapism may also require urologist interventions. A supplementary therapy must be selected based on existing additional complications [1].

According to Gan et al. (2011) “In removing foreign objects around the penis, simpler methods should be given precedence over more complex ones, and for those that virtually defy cutting, the best option is degloving surgery with particular attention to the survival of the penile skin flap” [21].

The clinician should be aware of the various techniques to remove such devices. Innovative and novel methods are often required.

The authors therefore propose an attempt to standardize the treatment for which no protocol currently exists. This is represented in a flowchart (Figure 3):

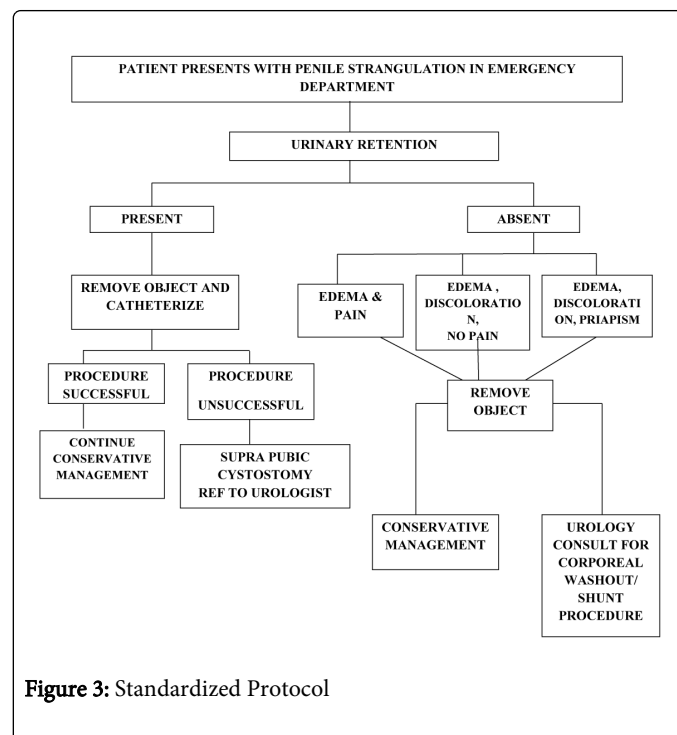


Figure 3: Standardized Protocol

References

1. Morentin B, Biritxinaga B, Crespo L (2011) [Section of Pathology, Forensic Pathology Service, Basque Institute of Legal Medicine, Bilbao, Bizkaia, Spain.], Penile strangulation: report of a fatal case. *The American Journal of Forensic Medicine and Pathology* 32: 344-6.
2. Punekar SV, Shroff PR, Vaze ML (1978) An unusual case of strangulation of penis by metal hammer head: (a case report). *J Postgrad Med* 24: 58-59, 59A.
3. Ivanovski O, Stankov O, Kuzmanoski M, Saidi S, Banev S, et al. (2007) [University Clinical Centre Skopje--Department of Surgery, Clinic of Urology, Skopje, Macedonia], Penile strangulation: two case reports and review of the literature. *The Journal of Sexual Medicine* 4: 1775-80.
4. Baruah SJ, Bagchi PK, Barua SK, Deka PM (2009) An innovative surgical technique for treating penile incarceration injury caused by heavy metallic ring. *Indian J Urol* 25: 267-268.
5. Labanaris AP, Zugor V, Smiszek R, Nutzel R, Kuhn R (2008) Dry gangrene of the penis induced by a bullring for sexual stimulation purposes., *The Scientific World Journal* 8: 896-900.
6. Raza K, Khadim MF, Naqvi GA, Ahmed I (2009) Wedding ring in the wrong place: an unusual presentation of penile incarceration in a child with a wedding ring. *BMJ Case Rep* 2009.
7. Okumura A, Tsuritani S, Muraishi Y, Sakamoto M, Kazama T, et al. (1993) [Strangulation of the penis by a metallic ring]. *Hinyokika Kiyo* 39: 1179-1181.
8. Halis F, Inci M, T Freier M, Gokce A., [Department of Urology, Korfez State Hospital, Kocaeli, TURKEY], Self-inflicted strangulation of prepuce in a child, *APSP Journal of Case Reports*. 2013 Jan; 4: 4.
9. Bhat AL, Kumar A, Mathur SC, Gangwal KC (1991) Penile strangulation. *Br J Urol* 68: 618-621.
10. Silberstein J, Grabowski J, Lakin C, Goldstein I (2008) Penile constriction devices: case report, review of the literature, and recommendations for extrication. *The Journal of Sexual Medicine* 5: 1747-57.

11. Nelius T1, Filleur S (2010) [Self-inflicted penile strangulation]. See comment in PubMed Commons below *Aktuelle Urol* 41: 64-66.
12. Xu T, Gu M, Wang H (2009) Emergency management of penile strangulation: a case report and review of the Chinese literature. *Emergency Medicine Journal* 26: 73-4.
13. Detweiler MB (2001) Penile incarceration with metal objects--a review of procedure choice based on penile trauma grade. *Scandinavian Journal of Urology and Nephrology* 35: 212-7.
14. Singh I, Joshi MK, Jaura MS (2010) Strangulation of penis by a ball bearing device. *The Journal of Sexual Medicine* 7: 3793-7.
15. Gan W, Yang R, Ji C, Lian H, Guo H (2012) Successful remove of a metal axletree causing penile strangulation in a 19-year-old male by degloving operation. *Case Reports in Medicine* 2012:532358.
16. Perabo FG, Steiner G, Albers P, Müller SC (2002) Treatment of penile strangulation caused by constricting devices. *Urology* 59: 137.
17. Sathesh-Kumar T, Hanna-Jumma S, De Zoysa N, Saleemi A (2009) Genitalia strangulation--fireman to the rescue! *Ann R Coll Surg Engl* 91: W15-16.
18. Lamba S, Patel NN, Scott SR (2012) Penile incarceration secondary to an S-shaped lead pipe: removal with dremel moto-tool. *The Journal of Emergency Medicine* 42: 659-61.
19. Horstmann M, Mattsson B, Padevit C, Gloyer M, Hotz T, et al. (2010) Successful removal of a 3.6-cm long metal band used as a penile constriction ring. *The Journal of Sexual Medicine* 2010 Nov;7(11): 3798-801.
20. Abogunrin FA (2012) Penoscrotal incarceration, four rings, and estate department bolt to the rescue. See comment in PubMed Commons below *Indian J Urol* 28: 213-215.
21. Gan WD, Guo HQ, Zeng LQ, Lian HB, Yao LF, et al. (2011) Treatment of penile strangulation and sexual psychological analysis of the patients. *Zhonghua Nan Ke Xue* 17: 535-7.