

## Transient OCT Highly Reflective Layer Following Macular Hole Surgery

Paul G Rainsbury<sup>1\*</sup>, Emily Gosse<sup>2</sup> and Jonathan Lochhead<sup>3</sup>

<sup>1</sup>Department of Ophthalmology, Queen Alexandra Hospital, Portsmouth, Hants UK

<sup>2</sup>Department of Ophthalmology, Nottingham University Hospitals, Nottingham, Notts, UK

<sup>3</sup>Department of Ophthalmology, St Mary's Hospital, Parkhurst Rd, Newport, Isle of Wight, UK

\*Corresponding author: Paul G Rainsbury MRCS, Department of Ophthalmology, Queen Alexandra Hospital, Portsmouth, Hants UK, Telephone: 0044 23 9228 6000; Fax 00441962712145; E-mail: [paul.rainsbury@nhs.net](mailto:paul.rainsbury@nhs.net)

Received date: Oct 08, 2014, Accepted date: Nov 26, 2014, Published date: Nov 29, 2014

Copyright: © 2014 Rainsbury PG, et al. This is an open-access article distributed under the terms of the Creative Commons Attribution License, which permits unrestricted use, distribution, and reproduction in any medium, provided the original author and source are credited.

### Abstract

**Objective:** Internal Limiting Membrane (ILM) peeling during macular hole surgery is commonly performed. In spite of this, little is known about the exact histological effect that this has on the retina post-operatively, due to a lack of clinicopathological studies.

OCT imaging is increasing our understanding of structural changes that occur after macular hole surgery, and is now widely used. Recently OCT observations have included Concentric Macular Dark Spots (CMDS) and Swelling of the Arcuate Nerve Fibre Layer (SANFL). In this paper a new postoperative OCT observation is described. This occurs transiently after macular hole surgery. The observation consists of a Highly Reflective Layer (HRL) on the retinal surface, and has been observed 1 month after surgery following gas disappearance.

**Methods:** A retrospective review of 26 consecutive cases of stage II-IV macular holes treated with 3 port pars plana vitrectomy, ILM peel and gas tamponade.

**Results:** HRL was found to be present in 31% of cases, and appears to be related to increased central retinal thickness pre-operatively and at 1 month postoperatively. HRL appears less likely in cases in which Triamcinolone Acetonide was used for assisted induction of posterior vitreous detachment, and more likely in combined phacoemulsification vitrectomy procedures. HRL did not appear to influence macular hole closure rates or visual acuity improvement.

**Conclusion:** The aetiology of this transient HRL on the surface of the retina is unclear, but it may represent a transient fibrinous process caused by the release of inflammatory mediators during ILM peeling.

**Keywords:** Membranes; Vitrectomy; Tomography, Optical coherence; Macular hole

### Introduction

Vitrectomy has become the established method for treating macular holes since it was first described by Kelly and Wendel in 1991 [1]. It is commonly combined with peeling of the Internal Limiting Membrane (ILM), which has been shown to significantly increase the closure rate and reduce the re-operation rate [2-4] especially in stage III and IV macular holes [5,6]. The ILM is a surface retinal basement membrane that originates from the underlying Müller cells, and is made up of collagen, laminin, glycosaminoglycans, and fibronectin [7]. Functionally it appears to provide additional strength to the retina [8].

The exact histopathological effect of ILM peeling has not been fully established, and our limited understanding is based on several single case studies of post mortem specimens. Peeling of the ILM in post mortem eyes without macular holes seems to produce damage to the end feet and processes of Müller cells in both the area peeled, and in the adjacent retina [9]. In eyes previously treated for macular holes with vitrectomy and ILM peel the structural defect induced by the ILM removal seems to be at least partly filled by glial cells [10,11].

Optical Coherence Tomography (OCT) has been established as an in vivo technique for studying structural changes in neurosensory retinal anatomy. It was first described for imaging macular holes by Puliafito et al. [12], and is now widely used to monitor recovery after macular hole surgery. With the advent of more sophisticated OCT imaging techniques, interest in the postoperative appearance of macular holes treated with ILM peeling has lately increased, and a number of signs visible on OCT at the level of the inner retina have been described. These have recently been classified by Pichi et al. into 'early' (occurring less than 15 days after surgery), and 'late' changes [13].

In this paper we would like to present examples of a previously unreported OCT observation recorded in a number of eyes shortly after routine macular hole surgery. The observation consists of a highly reflective layer on the retinal surface observed one month after surgery on cross sectional OCT scans. At this stage clear imaging of the macular region was possible without interference from the intraocular gas.

### Materials and Methods

A retrospective review of the OCT images of 26 consecutive cases of stage II-IV macular holes treated with vitrectomy and ILM peel over a

2 year period was performed. In 24 cases a 25-gauge system was used, and in 2 patients a 23-gauge system was preferred. A standard three port pars plana vitrectomy was carried out, and combined phacovitrectomy was performed in phakic patients in 20 out of 26 cases. The other 6 patients had previously undergone phacoemulsification. Triamcinolone Acetate (TA) was used in 17 cases. ILM peeling was then completed with 'Membrane blue dual' staining. In general, an area of approximately 2-3 disc diameters from the centre of the macular hole was peeled.

A Total FAX was performed, and all eyes were filled with 18% C3F8, with the exception of one eye where 25% SF6 was used. With a sutureless technique there is occasional venting of gas leading to underfill. If macular tamponade was thought to be inadequate in the upright position (<70% fill) then 3 days of posturing was recommended. All patients underwent a comprehensive preoperative and postoperative assessment including visual acuity, dilated fundal examination and OCT imaging. No patients were excluded from this consecutive cohort.

All OCT images were reviewed independently by three Ophthalmologists. Reviewers confirmed the presence of an HRL if the following three criteria were present; a highly reflective layer seen in the macular area where the ILM peel had been performed, flattening of the retinal surface in this region and resolution of these two changes on subsequent scans. The OCT scans from the pre-operative period were reviewed, in addition to images taken at approximately 1 month (mean of 42 days, range 15-54 days) and 4 months (mean of 136 days, range 64-239 days). Later scans were analyzed if the HRL seemed to be persistent. Images were taken on a Topcon 3D spectral domain machine.

Retinal thickness was measured across five areas of the peel. In addition to the Central Retinal Thickness (CRT) measured in the perifoveal region, four peripheral retinal thickness measurements within the macular arcades were taken superiorly, inferiorly, nasally and temporally. The average of these four more peripheral macular readings was calculated to provide a measure of the Peripheral Retinal Thickness (PRT) pre- and post-operatively. Visual acuity was measured using a standard Snellen chart, and converted into LogMAR units for the purpose of analysis.

Statistical analysis was performed on all results using Minitab version 16 software. Statistical methods included T-test and Mann-Whitney non parametric analysis. A cut off p value of  $\leq 0.05$  was used to demonstrate statistical significance.

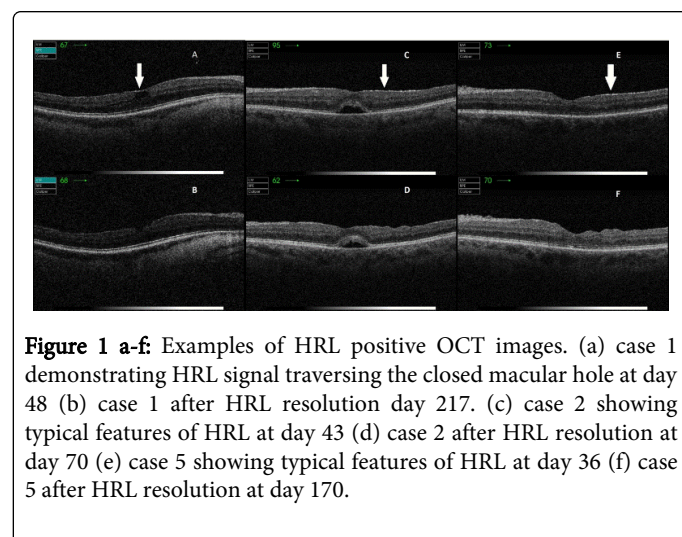
## Results

Twenty six consecutive cases of full thickness macular hole treated with vitrectomy, ILM peel and gas tamponade were reviewed. An HRL was confirmed in eight cases (31%). There was no statistical difference found in the size of the macular hole between those HRL positive cases (mean 351  $\mu\text{m}$  range 53-494  $\mu\text{m}$ ) and those HRL negative cases. (mean 305  $\mu\text{m}$ , range 10-566  $\mu\text{m}$ ) Anatomical closure was achieved in all patients post-operatively. Demographic data for the patients with and without an HRL are shown in Table 1.

Patient characteristics of individuals demonstrating the HRL are shown in Table 2, and typical OCT findings demonstrating the HRL are shown in Figure 1.

	HRL* (n=8)	positive	HRL (n=18)	negative	p-value
Age (years)	68.5		76.9		<0.01
Sex (Male/Female)	3/5		5/13		0.66
Eye (OD/OS)	2/6		11/7		0.09
Mean minimal macular hole size ( $\mu\text{m}$ )	351 (range 55-494)		305 (range 10-566)		0.49
Triamcinolone induced PVD	37.5% (n=3)		77.8% (n = 14)		<0.05
Combined phaco-vitrectomy	100%		66.7%		<0.01

**Table 1:** Patient demographic data



**Figure 1 a-f:** Examples of HRL positive OCT images. (a) case 1 demonstrating HRL signal traversing the closed macular hole at day 48 (b) case 1 after HRL resolution day 217. (c) case 2 showing typical features of HRL at day 43 (d) case 2 after HRL resolution at day 70 (e) case 5 showing typical features of HRL at day 36 (f) case 5 after HRL resolution at day 170.

Case	Age	Pre-op (LogMAR)	VA (LogMAR)	Final Post-op VA (LogMAR)	Mean Minimal Macular Hole Size ( $\mu\text{m}$ )
1	70	0.48		0.18	55
2	75	0.48		0.3	294
3	64	0.18		0.18	286
4	68	0.6		0	429
5	72	1.0		0.18	570
6	69	0.78		0	391
7	67	0.6		0.18	494
8	63	0.78		0.3	294

**Table 2:** Patient characteristics in HRL positive cases.

Mean pre-operative visual acuity was logMAR 0.61 in HRL positive patients and logMAR 0.68 in HRL negative patients ( $p=0.51$ ). Mean final post-operative visual acuity at  $\geq 4$  months was logMAR 0.17 (range 0.0-0.3) in HRL positive cases and logMAR 0.39 (range -0.8-1.4) in HRL negative cases ( $p=0.02$ ).

In the HRL negative group 1 patient developed wet AMD postoperatively, achieving a final visual acuity of logMAR 1.4. Excluding this patient from the analysis gave a mean final post-operative visual acuity at  $\geq 4$  months of logMAR 0.33 in the HRL negative group ( $p=0.03$ ).

However, the mean gain in visual acuity was logMAR 0.45 in HRL positive cases and logMAR 0.29 in HRL negative cases. This difference was not statistically significant ( $p=0.30$ ).

Statistical analysis of the retinal thickness measurements was possible in all 26 patients. For CRT we found a highly statistically significant relationship between positive HRL and postoperative retinal thickness at 1 month ( $p<0.01$ ). We also found this relationship to be statistically significant when comparing preoperative CRT with the HRL positive and negative groups. ( $p=0.02$ ). However at 4 months there was no statistical difference between the two groups in relation to CRT ( $p=0.12$ ). The findings for PRT showed a similar trend.

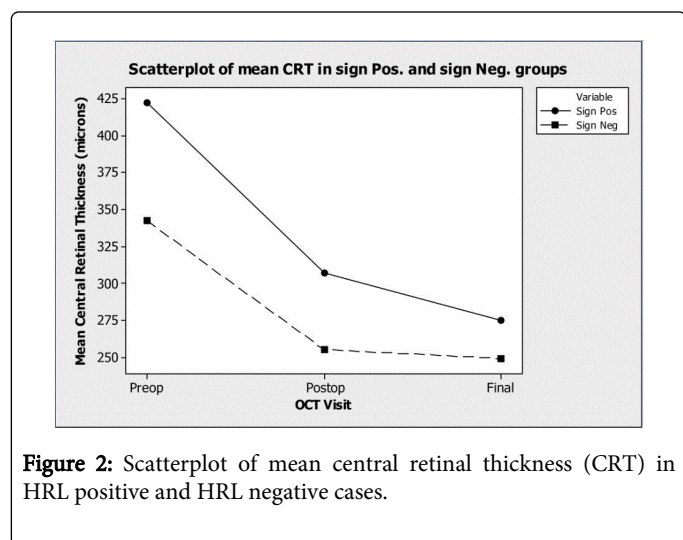


Figure 2: Scatterplot of mean central retinal thickness (CRT) in HRL positive and HRL negative cases.

	HRL* positive (n=8)	HRL negative (n=18)	p-value
Pre-operative CRT† (µm)	422	342	<0.05
Post-operative CRT at 1 month (µm)	307	255	<0.01
Post-operative CRT at 4 months (µm)	275	249	0.12
Pre-operative PRT‡ (µm)	379	320	<0.05
Post-operative PRT at 1 month (µm)	316	290	<0.01
Post-operative PRT at 4 months (µm)	303	292	0.29
Mean gain in visual acuity (logMAR)	0.45	0.29	0.30

\*Highly Reflective Layer, †Central Retinal Thickness, ‡Peripheral Retinal Thickness

Table 3: Peripheral retinal thickness (PRT), Central retinal thickness (CRT) and visual outcomes in cases with and without an HRL.

These results are illustrated in Table 3. CRT also demonstrated a consistent reduction in value during the postoperative period as demonstrated in Figure 2. Similar results were found for PRT. Linear regression analysis on the CRT data confirmed statistical significance with a regression coefficient of  $R^2=0.592$  for this change in the HRL positive group over time.

## Discussion

The advent of OCT imaging, especially when used postoperatively, has given the opportunity to study the healing process after macular hole surgery in a way that was previously very difficult. It is now recognized that glial bridging across the defect is one of the first steps involved in macular hole closure [14].

However despite these technological advances, the role of ILM peeling on macular hole closure has not been definitively established through OCT studies. ILM peeling may work by removing existing glial cells which could exert tangential forces if left behind. Removal of these glial cells may also stimulate the additional gliosis necessary for macular hole closure by glial bridge formation.

In this study we observed an HRL on OCT imaging in the area of ILM peeling at 1 month follow up. The HRL appears to be visible after macular hole closure, and had disappeared by a mean of 164 days. As far as we are aware, this is the first time that such a sign has been reported. The HRL is currently only an OCT finding, which has been detected transiently. It is possible that our observations are affected by the presence of gas in the immediate postoperative period, as although the macular region was not covered at this stage, some gas was still present within the eye.

The aetiology and effect of this HRL on macular hole closure post-operatively is unclear. Other retinal surface changes such as epiretinal membranes (ERM) may influence surface retinal architecture and cause the formation of pseudoholes [15]. Additionally, other authors have commented that the contracture of epiretinal membranes may be able to influence the closure of full thickness macular holes [16]. It is therefore not inconceivable that the HRL may also exert such an effect, and possibly play a role in macular hole closure. The HRL shares some characteristics found in epiretinal membranes (ERM) such as uniform flattening of the retinal surface. In contrast to ERM however, these features are transient, and disappeared or significantly reduced in appearance over an 8 month period.

In one case, the HRL signal was observed to cross the closed macular hole (Figure 1a), suggesting that this sign could represent a transient fibrinous membrane. When the HRL is present the retinal surface appears taught and straight. This finding later disappears and is replaced by Dissociated Optic Nerve Fibre Layer (DONFL), which appears on OCT as multiple small depressions in the contour of the retina, previously described as having a 'moth eaten' appearance, with multiple dark striae running in the same direction as optic nerve fibres in the region of ILM peeling [17]. The term Concentric Macular Dark Spots (CMDS) has been proposed to refer to this appearance using the enface OCT technique. This finding has been reported to occur in 43-100% of patients postoperatively [17,18]. We found that this sign was present in varying degrees in all 26 patients' OCTs postoperatively, whether or not an HRL was present.

It may be the case that ILM peeling induces a localised pro-inflammatory effect on the retina which could in turn influence macular hole closure. It is possible that the HRL seen on OCT imaging

represents such an effect and could be caused by the release of plasmin and other pro-inflammatory mediators from microscopic cell damage resulting from the peeling process. This could explain why the HRL appearance seems to be associated with increased retinal thickness, both pre-operatively, and in the first few months postoperatively compared to the group without recorded HRL. Increased pre-operative thickening was more often associated with cystoid inflammatory changes around the FTMH which may then subsequently increase the risk of post-operative inflammatory thickening. With successive post-operative visits these thickness measurements converged between the two groups (Figure 3) suggesting that this was not just a difference in baseline anatomical characteristics between the groups. This theory would also be supported by the finding that an HRL was seen more commonly in those eyes where intravitreal triamcinolone was not used to induce a PVD. Additionally it was more common in those patients undergoing vitrectomy combined with phacoemulsification, where more inflammation might be expected. We are aware that some of our baseline differences in data such as the use of TA and combined surgery may have influenced statistical analysis with regards to CRT measurements, however with the small numbers of patients analysed, correction for these variables would not have been valid. Further larger studies on this topic may help to clarify this matter.

Transient OCT changes have been previously reported elsewhere. Clark et al. described a process, following ILM peeling, that they called swelling of the arcuate nerve fibre layer (SANFL) [19]. They found that 31% of the cases that they reviewed postoperatively developed dark striae on infrared and auto fluorescence photographs originating from the optic nerve head, radiating in an arcuate pattern toward the macula. This was visible on OCT imaging postoperatively as swelling of the inner retinal layers and resolved after a mean period of 2 months. This SANFL is in a parafoveal anatomical region, with the documented swelling only described in the areas of striation seen on autofluorescence. Our observations are focused more on the fovea and peri-fovea. Examination of green filter infrared images of our patients with HRL did not reveal any characteristic striae of SANFL, nor did we observe the high signal change originating from the optic disc.

We have detailed statistical analysis of CRT measurements which have not been published before, and while it is possible that SANFL may also be associated with an increased CRT, we are confident that an HRL has not previously been described. It is interesting to note that both SANFL and HRL have a similar estimated incidence. It is possible that both these two series describe different aspects of the same spectrum of postoperative OCT changes which follow each other in succession. Since SANFL has been described during the first postoperative month [19], it might be supposed that HRL follows SANFL before the appearance of DONFL/CMDS on monochromatic fundus images or OCT scans.

In conclusion, HRL may represent a dynamic process during macular hole healing postoperatively. The patients found to have this sign all achieved a good anatomical and functional outcome. Analysis of our results suggests that the presence of an HRL is more apparent in patients with greater preoperative retinal thickening and cystoid macular oedema. This relationship continues to be significant in the immediate postoperative period. Patients receiving TA as an intraoperative tool are less likely to have a visible HRL postoperatively.

The clinical importance of HRL is yet to be established. In our series we compared the change in visual acuity in patients with and without an HRL, and found no statistically significant difference between the

two groups. There was also no difference in macular hole size or closure rate between the two groups.

Additional larger prospective studies may be useful in defining this clinical entity in more detail, and establishing further the origins of the HRL in post-operative macular hole OCT studies.

#### Conflict of Interest Statement

The authors declare no conflict of interest. The data has been presented at the British and Eira Association of Vitreoretinal Surgeons annual conference in 2013.

#### References

1. Kelly NE, Wendel RT (1991) Vitreous surgery for idiopathic macular holes. Results of a pilot study. *Arch Ophthalmol* 109: 654-659.
2. Kwok AK, Lai TY, Wong VW (2005) Idiopathic macular hole surgery in Chinese patients: a randomised study to compare indocyanine green-assisted internal limiting membrane peeling with no internal limiting membrane peeling. *Hong Kong Med J* 11: 259-266.
3. Christensen UC, Krøyer K, Sander B, Larsen M, Henning V, et al. (2009) Value of internal limiting membrane peeling in surgery for idiopathic macular hole stage 2 and 3: a randomised clinical trial. *Br J Ophthalmol* 93: 1005-1015.
4. Lois N, Burr J, Norrie J, Vale L, Cook J, et al. (2011) Internal limiting membrane peeling versus no peeling for idiopathic full-thickness macular hole: a pragmatic randomized controlled trial. *Invest Ophthalmol Vis Sci* 52: 1586-1592.
5. Johnson RN, Gass JD (1988) Idiopathic macular holes. Observations, stages of formation, and implications for surgical intervention. *Ophthalmology* 95: 917-924.
6. Gass JD (1988) Idiopathic senile macular hole. Its early stages and pathogenesis. *Arch Ophthalmol* 106: 629-639.
7. Hart WM (1992) Adler's physiology of the eye. Mosby-Year Book, Baltimore.
8. Wollensak G, Spoerl E, Grosse G, Wirbelauer C (2006) Biomechanical significance of the human internal limiting lamina. *Retina* 26: 965-968.
9. Wolf S, Schnurbusch U, Wiedemann P, Grosche J, Reichenbach A, et al. (2004) Peeling of the basal membrane in the human retina: ultrastructural effects. *Ophthalmology* 111: 238-243.
10. Madreperla SA, Geiger GL, Funata M, de la Cruz Z, Green WR (1994) Clinicopathologic correlation of a macular hole treated by cortical vitreous peeling and gas tamponade. *Ophthalmology* 101: 682-686.
11. Funata M, Wendel RT, de la Cruz Z, Green WR (1992) Clinicopathologic study of bilateral macular holes treated with pars plana vitrectomy and gas tamponade. *Retina* 12: 289-298.
12. Puliafito CA, Hee MR, Lin CP, Reichel E, Schuman JS, et al. (1995) Imaging of macular diseases with optical coherence tomography. *Ophthalmology* 102: 217-229.
13. Pichi F, Lembo A, Morara M, Veronese C, Alkabes M, et al. (2014) Early and late inner retinal changes after inner limiting membrane peeling. *Int Ophthalmol* 34: 437-446.
14. Michalewska Z, Michalewski J, Nawrocki J (2010) Continuous changes in macular morphology after macular hole closure visualized with spectral optical coherence tomography. *Graefes Arch Clin Exp Ophthalmol* 248: 1249-1255.
15. Steel DH, Lotery AJ (2013) Idiopathic vitreomacular traction and macular hole: a comprehensive review of pathophysiology, diagnosis, and treatment. *Eye (Lond)* 27 Suppl 1: S1-21.
16. Smiddy WE (2008) Spontaneous macular hole closure with appearance of epiretinal membrane: implications for therapy. *Ophthalmic Surg Lasers Imaging* 39: 237-238.
17. Tadayoni R, Paques M, Massin P, Mouki-Benani S, Mikol J, et al. (2001) Dissociated optic nerve fibre layer appearance of the fundus after

- 
- idiopathic epiretinal membrane removal. *Ophthalmology* 108: 2279–2283.
18. Alkabetz M, Salinas C, Vitale L, Burés-Jelstrup A, Nucci P, et al. (2011) En face optical coherence tomography of inner retinal defects after internal limiting membrane peeling for idiopathic macular hole. *Invest Ophthalmol Vis Sci* 52: 8349-8355.
19. Clark A, Balducci N, Pichi F, Veronese C, Morara M, et al. (2012) Swelling of the arcuate nerve fiber layer after internal limiting membrane peeling. *Retina* 32: 1608-1613.