

Lymphogranuloma Venereum: Report of Two Cases with "Bubonulus" As Primary Stage and Immunohistochemical Demonstration of Chlamydia Trachomatis

Federico Feltes^{1*}, Lara Vallés¹, Inmaculada Alcaraz¹, Heinz Kutzner² and Luis Requena¹

¹Dermatology Department, Fundación Jimenez Díaz, Universidad Autónoma, Madrid, Spain

²Dermatopathology Friedrichshafen, Friedrichshafen, Germany

*Corresponding author: Federico Feltes, Dermatology Department, Fundación Jimenez Díaz, Universidad Autónoma, Plaza Ciudad de Viena 6, 5th floor, door 507, Madrid, 28040, Madrid, Spain, Tel: 0034 606311649, E-mail: fedefeltes@hotmail.com

Received date: December 29, 2014, Accepted date: Jan 26, 2015, Published date: Jan 31, 2015

Copyright:© 2015 Federico Feltes et al. This is an open-access article distributed under the terms of the Creative Commons Attribution License, which permits unrestricted use, distribution, and reproduction in any medium, provided the original author and source are credited.

Abstract

We report two cases of lymphogranuloma venereum that manifested initially with an inflammatory nodule in the foreskin, a rare lesion known as "bubonulus". Both patients were men who have sex with men, HIV positive, in good immunologic condition, and lacked any other factor that could possibly explain the development of this form of presentation. Immunohistochemically, *Chlamydia* particles were found in lesional skin.

Keywords: Lymphogranuloma venereum; Bubonulus; Chlamydia trachomatis; Immunohistochemistry

Introduction

Since 2003, there has been a considerable rise in the incidence of lymphogranuloma venereum in Western countries, almost exclusively in men who have sex with men (MSM). Proctitis has been by far the most common clinical manifestation of this infection in this scenario [1,2]. The traditional description of the initial presentation of the disease consists of a small and painless papule or ulcer in the genitalia, followed by inguinal lymphadenopathies, named buboes as secondary stage.

Other typical primary manifestations described include acute proctitis and urethritis, and less commonly a perianal ulcer in MSM [2].

We report two cases of lymphogranuloma venereum in MSM who presented with bubonulus involving the foreskin. Immunohistopathological study demonstrated the presence of *Chlamydia trachomatis* in lesional skin.

Case Reports

Case 1

A 51-year-old male, MSM, with a ten year history of HIV infection on highly active antiretroviral therapy (HAART) with emtricitabine, tenofovir and ritonavir, presented with a 15-day asymptomatic nodule in the penis, which had developed 72 hours after sexual intercourse without protection with a casual partner. The lesion showed progressive enlargement until it reached 4 cm in maximum diameter (Figure 1). Foreskin retraction was impossible.

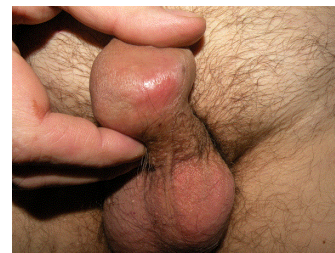

Figure 1: Inflammatory nodule in the foresking of the penis, the so-called "bubonulus".

In the next days, the patient developed inguinal lymphadenopathies. There was neither scrotal edema, nor rectal symptoms. Systemic symptoms, like fever or malaise, were lacking. Rectal examination failed to disclose any anomaly. Patient clinical history included past hepatitis B already cured. He had started treatment at the moment of diagnosis of HIV that was made in a screening test when he was still asymptomatic and CD4+ count was 191. The patient had positive IgG for CMV and Epstein Barr virus, but did not suffer other opportunistic infections. Last laboratory assessment showed a CD4+ count at 464/μl and an undetectable HIV RNA. Syphilis serology by chemoluminescence and antibodies against hepatitis C virus were negative.

Chlamydia trachomatis infection was demonstrated by PCR in the biopsy of the penis lesion. Serovar L2b was identified by restriction fragment length polymorphism of omp 1 gene amplified by polymerase chain reaction (PCR-RFLP genotyping). Histopathology showed a dense diffuse inflammatory infiltrate involving the entire thickness of the dermis. This infiltrate was composed of lymphocytes, plasma cells, histiocytes and neutrophils, and in some areas was arranged in nodular and granulomatous patterns (Figure 2A-2C). Immunohistochemistry with a monoclonal antibody reactive against *Chlamydia trachomatis* D/K and L2 serovars (Acris Antibodies catalog

number AM00660PU-N, Inc. San Diego, CA; USA) demonstrated the presence of the microorganisms within the cytoplasm of some histiocytes of the granulomatous areas (Figure 2D). *Klebsiella granulomatis* and *Haemophilus ducreyi* PCR tests were negative. The patient was treated with oral doxycycline 100 mg/12 hours for 3 weeks with complete remission of the lesion.

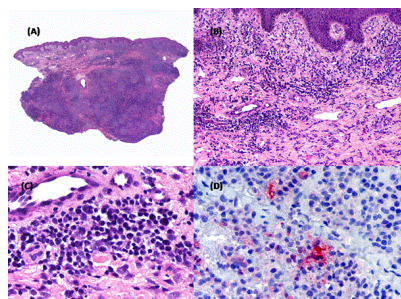


Figure 2: Case 1. (A), (B) and (C), Hematoxylin & eosin stain. Dense inflammatory infiltrate composed of lymphocytes, plasma cells, histiocytes and neutrophils. (D), Immunohistochemistry showing *Chlamydia trachomatis* particles in lesional tissue.

Case 2

A 49-year-old, HIV positive MSM developed a painless nodule in the foreskin. He was under treatment with Efavirenz, Emtricitabina and Tenofovir disoproxil, with good immunological status. He had been diagnosed HIV nineteen years before and started antiretroviral treatment. The patient had history of asymptomatic left varicocele and perianal warts. He also had had oropharyngeal candidiasis, difficult-to-treat right leg cellulitis ten years before, that finally resolved without sequelae with IV antibiotic therapy, and was under primary prophylaxis against *Pneumocystis jirovecii* with inhaled pentamidine upon previous skin reaction to the sulfa component of cotrimoxazole. He admitted unprotected sex with anonymous partners, but denied the use of sexual toys or traumatic practices. The patient complained of a nodule that slowly enlarged during the last two months, with a pick growth two weeks prior to consultation.

Physical examination demonstrated a painless lobulated nodule involving the foreskin, which was elastic in some areas and indurated in other ones (Figure 3). There were large painful left inguinal lymphadenopathies, with fluctuation.

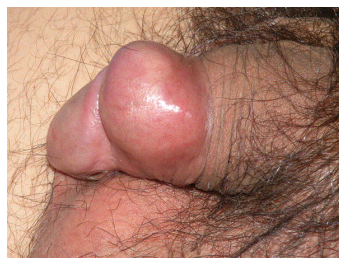


Figure 3: Case 2. Bubonulus in the penis.

The laboratory tests resulted negative for antibodies against *Treponema pallidum*, and HIV RNA was undetectable. The CD4

count was 45/mcL. Histopathology showed nodular infiltrates involving superficial and deep dermis. These nodules were composed of lymphocytes, plasma cells, histiocytes and neutrophils (Figure 4). *Chlamydia trachomatis* particles were found by immunohistochemistry (Figure 4) and by PCR on tissue. Serovar L2b was identified by PCR-RFLP genotyping. *Klebsiella granulomatis* and *Haemophilus ducreyi* PCR tests were negative. The patient was treated with doxycycline 100 mg/12 hours for 3 weeks, with significant improvement of the inflammation of the foreskin, although inguinal buboes needed to be aspirated to achieve full resolution.

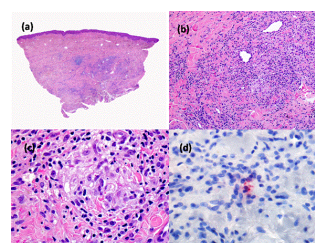


Figure 4: Case 2. (A), (B) and (C), Hematoxylin & eosin stain. Like in Case 1, there was nodular dense inflammatory infiltrate composed of lymphocytes, plasma cells, histiocytes and neutrophils. (D), Immunohistochemistry showing *Chlamydia trachomatis* particles in lesional tissue.

Discussion

Lymphogranuloma venereum (LGV) is a sexually transmitted systemic infection caused by *Chlamydia trachomatis* L1, L2 and L3 serovars. In contrast with other serovars, it does not infect mucosal cells but macrophages instead, leading to the development of lymphadenitis and buboes formation. Three stages in the course of the untreated disease have been described. The first is characterized by a papule or ulcer in the mucosa, where the organism is inoculated. The second stage manifests as an inguinal syndrome, with large lymphadenopathies in men who acquire the infection through the urethra or penis mucosa, or pelvic lymphadenopathies, in the case of women with vaginal acquisition of the disease [3]. Proctitis has been the main form of presentation of LGV in recent years in developed countries, with cases reported in Europe, North America and Australia, almost exclusively among HIV-MSM. Pharyngeal presentation is also possible, with cervical lymphadenopathies. Persistent perianal or genital ulcer was also reported [4,5].

Since a first outbreak reported in Netherlands in 2003, new ones took place in many other Western countries [6]. Despite much more awareness in health services about this phenomenon, the situation is far from being controlled, and trends are on the rise. HIV-1 infection is the strongest single risk factor associated with anorectal LGV. The oligosymptomatic nature of the most common presentation of the disease, which is affecting the rectum in MSM, and high-risk sexual behavior are the main factors that make control of these outbreaks particularly difficult, as well as complete absence of symptoms in up to 25% of cases as recently published. Therefore, routine screening in risk groups should be intensified [7].

Serovar L2b *Chlamydia trachomatis* is generally found in LGV cases throughout Western countries, as was the case in our patients [1,2,7].

Whereas most cases affect the anorectal area, Herida et al. published the first case of urethritis due to L2b [8].

Bubonulus is an uncommon form of primary stage of LGV. It was first described by Brandt in 1940 [9]. It is thought to develop from initial lymphangitis of the dorsal penis, with formation of a nodule that, if persists, will lead to fibrosis and chronic elephantiasis, which characterizes the third stage of LGV infection. This chronic condition due to fibrosis and lymphatic edema results in a penis deformity known as "saxophone penis", which is different from the acute "bubonulus" here described. In women, the vulva equivalent for saxophone penis would be "esthiomene". To the best of our knowledge, no equivalent for bubonulus has been described in female patients. After the original description by Brandt, a thorough histopathologic description was made by Sheldon et al. [11] and other cases were reported as well. Spenatto et al. [12] reported a case of bubonulus associated with "cock ring" use, a device that, placed at the base of the penis, decreases blood (and lymph) flow. Whether this unusual presentation is related to host immunity, sexual practices or other factors is still uncertain.

According to previous descriptions and the findings in our own cases, histopathology of the lesion usually shows normal or papillomatous epidermis, edema and lymphangiectasia in superficial dermis and dense infiltrate in reticular dermis. This infiltrate is often arranged in clusters configuring a granulomatous pattern throughout the dermis or in perivascular fashion. It is mostly composed of lymphocytes, plasma cells and histiocytes, but sometimes multinucleated giant cells are also present.

Immunohistochemistry for Chlamydia trachomatis may be performed to demonstrate the microorganism in tissue samples.

Dermatologists should be aware of this clinical presentation of LGV in their daily practice, allowing a faster and accurate diagnosis of LGV, as well as prompt treatment.

References

1. Savage EJ, van de Laar MJ, Galloway A, van der Sande M, Hamouda O, et al. (2009) Lymphogranuloma venereum in Europe, 2003-2008. *Euro Surveill* 14.
2. Richardson D, Goldmeier D (2007) Lymphogranuloma venereum: an emerging cause of proctitis in men who have sex with men. *Int J STD AIDS* 18: 11-14.
3. (2010) Centers for Disease Control and Prevention. 2006 Guidelines for treatment of sexually transmitted diseases. *MMWR Morb Mort Wkly Rep*. 59: 18-26.
4. Singhrao T, Higham E, French P (2011) Lymphogranuloma venereum presenting as perianal ulceration: an emerging clinical presentation? *Sex Transm Infect* 87: 123-124.
5. Marcotte T, Lee Y, Pandori M, Jain V, Cohen SE (2014) Lymphogranuloma venereum causing a persistent genital ulcer. *Sex Transm Dis* 41: 280-282.
6. Martin-Iguacel R, Llibre JM, Nielsen H, Heras E, Matas L, et al. (2010) Lymphogranuloma venereum proctocolitis: a silent endemic disease in men who have sex with men in industrialised countries. *Eur J Clin Microbiol Infect Dis* 29: 917-925.
7. de Vrieze NH, de Vries HJ (2014) Lymphogranuloma venereum among men who have sex with men. An epidemiological and clinical review. *Expert Rev Anti Infect Ther* 12: 697-704.
8. Herida M, Kreplack G, Cardon B, Desenclos JC, de Barbeyrac B (2006) First case of urethritis due to Chlamydia trachomatis genovar L2b. *Clin Infect Dis* 43: 268-269.
9. Brandt R (1940) "Bubonulus" in lymphogranuloma venereum. *Arch Derm Syphilol*. 42: 811-813.
10. Kumaran MS, Gupta S, Ajith C, Kalra N, Sethi S, et al. (2006) Saxophone penis revisited. *Int J STD AIDS* 17: 65-66.
11. Sheldon WH, Heyman A (1947) Lymphogranuloma Venereum: A Histologic Study of the Primary Lesion, Bubonulus, and Lymph Nodes in Cases Proved by Isolation of the Virus. *Am J Pathol* 23: 653-671.
12. Spenatto N, Boulinguez S, de Barbeyrac B, Viraben R (2007) First case of "bubonulus" in L2 lymphogranuloma venereum. *Sex Transm Infect* 83: 337-338.