

## Vogt-Koyanagi-Harada Syndrome in a Healthy African-American Woman: Case Report and Review of Literature

Steven S. Saraf, Yogin Patel, Ankit Desai\* and Uday Desai

Department of Ophthalmology, Henry Ford Hospital, Detroit, Michigan, USA

\*Corresponding author: Steven S. Saraf, MD, Department of Ophthalmology, Henry Ford Hospital, Detroit, Michigan, USA, E-mail: [SSARAF1@hfhs.org](mailto:SSARAF1@hfhs.org)

Received date: January 03, 2015; Accepted date: January 19, 2015; Published date: January 26, 2015

Copyright: © 2015 Saraf S, et al. This is an open-access article distributed under the terms of the Creative Commons Attribution License, which permits unrestricted use, distribution, and reproduction in any medium, provided the original author and source are credited.

### Abstract

A previously healthy 18 year-old African-American female presented with unilateral vision loss associated with headaches. Initial ocular examination revealed an exudative retinal detachment involving the macula, disc edema, and choroidal striae worse in the right than the left eye. Fluorescein angiography showed multiple punctate hyperfluorescent lesions with leakage into the subretinal space. Extensive work up led to the diagnosis of Vogt-Koyanagi-Harada syndrome. The patient was treated with a prolonged taper of systemic prednisone and approximately 4 months after presentation, vision improved to 20/20 in the right eye and 20/25 in the left eye.

**Keywords:** Vogt-Koyanagi-Harada syndrome; African-american woman; Case report; Health

### Background

Vogt-Koyanagi-Harada (VKH) syndrome is an inflammatory systemic disease affecting multiple pigment rich tissues in the body including the uvea, meninges, skin, and inner ear. Ophthalmic manifestations include bilateral granulomatous panuveitis, thickened choroid, exudative retinal detachment, and anterior chamber reaction. Systemic sequelae include vitiligo, poliosis, alopecia, meningismus, and dysacusia. The underlying pathophysiology involves an immune-mediated attack of pigmented cells in the affected organ systems.

Consequently, VKH syndrome is more common in individuals with darker skin pigmentation. However, it has been known to occur rarely in those of African descent compared to other darkly pigmented races including Asians, Hispanics, Native Americans, Asian Indians, and Middle Easterners.

We report an uncommon case of new onset VKH syndrome in a young African-American woman with characteristic fundus findings and angiographic features. We review the epidemiology, characteristic findings, and management of those with new onset VKH syndrome.

### Case Presentation

An 18-year old woman with a history of astigmatism presented with the complaint of blurred vision in the right eye for two weeks. The patient's symptoms were first noticed following an emotional event that incited "color changes" in the vision of the affected eye. Shortly after the onset of her symptoms, she experienced a severe headache localized to her temples. Although she had a history of frequent headaches, she describes the new headache to be unlike any prior episodes. The headaches were of variable duration with minimal relief when taking aspirin. She denied having any photophobia or other ocular symptoms in her left eye.

A careful review of systems did not reveal any recent fevers or chills, skin changes, hair changes, joint problems, hearing changes, recent

infections or viral prodrome. The patient also denied any history of eye trauma or surgery.

On ophthalmologic examination, visual acuity was found to be 20/60 in the right eye and 20/30 in the left eye. Tonometry, pupil exam, confrontational visual fields, and extraocular movements were all within normal limits. Amsler grid testing mapped scotomas superior and inferior to fixation in the right eye. Slit-lamp examination of the anterior segment was unremarkable for both eyes. Bilateral dilated fundus exam did not show any vitreous cell or opacities. The margin of the right optic nerve appeared edematous with associated choroidal striae extending into the macula. A serous retinal detachment was noted in the inferior macula along with creamy white infiltrates (Figure 1). Dilated fundus exam of the left eye was remarkable for only choroidal striae involving the macula.

Fluorescein angiography demonstrated early spotted choroidal hyperfluorescence in the inferior right macula with late stages showing leakage and pooling (Figure 2). Ocular coherence tomography (OCT) showed significant submacular fluid in the right eye with mild irregularity of the foveal contour in the left eye (Figure 3).

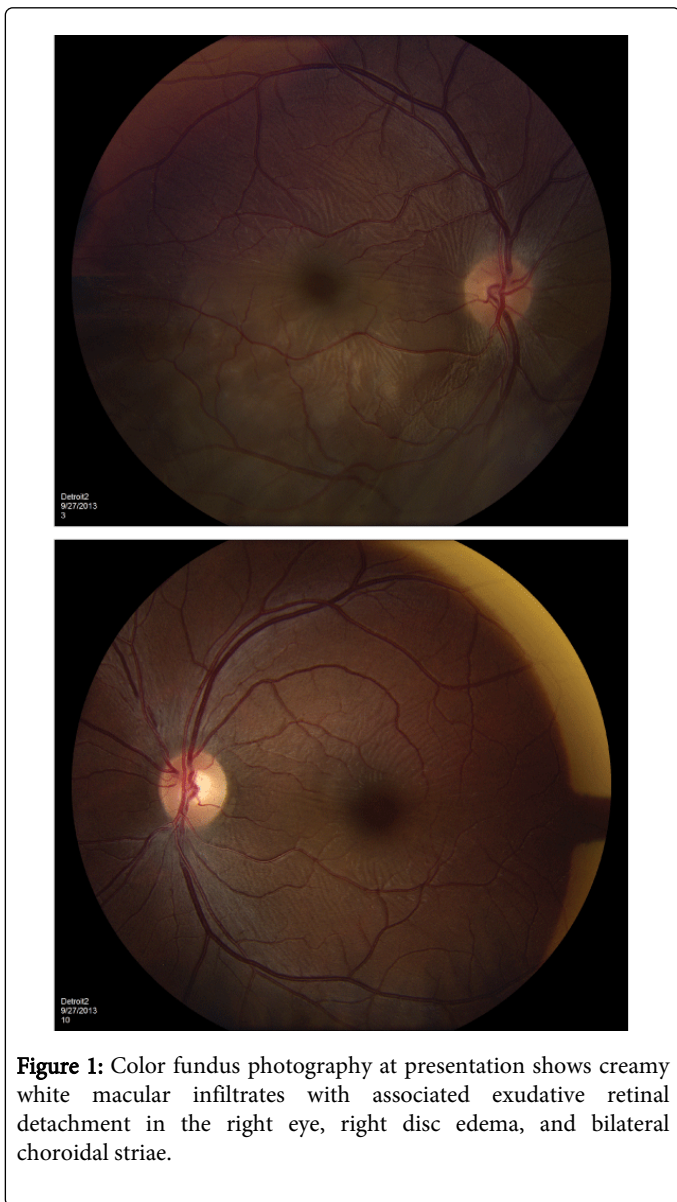The patient experienced an allergic reaction to the fluorescein, for which she was taken to the emergency department. She was given a prescription for oral prednisone and subsequently left against medical advice.

The patient returned to clinic a few days later with worsening of vision in her left eye and new complaints of photophobia and aniseikonia. Ophthalmic exam was remarkable for bilateral anterior chamber cell, decreased vision in the left eye measuring 20/60, and stable vision in the right eye. Dilated fundus exam of the right eye showed improved serous detachment, while the left eye remained stable.

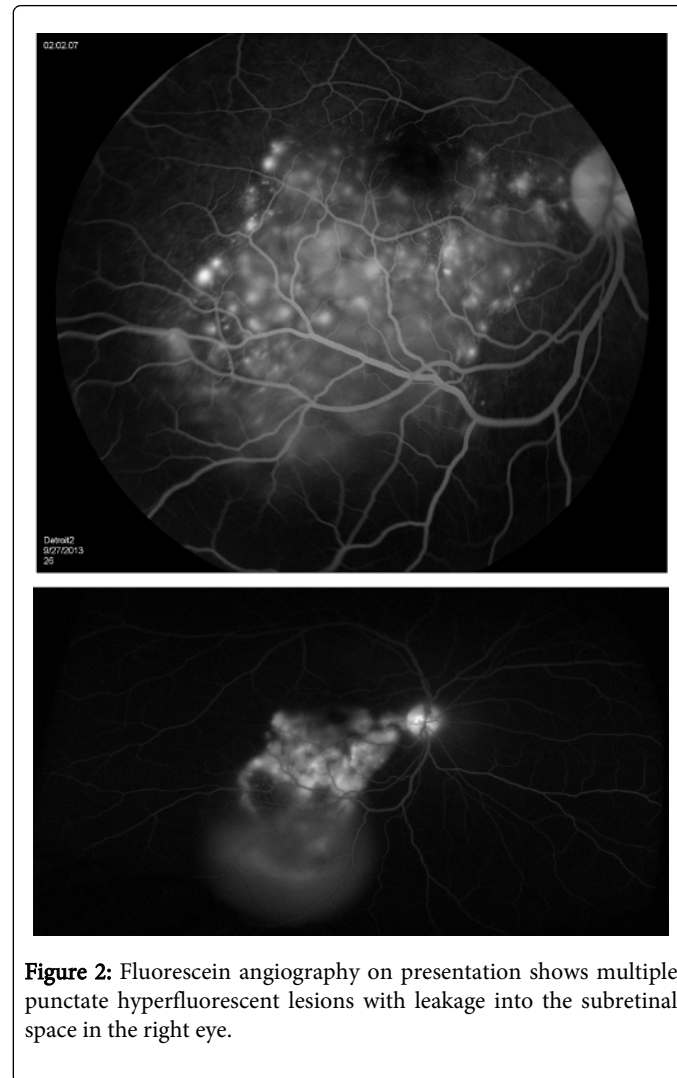
Outpatient laboratory work-up including angiotensin converting enzyme level, lysozyme level, chest x-ray, *Toxoplasma gondii* antibodies, Treponemal antibodies, RPR, *Toxocara* antibodies, quantiferon gold, Lyme antibody, ANA, and *Bartonella* antibodies, did not yield any positive results. Lumbar puncture for suspected VKH syndrome was performed but cerebrospinal fluid (CSF) analysis did

not show pleocytosis. Additional testing to detect melanin-laden macrophages was not performed.

follow up visits the choroidal striae resolved. The patient reported resolution of aniseikonia with a return to her baseline visual functioning.

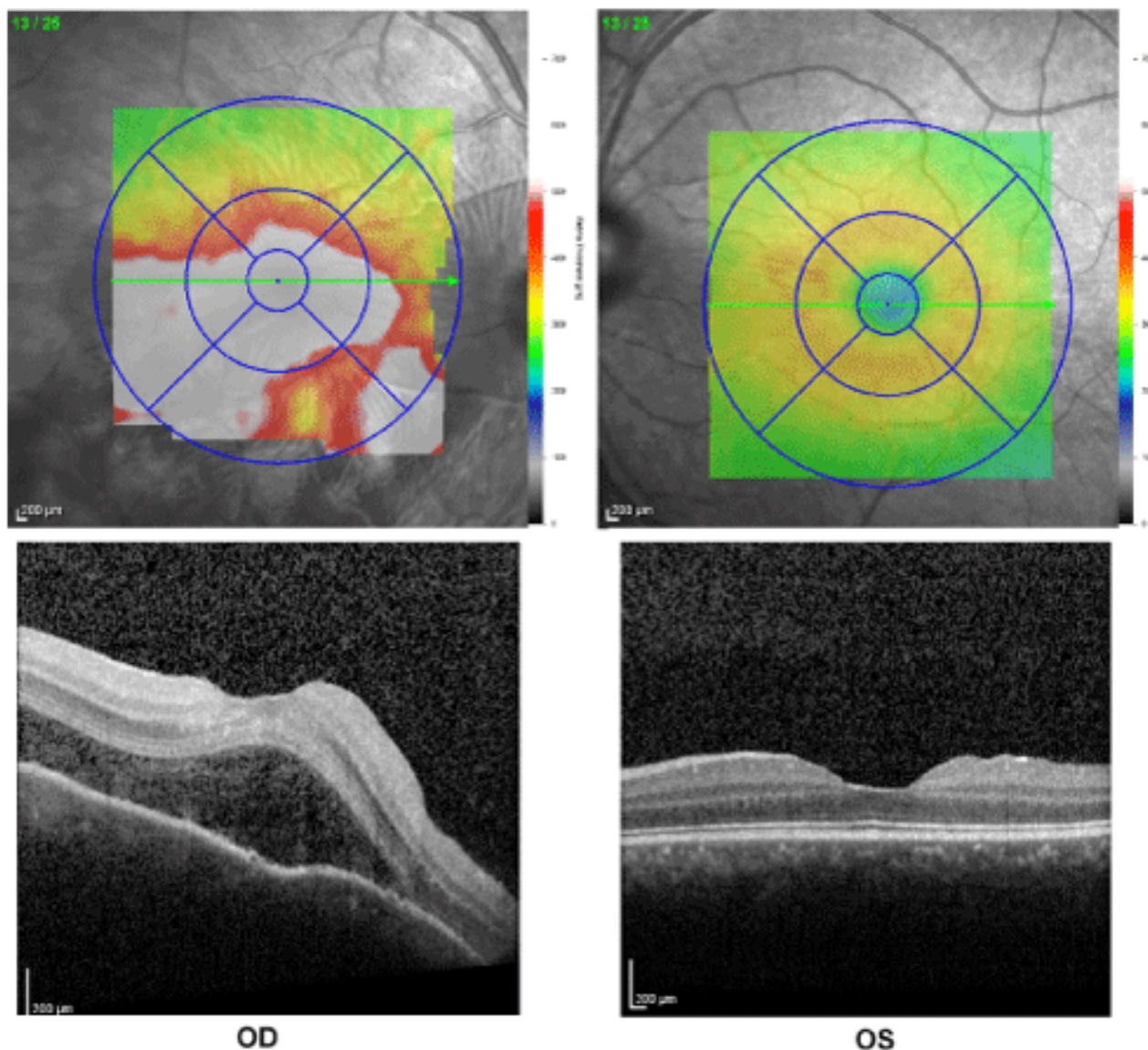


At the time of suspected diagnosis the patient had an extensive negative laboratory work-up, no history of ocular surgery or trauma, meningismus-type headache, and bilateral ocular inflammation meeting four of five criteria, as defined by the First International Workshop on VKH disease, for the diagnosis of incomplete VKH syndrome. The patient was initiated on Prednisone 60 mg with gradual taper over the next 6 months. The patient had recovery of vision to 20/20 in the right eye and 20/25 in the left eye. After several



## Discussion

Vogt-Koyanagi-Harada (VKH) syndrome is a systemic autoimmune disease, which targets melanin-rich pigmented cells. Vogt initially noticed the combination of bilateral anterior uveitis, vitiligo, poliosis, alopecia, and dysacusia in 1906. Koyanagi then came to the same conclusion in 1929. Harada finally described a case with posterior uveitis, cerebrospinal pleocytosis, and an exudative retinal detachment in 1926. Since then these manifestations have been grouped together in what is known as VKH syndrome [1].



**Figure 3:** Ocular coherence tomography on presentation demonstrates submacular fluid in the right eye with only mild changes in foveal contour in the left eye.

The disease follows a particular time course initially presenting in a prodromal phase with non-specific symptoms including fever, headache, vertigo, and dysacusis. Rarely focal neurological signs may be present. Cerebrospinal fluid cell count may show pleocytosis. Three to five days later, the acute ocular phase begins with a marked granulomatous uveitis with often associated thickened posterior choroid. Symptoms include blurred vision, photophobia, and pain. Exudative retinal detachments start as small focal shallow areas of elevation with folds that may coalesce into large bullous lesions in advanced cases. Optic nerve swelling develops in the majority of patients. The inflammatory reaction targets primarily the choroid with relative sparing of the choriocapillaris and overlying retina. Mutton fat keratic precipitates and iris nodules are common findings. Swelling of the ciliary body may result in anterior displacement of the lens iris

diaphragm shallowing the anterior chamber and precipitating bouts of acute angle closure. The ocular manifestations closely resemble sympathetic ophthalmia and a detailed history of prior eye trauma or surgery should be obtained. In the convalescent phase following treatment, the retinal detachments resolve and the uveitis is extinguished. The now atrophic pigmented cells result in an orange-red “sunset glow” fundus. Focal loss of segments of the retinal pigment epithelium results in nummular depigmented scars. Aggregates of lymphocytes and pigment laden macrophages form Dalen-Fuchs nodules. Subretinal fibrosis and pigment clumping are also commonly seen. Depigmentation of the limbus may occur, referred to as Sugiura sign [2,3].

VKH-related uveitis can be indolent and chronic and may recur. Recurrent bouts result in most of the vision threatening complications.

Retinal vasculitis and arteriovenous anastomosis are responses to chronic inflammation. Choroidal neovascularization and hemorrhage can occur, threatening vision. Posterior synechiae and iris atrophy are common. The ciliary body band may lose its pigmentation when viewed by gonioscopy. Long term sequelae of chronic steroid treatment are also common, including cataract formation, intraocular pressure elevation, and secondary angle closure [3].

Involvement of the meninges, skin, and inner ear may result in meningismus, vitiligo, and dysacusis respectively. Encephalitis with cranial nerve palsy, aphasia, and personality changes have been described. However, alopecia and poliosis are the most often found systemic manifestations [3].

VKH is common among pigmented individuals including Asians, Hispanics, Native Americans, Asian Indians, and Middle Eastern people. It is rare among Caucasian and interestingly Africans. The incidence in the United States is 1.5 to 1.6 million per 1 million patients. There is a slight female preponderance, and it affects people most often in the third to fifth decade of life. There is a genetic link in certain HLA alleles including HLA-DR4 and HLA-Dw53 with the most significant association being with HLA-DRB1\*0405 [2,3].

The predilection for certain races of people varies widely from study to study. Africans appear to make up a smaller proportion of cases relative to their degree of pigmentation. Some have found in California that African American patients comprise 14% of their cases, while others in NIH studies report percentages as high as 35% [4,5].

The pathogenesis is centered on an immune mediated attack of pigmented cells. The most heavily targeted uveal tissues are those in closest proximity to the optic nerve. The histologic hallmarks are non-necrotizing granulomatous infiltration with resultant thickening of the choroid with relative sparing of the choriocapillaris and retina. This

inflammation may extend anterior to include the ciliary body and even iris. During the convalescent phase, the level of inflammation subsides. Generalized loss of RPE leads to alteration of the color of the fundus and depigmented scars form, coinciding with areas of chorioretinal adhesion. The chronic recurrent phase is marked by mild smoldering inflammation with RPE atrophy and hyperplasia forming hyperpigmented lesions, subretinal fibrosis, and subretinal neovascular membranes. The immune response is thought to be T cell mediated. This may be triggered by molecular mimicry [6]. Tyrosinase has been postulated to be a target and may share protein sequences with cytomegalovirus [7]. Epstein-Barr virus has also been thought to be a trigger with viral DNA found in the vitreous of VKH patients [8]. Attack of these melanocyte specific proteins lead to all the systemic manifestations of the disease.

Diagnosis of VKH is made primarily from clinical features, angiographic features, and the exclusion of other causes. The first international workshop on VKH disease proposed a diagnostic schema in 2001. A complete diagnosis of the disease requires five criteria to be met (Table 1). First, there must be no history of penetrating eye trauma or surgery prior to the onset of uveitis. Second, a laboratory work up is necessary to rule out other causes. Third, there must be bilateral eye involvement with characteristic exam findings (of early or late disease), fluorescein angiographic findings, or echographic evidence of diffuse choroidal thickening. Fourth, there must be neurologic or auditory findings. Fifth, there must be integumentary findings not preceding the onset of neurologic or ocular disease. If only the first three criteria are met with either four or five present, this is defined as incomplete disease. If only the first three criteria are met then the process is isolated to the eyes and it is defined as probable disease [9]. Our patient did not manifest integumentary changes but did suffer from severe headaches, classifying her as incomplete disease.

<b>Complete diagnosis requires criteria 1 to 5 be present</b>
1. No prior ocular trauma or surgery preceding uveitis
2. Clinical and laboratory work up is not suggestive of other disease process
3. Bilateral ocular involvement as characterized by either -Early manifestations: choroiditis, exudative retinal detachment, characteristic fluorescein angiographic findings, or choroidal thickening on B-scan -Late manifestations: suggestive history of prior uveitis, ocular depigmentation (sunset glow fundus or Sugiura sign) and other ocular signs such as chorioretinal scars, RPE clumping, or anterior uveitis
4. Neurologic or auditory findings Including meningismus, tinnitus, or cerebrospinal fluid pleocytosis
5. Integumentary findings, with onset after ocular or central nervous system disease Including alopecia, poliosis, or vitiligo
<b>Incomplete disease (criteria 1 to 3 and either 4 or 5 are present)</b>
<b>Probable disease (only criteria 1 to 3 are met, isolated ocular disease)</b>

**Table 1:** Diagnostic criteria for VKH Syndrome proposed by the First International Workshop on VKH disease [2,9].

The prevalence of complete versus incomplete disease is unknown. In a retrospective review of 48 patients, Beniz et al. report the prevalence of headache (67%), tinnitus (17%), dysacusis (13%), vitiligo (10%), alopecia (13%), and poliosis (6%). In this study, extraocular involvement beside headache were unusual, suggesting that the diagnosis of complete disease may be more uncommon than incomplete disease [4].

Laboratory testing may be of use in less obvious cases. Nakamura et al. utilized a protocol wherein CSF samples from 7 patients with VKH were stained with May-Grünwald and evaluated by a silver impregnation method. The process stains melanin granules within the macrophages of the CSF, which if present may be indicative of the underlying immunopathologic process of VKH. The granules were confirmed to be melanin positive by HMB-45 immunohistochemical

testing. Six out of the seven patients in the study tested positive for melanin-laden macrophages in the CSF, suggesting that the protocol may be of utility [10].

Characteristic fluorescein angiographic findings of VKH in order of prevalence include disc hyperfluorescence, early pinpoint areas of hyperfluorescence, delayed areas of choroidal perfusion, choroidal vessel hyperfluorescence, persistent small and large dark dots, late pooling, and choroidal striae. With univariate analysis, when there were areas of pinpoint peripapillary hyperfluorescence, a poorer prognosis was portended. This finding held true when controlled for age at onset, gender, and duration of follow up [11]. Signs of good prognostic outcome include good visual acuity at 1 month, younger age at onset, and early treatment with high-dose corticosteroids [12].

Studies have shown that early therapy with steroids with prolonged taper is important in preventing an acute episode from becoming recurrent. In a retrospective analysis by Lai et al. of 35 patients with new onset VKH syndrome, 17 patients received oral corticosteroid for less than 6 months duration while 18 received oral corticosteroid for greater than 6 months. In the group with less than 6 months treatment, the recurrence rate was 58.8% (10 patients), while the greater than 6 months group recurred at a rate of 11.1% (2 patients). Their findings were adjusted for age, gender, and initial oral dose of corticosteroid. They also found that those with the more rapid taper were more likely to have poorer visual outcomes [13]. Our patient was tapered off of prednisone over a 6 month period and has remained free of recurrence without need for further immunosuppression. Lai et al. [13] did not describe specifics of the steroid regimen implemented in their study nor the speed of the taper each month. In the setting of long-term steroid use, we recommend collaboration with the patient's primary care doctor to help monitor potentially serious side effects of corticosteroid use. Treatment of chronic disease may require systemic immunosuppression with steroid-sparing agents such as methotrexate, cyclosporine, tacrolimus, cyclophosphamide, chlorambucil, azathioprine and intravenous immunoglobulin (IVIG).

Our review suggests that beside our patient being of African descent, her presentation is typical as she meets the criteria for incomplete disease and lacks integumentary findings, the rarest component of the diagnostic criteria as observed by Beniz et al. [4] However, her case is unique given that those of African descent appear to present less commonly than other pigmented races in some studies. Our case highlights the fact that VKH syndrome may still occur in

those of African descent and should be kept in the differential, especially when the diagnostic criteria of the disease are met. Initial treatment with corticosteroids with prolonged taper of at least 6 months is advised and has prevented recurrence in our patient.

## References

1. Greco A, Fusconi M, Gallo A, Turchetta R, Marinelli C, et al. (2013) Vogt-Koyanagi-Harada syndrome. *Autoimmun Rev* 12: 1033-1038.
2. Sakata VM, da Silva FT, Hirata CE, de Carvalho JF, Yamamoto JH (2014) Diagnosis and classification of Vogt-Koyanagi-Harada disease. *Autoimmun Rev* 13: 550-555.
3. Andreoli CM, Foster CS (2006) Vogt-Koyanagi-Harada disease. *Int Ophthalmol Clin* 46: 111-122.
4. Beniz J, Forster DJ, Lean JS, Smith RE, Rao NA (1991) Variations in clinical features of the Vogt-Koyanagi-Harada syndrome. *Retina* 11: 275-280.
5. Nussenblatt RB (1988) Clinical studies of Vogt-Koyanagi-Harada's disease at the National Eye Institute, NIH, USA. *Jpn J Ophthalmol* 32: 330-333.
6. Yamaki K, Gocho K, Sakuragi S (2002) Pathogenesis of Vogt-Koyanagi-Harada disease. *Int Ophthalmol Clin* 42: 13-23.
7. Sugita S, Takase H, Kawaguchi T, Taguchi C, Mochizuki M (2007) Cross-reaction between tyrosinase peptides and cytomegalovirus antigen by T cells from patients with Vogt-Koyanagi-Harada disease. *Int Ophthalmol* 27: 87-95.
8. Bassili SS, Peyman GA, Gebhardt BM, Daun M, Ganiban GJ, et al. (1996) Detection of Epstein-Barr virus DNA by polymerase chain reaction in the vitreous from a patient with Vogt-Koyanagi-Harada syndrome. *Retina* 16: 160-161.
9. Read RW, Holland GN, Rao NA, Tabbara KF, Ohno S, et al. (2001) Revised diagnostic criteria for Vogt-Koyanagi-Harada disease: report of an international committee on nomenclature. *Am J Ophthalmol* 131: 647-652.
10. Nakamura S, Nakazawa M, Yoshioka M, Nagano I, Nakamura H, et al. (1996) Melanin-laden macrophages in cerebrospinal fluid in Vogt-Koyanagi-Harada syndrome. *Arch Ophthalmol* 114: 1184-1188.
11. Chee SP, Jap A, Cheung CM (2010) The prognostic value of angiography in Vogt-Koyanagi-Harada disease. *Am J Ophthalmol* 150: 888-893.
12. Chee SP, Jap A, Bacsal K (2009) Prognostic factors of Vogt-Koyanagi-Harada disease in Singapore. *Am J Ophthalmol* 147: 154-161.
13. Lai TY, Chan RP, Chan CK, Lam DS (2009) Effects of the duration of initial oral corticosteroid treatment on the recurrence of inflammation in Vogt-Koyanagi-Harada disease. *Eye (Lond)* 23: 543-548.