

## Ocular Manifestations in Systemic Lupus Erythematosus

Sutasinee Boonsopon<sup>1,2</sup>, Armin Maghsoudlou<sup>1,2</sup> and Charles Stephen Foster<sup>1,2,3\*</sup>

<sup>1</sup>Massachusetts Eye Research and Surgery Institution (MERSI), Cambridge, MA, USA

<sup>2</sup>Ocular Immunology and Uveitis Foundation, USA

<sup>3</sup>Harvard Medical School, Cambridge, MA, USA

\*Corresponding author: Charles Stephen Foster, Massachusetts Eye Research and Surgery Institution, 355 Main Street, 8th Floor, Cambridge, MA 02142 USA, Tel: 617-621-6377; Fax: 617-494-1430; E-mail: [sfoster@mersi.com](mailto:sfoster@mersi.com)

Received date: February 20, 2015; Accepted date: March 24, 2015; Published date: March 30, 2015

Copyright: © 2015 Boonsopon S, et al. This is an open-access article distributed under the terms of the Creative Commons Attribution License, which permits unrestricted use, distribution, and reproduction in any medium, provided the original author and source are credited.

### Abstract

Systemic lupus erythematosus (SLE) is an autoimmune disease manifest with multiple organ system involvement. Even though the eye is not part of the diagnostic criteria, once it gets affected, it will alter patients' quality of life. The purpose of this review is to point out the significance of ocular manifestations in SLE and to emphasize the importance of possible blinding complications such as peripheral ulcerative keratitis, scleritis, and SLE retinopathy/ choroidopathy. The condition can be even worse when SLE is accompanied with antiphospholipid syndrome. In addition to the disease itself, several treatment agents that are used in SLE are responsible for vision threatening conditions; thus they have to be given with caution because of potential side effects, including cataract, glaucoma, and chloroquine maculopathy.

**Keywords:** Systemic lupus erythematosus; Antiphospholipid syndrome; Ocular manifestations; Vision threatening

### Introduction

Systemic lupus erythematosus (SLE) is a chronic autoimmune disease that has multisystem involvement. It is a challenging disease to diagnose, assess and manage. Many factors of this disease have been postulated including genetic susceptibility, environmental effects, and disturbances in both innate and adaptive immunity [1]. The highest prevalence has been reported in Italy, Spain, Martinique, and the African-Caribbean population [2]. The eye is not a primary target of immune mediated damage in SLE, but can be affected in a variety of ways resulting in significant ocular morbidity [3]. This can occur in up to one third of patients and it can be a marker for overall systemic disease activity [4]. Eye symptoms are easily neglected by patients who are overwhelmed with major organ involvement when their disease is active, but delayed diagnosis and treatment may lead to permanent eye damage and visual loss. This article aims to review the ocular manifestations in SLE that are related to the disease itself, manifestations related to antiphospholipid syndrome, and manifestations secondary to medications. Early detection, early diagnosis and prompt referral to ophthalmologists can prevent permanent visual loss in some instances.

### Pathophysiology and Immunology

Many mechanisms are involved in SLE related ocular lesions. These include immune complex deposition and other antibody related mechanisms, vasculitis, and thrombosis [5]. Cytokine dysregulation, polyclonal B-cell activation, autoantibody production, and increased immune complex formation due to aberrations involving hyperactive B cells, T cells, and cells of the monocytic lineage are also postulated [6]. Deficiencies in components of the complement cascade are well known to the development of SLE. Some of the strongest associated risk loci identified through genome-wide association studies are

ITGAM, FcγR, PRDM1-ATG5, and TNFAIP3 [1]. Immune complex deposition has been identified in blood vessels of the conjunctiva, retina, choroid, sclera, and ciliary body [7]. Circulating antibodies such as antiphospholipid antibodies (in particular interest in β<sub>2</sub>-glycoprotein) [1] and antineuronal antibodies also play a role by increased liability to thrombosis [8]. The role of anti-neuronal antibodies is evidenced in neuropsychiatric lupus [9]. There were 20 autoantibodies detected in the serum or cerebrospinal fluid of patients with neuropsychiatric lupus and they were categorized into brain-specific and systemic autoantibodies. Brain-specific autoantibodies included those binding neuronal, brain reactive (BRAA), N-methyl-D-aspartate receptor (NMDA), ganglioside, microtubule-associated protein 2 (MAP-2), neurofilament, and glial fibrillary acidic proteins. The most common autoantibodies in patients with neuropsychiatric lupus however, were anticardiolipin antibodies [1]. Lupus is also strongly associated with defects in apoptotic clearance [10]. Moreover, medications (such as hydralazine, D penicillamine, anti-TNFα inhibitor), hormonal influences (pre-puberty, puberty, pregnancy, menstrual cycle, menopause), and other factors such as sunlight have all been implicated in disease exacerbation [4]. Ultraviolet light is the most well described environmental trigger of systemic lupus erythematosus. Both ultraviolet A2 and ultraviolet B exposure can exacerbate skin disease in patients with the disorder [11]. However, the consequent avoidance of sunlight can lead to vitamin D deficiency, which is inversely related to disease activity [12].

### Mechanism of Disease

Dysregulation of the immune system was found in SLE patients. Multiple autoantibodies that have been implicated in the disease include autoantibody against double-stranded DNA, Ro, La, Sm, NMDA receptor, phospholipid, and α-actinin [4]. The explanations of tissue damage caused by autoantibodies have two major theories. The first theory suggested that anti-double stranded DNA antibodies bind to circulating nucleosomes to form immune complexes that then get

deposited in end-organ capillary beds such as the renal glomerulus and activate immune/inflammatory responses [13]. The second hypothesizes that these autoantibodies cross-react with normal renal proteins causing tissue destruction [14]. The source of autoantigens that trigger the formation of the aforementioned antibodies is thought to arise from apoptotic cells, with phagocytosis by macrophages. Depression of such complement factors is an independent risk factor for the development of SLE [15] Mass production of autoantibodies relies on multiple factors, which have each independently been targeted as a potential immunotherapy in the treatment of lupus. Important steps include T-cell activation via antigen binding to the T-cell receptor and proper co-stimulation; T-cell activation of B-cell; production of cytokines such as TNF- $\alpha$ , TNF- $\gamma$ , IL-10, and B lymphocyte stimulator [4].

During the past few years, several mechanisms have been proposed for a potential role of Neutrophil Extracellular Traps (NETs) in the etio-pathogenesis of SLE. When neutrophils undergo mitosis, histones are highly susceptible to acetylation and methylation of certain residues that were reportedly associated with apoptosis [16-18]. The increased content of acetylated and methylated residues on histones from NETs of SLE patients may, therefore, indirectly increase the immune-stimulatory potential of NETs via an enhanced binding of antimicrobial peptides within the NETs. However, it appears that modified histones themselves are also highly immune-stimulatory [19].

## Epigenetics and Lupus

Pathophysiological mechanisms in SLE involve both genetic and environmental factors. Genome-Wide Association (GWA) screening for several thousand bi-allelic variants in case-control studies has identified over 30 genes involved in SLE [20]. A role for epigenetic dysregulation in the pathogenesis of SLE was suggested more recently [21]. Epigenetics is the study of transmissible and reversible changes in gene expression that are not accompanied with alterations in nucleotide sequences. Epigenetic information is carried chiefly by DNA itself, histones, and noncoding RNAs [22] Epigenetic dysregulation in lupus is related to DNA methylation abnormalities (hypomethylation), biochemical changes in histones (hypoacetylation of the histones H3 and H4 in CD4+ T cells from patients with SLE, as

well as a negative correlation between the level of H3 histone acetylation and disease activity [23] More recent studies showed IL-17A overexpression related to biochemical changes in the histones located near the corresponding locus [24]), and dysregulation of microRNA (especially a role of MiR-146a) [25].

## Autoimmunity and Oxidatively Modified Autoantigens

Reactive oxygen species (ROS) are oxygen-based molecules possessing high chemical reactivity. These include free radicals (superoxide and hydroxyl radicals) and non-radical species (hydrogen peroxide) which can be produced even at basal conditions by a number of ways [26]. In SLE and other diseases, significantly higher 4-hydroxy-2-nenonal-modified protein levels occur in children with lupus. SOD1 activity was decreased in lupus [27]. Malondialdehyde and conjugated dienes were significantly elevated in lupus patients compared to controls. Antibodies to SOD1 were significantly increased in SLE patients and are potentially responsible for the increased oxidative damage seen [27]. Oxidatively modified LDL's have been shown to elicit autoantibodies and oxidant stress has been attributed to the development of anti-phospholipid antibodies. Elevated levels of anti-oxLDL autoantibodies occur in SLE patients [28]. Studies show that anti-oxLDLs positively correlate with antiphospholipid antibodies and anti- $\beta$ -2-glycoprotein. Antibodies to oxLDL that are cross-reactive with phospholipids are thought to be due to binding to oxidized phospholipids. Circulating oxLDL/ $\beta$ -2-glycoprotein complexes and IgG immune complexes containing oxLDL/ $\beta$ -2-glycoprotein occur in SLE and/or phospholipid syndrome [29]. Increased levels of 8-oxo-deoxyguanine (8-oxodG) have been found in lymphocytes from patients with SLE. An investigation of blood monocytes from patients with SLE showed an impairment in the removal of 8-oxodG as a result of a deficient repair system [30].

## Diagnostic Criteria

The latest revision and development of classification criteria for SLE has been the publication of the Systemic Lupus International Collaborating Clinics (SLICC) classification criteria in 2012 [1,31]. This is show in Table 1. Interestingly, ocular manifestations are not part of the criteria.

Clinical criteria
Acute cutaneous lupus, including lupus malar rash, bullous lupus, toxic epidermal necrolysis variant of SLE, maculopapular lupus rash, photosensitive lupus rash, or subacute cutaneous lupus (psoriaform of annular polycyclic lesions, or both)
Chronic cutaneous lupus, including classic discoid rash (localized and generalized), hypertrophic lupus, lupus panniculitis, mucosal lupus, lupus erythematosus tumidus, chilblains lupus, and discoid lupus/lichen planus overlap
Oral ulcers and nasal ulcers
Non-scarring alopecia
Synovitis involving two or more joints and at least 30 minutes of morning stiffness
Serositis
Renal (urine protein to creatinine ratio or 24 hours urine protein) representing 500 mg protein per 24 hours or red blood cell casts.
Neurological: seizures, psychosis, mononeuritis multiplex, myelitis, peripheral and cranial neuropathy, acute confusional state.
Hemolytic anemia
Leukopenia (<4,000 cells per $\mu$ L at least once) or lymphopenia (<1,000 cells per $\mu$ L at least once)
Thrombocytopenia (<100,000 cells per $\mu$ L) at least once
Immunological criteria

Antinuclear antibody concentration greater than laboratory reference range
Antidouble-stranded DNA antibody concentration greater than laboratory reference range (or two fold the reference range if tested by ELISA)
Anti-Sm: presence of antibody to Sm nuclear antigen
Antiphospholipid antibody positivity as determined by any of the following: positive test result for lupus anticoagulant, false-positive test result for rapid plasma-reagin, medium titer or high titer anticardiolipin antibody concentration (IgA, IgG, or IgM), or positive test result for anti-2 glycoprotein I (IgA, IgG, or IgM)
Low complement C3, low C4, low CH50
Direct Coombs' test in the absence of hemolytic anemia

**Table 1:** Clinical and immunological criteria used in the Systemic Lupus Collaborating Clinics (SLICC) classification system.

## Ocular Manifestations

SLE may affect almost any part of the eye and visual pathway. Ocular manifestations include eyelids, orbit, lacrimal system, ocular surface, glaucoma, cataract, uveitis, retinal vasculature, choroid, and cranial nerves [3-5,32]. The most common ocular involvement is dry eye syndrome or keratoconjunctivitis sicca, and the most common vision threatening condition is retinopathy [3-5].

## External eye diseases

**Eyelid disease:** Discoid lupus rash over the eyelids present as discrete raised scaly lesions [5], which are often mistaken for chronic blepharitis and eczema, and may lead to permanent sequelae such as madarosis and cicatricial ectropion. Lupus rash of this site is rare compared to other sun-exposed areas such as the head, the face, and the neck [4]. Histopathologic study shows a hyperkeratotic epithelium with liquefactive degeneration of the basal layer and a dense perivascular/periappendageal lymphocytic infiltration [33,34]. Kopsachilis et al. recommended all patients with chronic blepharitis who do not respond to common therapy should be examined for possible facial lesions, and biopsy with direct immunofluorescence staining should be considered [35]. Direct immunofluorescence (DIF) is used to detect deposits of the immunoglobulins IgG, IgM, and in rare cases, IgA, as well as deposits of the complement component C3 at the dermoepidermal junction [36]. Diagnosis can be made by serological blood test, but only 20% of discoid lupus patients have a positive Anti-Nuclear Antibody titre (ANA) [35]. Other laboratory tests that are recommended to confirm the diagnosis of cutaneous lupus erythematosus despite ANA are Erythrocyte Sedimentation Rate (ESR), C-reactive protein (CRP), complete blood count (CBC), liver enzymes, renal function parameters and urinalysis. Special tests after a histologically confirmed diagnosis of cutaneous lupus erythematosus are serum complement factors C3 and C4, antiphospholipid antibodies, immunoglobulins, rheumatoid factor, thyroid stimulating hormone (TSH) and thyroid antibodies, Venereal Disease Research Laboratory (VDRL), glomerular filtration rate (GFR), 24-hour urine protein, glucose-6-phosphate dehydrogenase activity [36]. Autoantibodies against double-stranded DNA and Sm are in the majority of cases associated with SLE and are not characteristic for any of the cutaneous lupus subtypes [37]. One further possible target of autoantibodies is annexin 1, a significant higher level of anti-annexin 1 antibody was observed in DLE patients, suggesting that anti-annexin 1 antibody might be a new diagnostic marker for DLE [38]. These lesions usually respond well to systemic therapy with hydroxychloroquine 200 mg orally twice per day if started early, but not topical anti-inflammatory therapy [39]. Ultraviolet light avoidance is also recommended [35].

**Lacrimal system disease:** Dry eye syndrome is the most common ocular presentation of SLE, present in approximately 25-35% of the patients, and is often associated with secondary Sjögren's syndrome, which is characterized by lymphocytic infiltration of the exocrine glands [3,40]. Dry eye in SLE patients is mainly caused by a decrease in tear production leading to ocular discomfort, irritation, and burning sensation [3]. Biswas et al identified that the anti-Sjögren's syndrome type B (SSB), the same substance as a cytoplasmic antigen La, namely the SSB/La antigen, was associated with the decreased phagocytic efficiency of neutrophils in patients with SLE [41]. A form of dry eye can be treated with artificial tear drops [5]. Corticosteroid drops are one of the most commonly used drugs for the treatment of any ocular surface inflammation. This treatment prohibits cell adhesion molecule ICAM-1, MMPs, prostaglandin, cytokine, and chemokine production and release, and stimulates lymphocyte apoptosis. Complications of corticosteroid eye drops should be taken into consideration since dry eye is a chronic problem. Therefore, they should be used as an acute phase treatment option in patients who are not relieved by other treatments [42]. The first topical cyclosporine eye drop, Restasis™ 0.05%, received FDA approval in 2002 for the treatment of inflammation in dry eye syndrome. It decreases expression of inflammation markers such as IL-2, IL-17, and IFN- $\alpha$ , which take place in HLA-DR and T-lymphocyte activation on ocular surface tissues of dry eye patients [43]. A decrement in IL-6 and activated lymphocytes, reduction of MMP-9 expression in conjunctival epithelial cells were reported with topical cyclosporine in moderate to severe dry eye patients [44,45]. Cyclosporine eye drop can also increase goblet cell density and immunoregulator TGF- $\beta$ 2 production, decrease in squamous metaplasia, ocular surface restoration with an improvement in corneal sensitivity and inhibition of apoptosis [46-48]. Tetracycline and derivatives act by inhibiting bacterial flora which produces lipolytic exoenzyme and lipase enzyme. They decrease collagenase activity, phospholipase A2 and MMPs activities, and inhibit IL-1 and TNF- $\alpha$  production in corneal epithelium and ocular surface structures. They also decrease lipase activity, regulate meibomian lipids, and decrease MMP-8 levels [49]. Oral tetracycline can be used 250 mg 4 times daily, or as doxycycline or minocycline 100 mg once or twice daily [42]. Autologous serum is rich in epitheliotropic factors, neurotrophin, vitamin A, immunoglobulin, and extracellular matrix proteins. They support epithelial cell proliferation and the normal morphology of corneal epithelial cells with this rich context [42]. In severe dry eye secondary to inflammatory conditions, systemic immunosuppressive agents can be considered [50].

**Orbital disease:** This is a rare condition and can present as orbital mass, periorbital edema, orbital myositis, panniculitis; previously called lupus erythematosus profundus (nodular inflammation of adipose tissue), acute orbital ischemia and infarction [5,51,52]. Clinical

presentation may be ptosis, proptosis, orbital pain, limitation of extraocular movements, and enophthalmos. Histopathologic features of lupus-related vasculitis or panniculitis is characterized by a lymphocytic reaction with a marked number of plasma cells, necrosis, hyalinization of fat and a secondary vasculitis with thickened arterial walls and occlusion. Positive immunofluorescent testing may help in making diagnosis [52]. Immunohistochemical study shows lymphocyte infiltration (OKT4, OKT8 OKT11, and HLA-DR positive cells) and element of the monocyte-macrophage lineage (Leu M3 and Leu M5 positive). Immunofluorescent IgG, IgM, C3 and C4 deposits were found in blood vessel walls of the deep dermis [53]. Treatment is with immunosuppression [5].

### Anterior eye segment manifestations

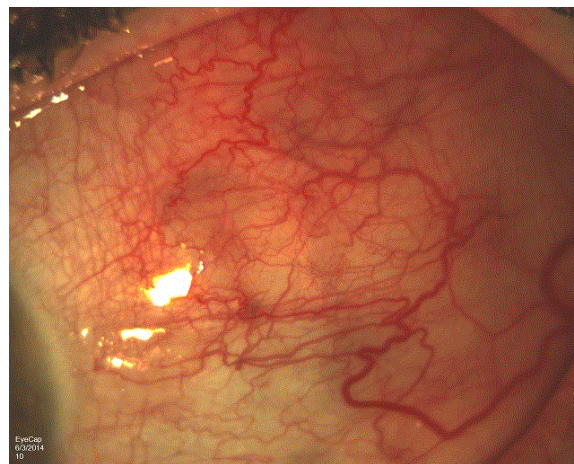
**Conjunctiva:** Chronic conjunctivitis is infrequent [3]. Symblepharon has been reported, especially in association with discoid lupus erythematosus of the eyelids [39]. Immunopathologic studies examining actively inflamed conjunctiva in SLE-associated peripheral ulcerative keratitis, scleritis, and cicatrizing conjunctivitis showed subepithelial and perivascular cellular infiltration and granuloma formation, as well as immune deposits at the epithelial basement membrane and in vessel walls, compatible with an immune complex-mediated disease [54,55]. Nonsteroidal anti-inflammatory agents or antimalarial therapy may be sufficient in relatively mild disease [54].

**Corneal disease:** In addition to dry eye and punctate epithelial erosion, breakdown of corneal epithelium can cause recurrent corneal erosion, and uncommonly, the inflammatory process in SLE can also affect the periltimbal capillary arcades and cause Peripheral Ulcerative Keratitis (PUK), which is rarely associated with necrotizing scleritis, as a result of severe systemic vaso-occlusive disease [54]. Involvement of the deep corneal layers, presented as interstitial keratitis is rarely reported [56]. Treatment strategy for PUK is systemic corticosteroids plus a cytotoxic agent during the acute phase of the disease and lubrication of corneal surface concomitantly. Collagenase inhibitors or collagenase synthetase inhibitors may be of limited benefit in reducing additional stromal ulceration. Topical steroids are not appropriate because these drugs inhibit new collagen production and thereby increase the risk of perforation [57].

**Episclera:** Episcleritis is a benign inflammation of the episclera, usually present with mild, if any, irritation and redness due to injection of the superficial blood vessels [5]. Systemic associations are rare [3]. The incidence in adult patients with SLE has been reported at 2.4% [58]. Treatment options include observation or topical/systemic nonsteroidal anti-inflammatory drugs [4].

**Scleral disease:** Scleritis is a painful, potentially sight threatening disorder and occasionally requires urgent assessment. It is less frequent than episcleritis but it can cause severe ocular morbidity [3]. Anterior scleritis may present as diffuse (Figure 1), nodular, or necrotizing scleritis, which may result in significant destruction, leaving an area of scleral thinning [5]. Redness is caused by injection of deep episcleral vessels. On the other hand, posterior scleritis is usually not associated with redness, because it affects sclera posterior to the equator of the globe. Presenting symptoms are pain and blurry vision, which is commonly caused by exudative retinal detachment, papillitis, and/or cystoid macular edema [4,5]. Prognosis of scleritis depends specifically on the systemic disease with which it is associated. The scleritis associated with SLE usually runs a fairly benign course. Immunosuppression is essential, and treatment usually entails steroid

therapy in combination with immunomodulatory therapy [59]. Tectonic scleral or peripheral corneal grafting may be necessary [60].



**Figure 1:** Active diffuse scleritis of the left eye in SLE patient who has been diagnosed with SLE since 1994 but was developed scleritis in 2012 and had recurrent scleritis in the left eye in 2014 while she was on hydroxychloroquine sulfate 400 mg daily and prednisolone 40 mg daily.

**Anterior uveitis:** SLE is a rare cause of anterior uveitis [3], but Drosos et al. believed that it is not an uncommon manifestation of SLE [32]. Hypopyon uveitis in a SLE patient was also reported in 2005 and prompt systemic immunosuppressive therapy was considered [61].

**Cataract:** The frequency of cataract in SLE patients ranges from 5-32%. It is not only iatrogenic steroid use in SLE that is associated with cataract formation, but also hypertension (especially high systolic blood pressure) and high level of SLE disease activity. The most important risk factor for cataract is the cumulative dose of corticosteroid [62]. In the general population, the relationship between hypertension and cataract has been inconsistent [63,64].

**Glaucoma:** Measuring intra-ocular pressure in SLE patients is challenging; the biomechanical properties of the cornea are altered compared to normal individuals. Intra-ocular pressure readings may be underestimated in SLE eyes [65]. The first report of open angle glaucoma in SLE was believed to be a report in 1971; the author speculated that an inflammatory connective tissue disorder such as SLE had occurred within the aqueous outflow channels and resulted in glaucoma, but this can also have been aggravated by systemic corticosteroid [66]. Not only secondary open angle glaucoma can be found in SLE patients, but also angle closure glaucoma secondary to choroidal effusion or posterior scleritis [67,68].

### Posterior eye segment manifestations

**Retina:** Retinal diseases affect around 10% of SLE patients, reflecting a reduction in frequency associated with improved control of systemic disease [5]. The retinal signs often parallel the severity of systemic inflammation, and may indicate control of the systemic disease [69,70].

**SLE retinopathy:** There is a strong correlation between presence of retinopathy and central nervous system disease such as cerebrovascular attacks, dementia, seizure, chorea, and transverse

myelopathy [71-73]. Mild retinopathy may be asymptomatic but more severe disease may cause loss of vision, field defects, distortion or floaters [5]. The earliest findings are small intraretinal hemorrhages and cotton wool spots [74]. This may resemble Purtscher-like retinopathy with characteristic of multiple areas of polygonal retinal whitening between the retinal arterioles and venules, usually accompanied by superficial cotton wool spots at the posterior pole [73].

The pathogenesis is characterized by the activation of immune cells and various cytokines, as well as the production of auto-antibodies and immune complex [75]. Fluorescein angiogram may show multifocal areas of capillary non-perfusion, supporting the theory of microembolization in Purtscher-like retinopathy. Complement activation does not appear to be a sufficient condition for the development of Purtscher-like retinopathy. Capillary endothelial damage and hyperviscosity have also been suggested to play roles in Purtscher-like retinopathy [73]. In the majority of cases, prognosis is excellent, but severe vaso-occlusive retinopathy often results in poor visual and systemic prognosis [76]. Proliferative retinopathy may occur in up to 72% of such cases, often with ensuing vitreous hemorrhage, retinal traction and retinal detachment [5].

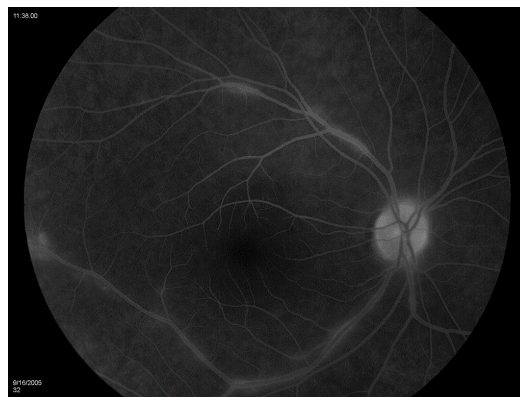Systemic therapy with steroid is required when severe manifestations are presented, initial treatment is usually with oral corticosteroids (e.g. prednisolone 1 mg/kg/day), but may be preceded by intravenous methylprednisolone [5,77]. Immunosuppression has been successful in improving the appearance of the retinopathy; however, visual recovery has only been reported in few cases. The permanent loss of visual acuity is likely due to retinal ischemia [4]. Laser therapy, intravitreal anti-vascular endothelial growth factor agents (anti-VEGF), and vitrectomy may also be considered for the treatment of complications of ocular ischemia [4,76]. Anticoagulation also has a role in addition to acetylsalicylic acid particularly when antiphospholipid antibodies are presented (5). Other therapies include plasmapheresis and plasma exchange have been reported, rapidly remove circulating immune complexes proposed but have limited success [78,79].

**Hypertensive retinopathy:** SLE patients are at risk for arterial hypertension. Many etiologies are involved such as increase in vascular stiffness due to endothelial dysfunction and atherosclerosis or renal disease, and secondary to medication such as cyclosporine and glucocorticoids [80,81]. Hypertensive retinopathy is a result of occlusion of retinal arterioles and consequent retinal infarction [5]. Proper medical management to control blood pressure and underlying SLE is the mainstay of the therapy.

**Retinal vein occlusion and/or retinal artery occlusion:** This is a rare form of retinal vascular disease that is often associated with poor visual prognosis [82]. There is an elevated risk for patients with SLE to develop retinal vascular occlusion [83]. In patients with both SLE and antiphospholipid antibodies, the pathogenesis of severe vaso-occlusive retinopathy is attributed to thrombosis associated with antiphospholipid syndrome, rather than the immune complex mediated vasculitis related to SLE [84]. Isolated retinal vein occlusion, retinal artery occlusion, or combine retinal artery and vein occlusion have been reported [82,85,86]. More details about role of antiphospholipid syndrome related to ocular manifestations will discuss later in this article.

**Retinal vasculitis:** Severe retinal vasculitis is a rare, but potentially blinding, complication of patients with SLE [87] (Figure 2). Treatment

of this retinal manifestation is the treatment of the systemic disease [88].



**Figure 2:** Fundus angiography of the right eye with retinal periphlebitis and papillitis in 38 year-old female with presumed antiphospholipid syndrome and SLE.

**Choroid:** Choroidal disease is less common than retinopathy [5]. Although it is rare, it is considered a sensitive indicator of systemic disease activity [89]. Choroidopathy with exudative retinal detachment is a rare ocular manifestation [4]. It is typically manifest as multifocal serous detachments of the Retinal Pigment Epithelium (RPE) and neural retina, with the transduction of the accumulated fluid through Bruch's membrane and RPE affected by the choroidal ischemia and inflammation.

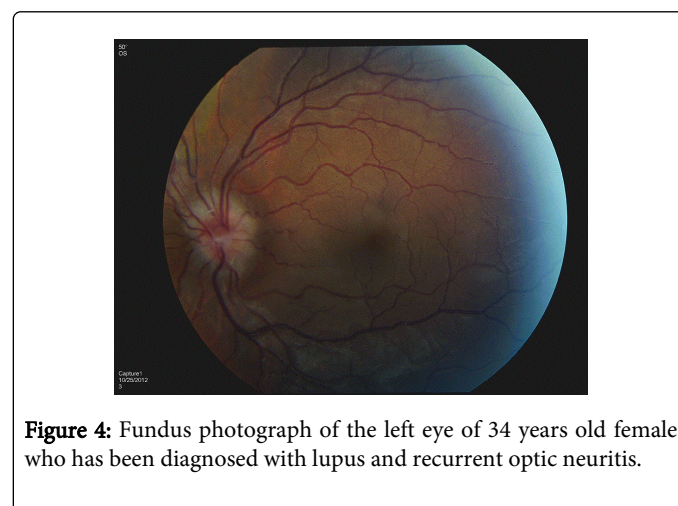
The presenting symptom is visual loss, which depends on the extent of macular involvement [3,90]. Indocyanine Green (ICG) geographic finding, often demonstrates disease not detectable on examination [5], shows early focal areas of transient choroidal ICG hypofluorescence suggest choroidal filling delay (Figure 3). Pinpoint spots of ICG choroidal hyperfluorescence appearing from the intermediate to late phases, may indicate ICG staining with localized abnormal fixing of the ICG molecule. They may represent immune deposits at the level of choroidal stroma, Bruch membrane or retinal pigment epithelial basement membrane that contain immunoglobulins and leukocytes which have been shown to bind the ICG molecule [89].

Histopathologic studies have shown the existence of inflammatory cells, immunoglobulin, and complement in choroidal vessels [91,92]. Lupus choroidopathy has been shown to be responsive to corticosteroids and other forms of immunosuppression [4]. Focal laser and Photodynamic Therapy (PDT) have been shown to be quite effective for central serous choroidopathy when systemic immunosuppression and control of systemic disease is insufficient for resolution of choroidopathy, and should be considered in the early course of the disease [92].

Pulse methylprednisolone and cyclophosphamide have been reported to be effective in treating bilateral exudative retinal detachment secondary to ischemic choroidopathy [93]. In rare circumstance, Serpiginous like choroidopathy and polypoidal choroidal vasculopathy in SLE patients have been reported [94,95].

### Neuro-ophthalmic manifestations

**Optic nerve:** Optic nerve disease is a rare manifestation of SLE and consists of optic neuritis (Figure 4) and ischemic optic neuropathy [98]. The optic nerve damage is believed to be secondary to an occlusive vasculitis of the small arterioles of the nerve, which leads to demyelination and/or axonal necrosis [99,100]. Signs of optic nerve disease include reduced visual acuity, impairment of color vision, diminished light brightness sensitivity, decreased contrast sensitivity, afferent pupillary defect and visual field defects. Fundoscopy discloses a swollen disc except in the case of retrobulbar neuritis that is characterized by a normal appearing optic disc; optic atrophy also is seen [3]. Optic neuritis response very well to high dose corticosteroid treatment [101]. Treatment for lupus optic neuropathy is also with high dose corticosteroid but followed by an extended oral taper. Immunosuppressive agents have shown success in some studies [4]. Visual prognosis following optic neuropathy is generally poor [5].

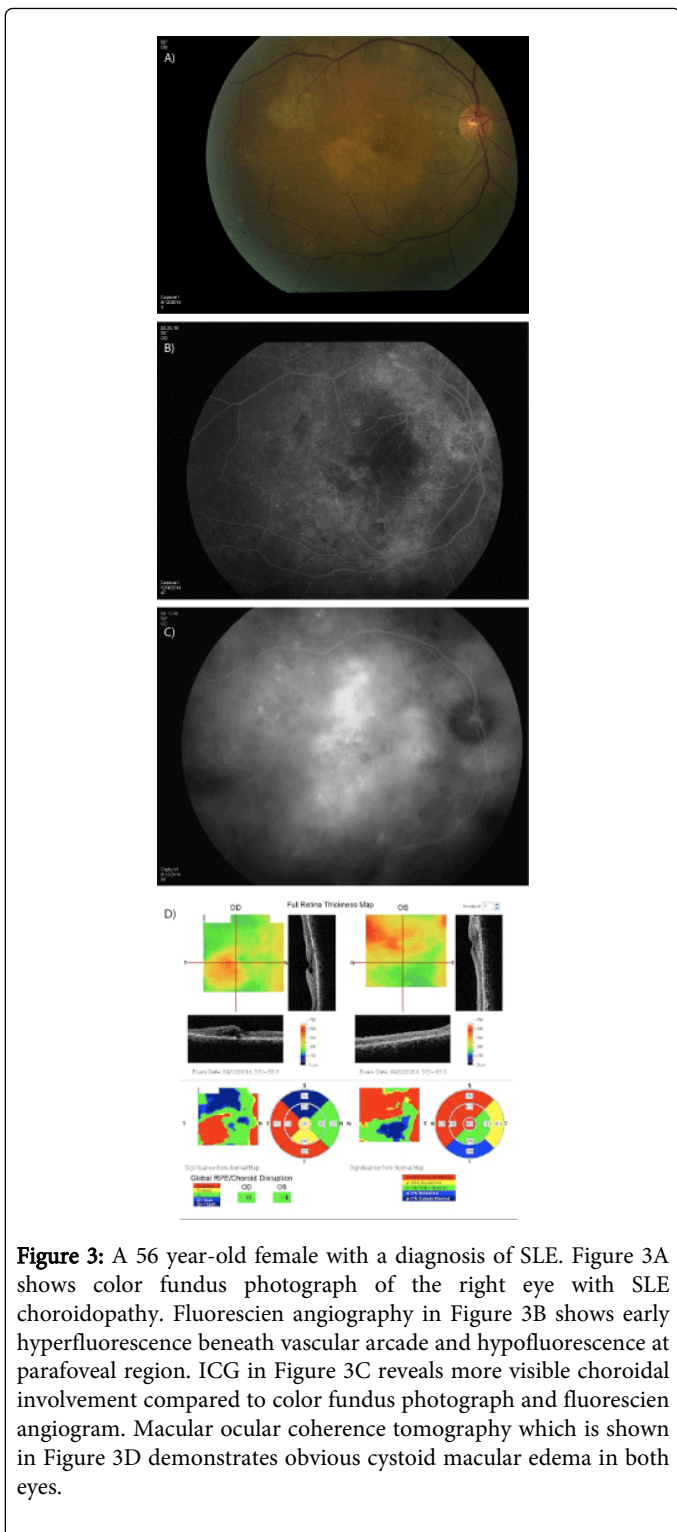


**Figure 4:** Fundus photograph of the left eye of 34 years old female who has been diagnosed with lupus and recurrent optic neuritis.

**Cranial nerve involvement:** Eye movement abnormalities are common such as ocular motor nerve palsy and internuclear ophthalmoplegia. Ischemic microvascular disease of the brainstem is usually the etiology [4]. Lesions of the posterior visual pathway and retrochiasmal lesions are relatively rare but have been previously reported [100,102,103]. Patients can be presented with visual hallucination, nystagmus and cortical blindness [4]. Pupillary abnormalities such as light-near dissociation, Horner's syndrome, Adie's pupil have also been reported [5]. Other neuro-ophthalmic manifestations of SLE also include idiopathic intracranial hypertension, Miller-Fisher syndrome and Devic's syndrome (neuromyelitis optica) [3].

### Role of Antiphospholipid Syndrome

Risk of developing ocular occlusive vascular disease is higher in the patients with SLE and positive circulating antiphospholipid antibodies (aPL). Retinopathy including arterial and venous occlusion, cotton-wool spots, optic disk edema and hemorrhages reported to be higher among SLE patients in the presence of aPL compared with SLE patients who has negative antibody against aPL [104]. Similar ocular and neuro-ophthalmic manifestations also reported in both primary and secondary anti-phospholipid syndrome (APS) [8]. Anti-phospholipid syndrome is an autoimmune disease defined by presence of anti-phospholipid antibodies and with one the following clinical manifestation, venous and or arterial thrombosis and repetitive fetal



**Figure 3:** A 56 year-old female with a diagnosis of SLE. Figure 3A shows color fundus photograph of the right eye with SLE choroidopathy. Fluorescein angiography in Figure 3B shows early hyperfluorescence beneath vascular arcade and hypofluorescence at parafoveal region. ICG in Figure 3C reveals more visible choroidal involvement compared to color fundus photograph and fluorescein angiogram. Macular ocular coherence tomography which is shown in Figure 3D demonstrates obvious cystoid macular edema in both eyes.

**Macula:** Maculopathy can be related to chloroquine toxicity, which is widely used in SLE patients [96]. Macular infarction has been reported as an uncommon complication of vasculitis associated with SLE [97].

loss. Primary APS is diagnosed when no underlying disease is recognized whereas secondary APS occurs when the disease develops in the context of another autoimmune disease like systemic lupus erythematosus.

Although the definite mechanism has not been discovered yet, the presence of autoantibodies including lupus anticoagulant, anti-cardiolipin antibody or anti- $\beta$ 2 glycoprotein-1 antibody might play a role in causing hemostasis shift to pro-thrombotic state leading to arterial and venous thrombosis [105]. Pro-inflammatory cytokines and endothelin-1 (ET-1, an endothelium-derived contracting factor) might also be contributive factors in developing hypercoagulable condition in APS [106,107].

Ocular manifestation of APS syndrome includes anterior eye segment, posterior eye segment and neuroophthalmic changes. Anterior segment manifestations include telangiectasia, microaneurysm, dry eye, episcleritis, scleritis, uveitis, keratitis and diplopia [108]. Unilateral and bilateral vascular retinal thrombosis is most prominent posterior segment ocular manifestation in both primary and secondary APS [109]. As mentioned before SLE patient with retinal vascular thrombosis reported to have higher level of aPL. These patients tend to develop central or branch artery and vein occlusion or with extensive retinal capillary non-perfusion complications including neovascularization, vitreous hemorrhage and tractional retinal detachment. Retinal vasculitis, vitritis, posterior scleritis and central retinal artery occlusion also reported with higher prevalence in aPL positive patients [110-113]. APS associated neuro-ophthalmic changes are probably related to blood supply hazard and optic nerve demyelization and include anterior non-arterial ischemic neuropathy (NAION), retro-bulbar neuritis and orbital ischemic syndrome on catastrophic APS [114,115].

In general the presence of aPL in SLE patients is associated with focal thrombotic events that prompt use of anticoagulants adding to immunosuppressive. APS patients with no anticoagulation treatment are generally at higher risk for recurrent thrombosis. Anticoagulation with heparin administration followed by anticoagulant therapy (Warfarin, etc.) to keep INR >3 are recommended therapy of venous thrombosis [116]. Pan-retinal argon laser photocoagulation may also be used in cases of retinal venous thrombosis and presence of neovascularization, aiming at prevention of both new thrombosis and its complications.

## Drug Related Ocular Manifestation

Drug-induced lupus erythematosus is a lupus-like syndrome related to continuous drug exposure and resolves after discontinuation of the offending drug. Ocular complications are rare in drug-induced lupus. Episcleritis reported as an ocular manifestation of drug induced lupus in patients treated with Infliximab [117]. Retinal vasculitis and occlusive disease as a consequence of hydralazine and procainamide have been also reported [5].

Agents used in treating SLE can be potentially harmful to the eyes. Corticosteroids are commonly used in SLE and may cause cataract formation and steroid induced hypertension and glaucoma. A corticosteroid-induced increased intra-ocular hypertension occurs in both systemic and topical steroid administration but is most commonly identified as a complication of topical corticosteroid. Risk factors include age, history of glaucoma or glaucoma suspect, first-degree relative with primary open angle glaucoma, high myopia,

previous steroid response, type I diabetes and history of connective tissue disease (eg. rheumatoid arthritis) [118].

Ideally, patients requiring long-term systemic corticosteroid therapy should have glaucoma screening and those receiving 10 mg or more of prednisolone daily should have their intra-ocular pressure checked at 1, 3, and 6 months and 6 monthly thereafter [119]. If glaucoma is established or progressed, corticosteroid should be stopped. The chronic corticosteroid response usually resolves in 1-4 weeks. The management of irreversible steroid induced glaucoma is similar to management of Primary open angle glaucoma (POAG). Medical management includes topical beta-blockers, prostaglandin analogues, alpha agonists and oral carbonic anhydrase inhibitors. Filtration surgery or trabeculectomy are the surgical options for the patient with persistent raised intra-ocular pressure following cessation of corticosteroid and refractory to medical therapy.

Chloroquine (CQ) and Hydroxychloroquine (HCQ) potentially can cause serious retinal toxicity if high dose given over a long period of time. Corneal epithelial deposits (vortex keratopathy, verticillata) may develop in patients taking chloroquine, but very rarely impair the vision [120]. The retinal drug adverse effects include asymptomatic mild macular pigmentary changes, persistent paracentral and central visual field scotoma, color vision impairment and most typically paracentral depigmentation surrounding the center of vision, called bull's-eye maculopathy. Loss of visual sensitivity can be detected even before fundus exam changes, by careful testing of para-central vision. Widespread retinal pigment epithelium and optic nerve atrophy may progress in long-term drug exposure and can persist even after cessation of the drug [120].

The incidences of toxicity however in clinical practice are very small. Among 150,000 people who had taken hydroxychloroquine in the USA between 1960 and 2005, only 47 cases reported to develop hydroxychloroquine retinopathy [121]. The vast majority of reports of toxicity have occurred in individuals taking 6.5 mg/kg/day of HCQ or 3 mg/kg/day of CQ, for 5 years. Maintenance dose below this level is suggested if possible.

According to American Academy of Ophthalmology, screening by an ophthalmologist is recommended for those patients on hydroxychloroquine who are at higher risk: dose >6.5 mg/kg/day, duration of treatment >5 years and high risk patient with renal or hepatic disease, pre-existing retinal disease or age >60 years. New screening guideline is now recommending to perform fundus examinations with 10-2 automated fields and at least one objective test including multifocal electroretinogram, fundus autofluorescence or spectral domain optical coherence tomography (SD-OCT). A baseline examination along with annual screening should be initiated no later than 5 years after starting hydroxychloroquine therapy [122].

Ocular manifestations in SLE, pathology and treatment are summarized in Table 2.

## New Treatment Modalities

The drugs commonly used in SLE are hydroxychloroquine and NSAIDs for mild disease activity/flare of malar rash, arthralgia and fatigue. For moderate activity with arthritis, pleuritic, pericarditis, crops of mouth ulcers, rash up to two-ninths body surface area, early renal involvement; recommended treatments are corticosteroid alone or corticosteroid plus azathioprine or methotrexate or mycophenolate mofetil. For severe disease activity without renal involvement, which

are rash involving more than two-ninths body surface area, severe pleuritis, pericarditis, and cerebral features; higher dose of corticosteroid (orally or intravenously) plus mycophenolate mofetil or B-cell depletion or cyclophosphamide are recommended. Once there

is renal involvement, which is presented with increased blood pressure, edema, and active urine sediment; corticosteroid with Euro-Lupus intravenous cyclophosphamide or mycophenolate mofetil or B-cell depletion are indicated [1].

Location		Disease	Pathophysiology	Medication(s) other than systemic steroid and IMT	References
Extraocular	Eyelids	Discoid lupus	Hyperkeratotic epithelium/ degeneration of basal layer/ perivascular lymphocytic infiltration	Antimalarial therapy	[11-14]
	Orbit	Periorbital edema/orbital masses/ orbital myositis/panniculitis/orbital ischemia	Lymphocytic reaction, secondary vasculitis	-	[17,18]
	Lacrimal system	Dry eye syndrome ± secondary Sjögren syndrome	Lymphocytic infiltration of the exocrine glands	Artificial tears, topical corticosteroid, topical cyclosporine, tetracycline derivatives	[15,16]
Anterior eye segment	Conjunctiva	Conjunctivitis/syblepharon	Subepithelial and perivascular cellular infiltrate, granuloma formation, immunodeposits	Systemic NSAID, Antimalarial therapy	[14,19,20]
	Cornea	Punctate epithelial erosion/recurrent corneal erosion/PUK/IK	Immune complex deposition, vaso-occlusion	Artificial tears, Collagenase synthetase inhibitor	[19,21,22]
	Episclera	Episcleritis	Topical/systemic NSAID	-	[23]
	Sclera	Scleritis		Systemic NSAID	[24,25]
	Iris/ciliary body	Anterior uveitis	Topical steroid, Topical cycloplegic		[10,26]
	Posterior eye segment	Retina/macula	SLE retinopathy/hypertensive retinopathy/retinal vascular occlusion/retinal vasculitis/ maculopathy/macular ischemia	Activation of immune cells and cytokines, capillary endothelial damage, hyperviscosity	Anti-VEGF, ASA, anticoagulant
Choroid		Choroidopathy/PCV	Inflammatory cells, Ig, complement in choroidal vessel	-	[54-60]
Optic nerve		Optic neuritis/ischemic optic neuropathy	Occlusive vasculitis, demyelination, axonal necrosis	-	[63-66]
Others	Pupil	Light-near dissociation/Horner's syndrome/Adie's pupil/	Ischemic microvascular disease	-	-
	Lens	Cataract	Steroid and other unknown mechanism	-	[27]
	Glaucoma	Open angle glaucoma/secondary angle closure glaucoma/steroid induced glaucoma	Multiple mechanism	Anti-glaucoma medication	[30-33]
	Cranial nerve and posterior visual pathway	Ocular motor nerve palsy/ internuclear ophthalmoplegia/one and a half syndrome/visual hallucination/nystagmus/cortical blindness/Miller-Fisher syndrome/ Devic's syndrome	Ischemic microvascular disease	-	[65,67,68]

**Table 2:** Ocular manifestations in SLE.

Patients who do not respond to conventional immunosuppressive drugs are considered for targeted biological therapies aimed at cytokines, B and T lymphocytes, and B-cell activating factors. These medications are rituximab (a chimeric monoclonal IgG1 antibody to

CD20), belimumab (a monoclonal human antibody that inactivate BlyS or B-cell activating factor, BAFF), atacicept (blocks the interaction between BlyS and a proliferation-inducing ligand (APRIL) and their receptors), epratuzumab (a humanized anti-CD22 IgG1



monoclonal antibody), abatacept (a biological drug that blocks T-cell co-stimulation), sifalimumab (a human anti-interferon  $\alpha$  monoclonal antibody, binds and neutralizes most interferon  $\alpha$  subtypes). (1) Other anti-interferon  $\alpha$  molecules that have been going through testing in phase 2 studies are rontalizumab, AGS-009, MEDI-546 and interferon  $\alpha$  kinoid [123].

## Conclusion

SLE is a chronic, relapsing autoimmune connective tissue disease, primarily affecting skin, joints, kidneys, heart, lungs, nervous system, blood elements, and serosal membranes [6]. Eyes are not the main organ affected in SLE, but once it gets involved, it can lead to permanent eye damage and blindness. Many ocular complications and disease deterioration are preventable, treatable, or even curable, thus inter-department collaboration is highly important. Prompt treatment with high dose systemic corticosteroid and immunosuppressive therapy are necessary in many circumstances. Ocular complications should be aware of, and proper evaluation by ophthalmologists is essential.

## Acknowledgement

The authors are thankful to Jamie L Metzinger and Janine Preble for providing the necessary facilities for the preparation of the paper.

## References

1. Lisnevskaja L, Murphy G, Isenberg D (2014) Systemic lupus erythematosus. *Lancet* 384: 1878-1888.
2. D'Cruz DP, Khamashta MA, Hughes GR (2007) Systemic lupus erythematosus. *Lancet* 369: 587-596.
3. Peponis V, Kyttaris VC, Tyradellis C, Vergados I, Sitaras NM (2006) Ocular manifestations of systemic lupus erythematosus: a clinical review. *Lupus* 15: 3-12.
4. Palejwala NV, Walia HS, Yeh S (2012) Ocular manifestations of systemic lupus erythematosus: a review of the literature. *Autoimmune Dis* 2012: 290898.
5. Sivaraj RR, Durrani OM, Denniston AK, Murray PI, Gordon C (2007) Ocular manifestations of systemic lupus erythematosus. *Rheumatology (Oxford)* 46: 1757-1762.
6. Merrill JT, Buyon JP, Utset T (2014) A 2014 update on the management of patients with systemic lupus erythematosus. *Semin Arthritis Rheum* 44: e1-2.
7. Karpik AG, Schwartz MM, Dickey LE, Streeten BW, Roberts JL (1985) Ocular immune reactants in patients dying with systemic lupus erythematosus. *Clin Immunol Immunopathol* 35: 295-312.
8. Suvajac G, Stojanovich L, Milenkovich S (2007) Ocular manifestations in antiphospholipid syndrome. *Autoimmun Rev* 6: 409-414.
9. Pradhan V, Patwardhan M, Rajadhyaksha A, Dhawale N, Ghosh K (2014) Neuropsychiatric manifestations and associated autoantibodies in systemic lupus erythematosus patients from Western India. *Rheumatology international*.
10. Shao WH, Cohen PL (2011) Disturbances of apoptotic cell clearance in systemic lupus erythematosus. *Arthritis Res Ther* 13: 202.
11. Zandman-Goddard G, Solomon M, Rosman Z, Peeva E, Shoenfeld Y (2012) Environment and lupus-related diseases. *Lupus* 21: 241-250.
12. Kamen D, Aranow C (2008) Vitamin D in systemic lupus erythematosus. *Curr Opin Rheumatol* 20: 532-537.
13. Berden JH, Licht R, van Bruggen MC, Tax WJ (1999) Role of nucleosomes for induction and glomerular binding of autoantibodies in lupus nephritis. *Curr Opin Nephrol Hypertens* 8: 299-306.
14. Michaud JL, Lemieux LI, Dube M, Vanderhyden BC, Robertson SJ, et al. (2003) Focal and segmental glomerulosclerosis in mice with podocyte-specific expression of mutant alpha-actinin-4. *JASN* 14: 1200-11.
15. Walport MJ (2002) Complement and systemic lupus erythematosus. *Arthritis Res* 4 Suppl 3: S279-293.
16. Dieker JW, Franssen JH, van Bavel CC, Briand JP, Jacobs CW, et al. (2007) Apoptosis-induced acetylation of histones is pathogenic in systemic lupus erythematosus. *Arthritis Rheum* 56: 1921-33.
17. van Bavel CC, Dieker J, Muller S, Briand JP, Monestier M, et al. (2009) Apoptosis-associated acetylation on histone H2B is an epitope for lupus autoantibodies. *Mol Immunol* 47: 511-6.
18. van Bavel CC, Dieker JW, Kroeze Y, Tamboer WP, Voll R, et al. (2011) Apoptosis-induced histone H3 methylation is targeted by autoantibodies in systemic lupus erythematosus. *Ann Rheum Dis* 70: 201-207.
19. Pieterse E, Hofstra J, Berden J, Herrmann M, Dieker J, et al. (2015) Acetylated histones contribute to the immunostimulatory potential of neutrophil extracellular traps in systemic lupus erythematosus. *Clinical and experimental immunology* 179: 68-74.
20. Sestak AL, Furrnrohr BG, Harley JB, Merrill JT, Namjou B (2011) The genetics of systemic lupus erythematosus and implications for targeted therapy. *Ann Rheum Dis* 70 Suppl 1: i37-43.
21. Zouali M (2011) Epigenetics in lupus. *Ann N Y Acad Sci* 1217: 154-165.
22. Miceli-Richard C (2015) Epigenetics and lupus. *Joint Bone Spine* 82: 90-93.
23. Hu N, Qiu X, Luo Y, Yuan J, Li Y, et al. (2008) Abnormal histone modification patterns in lupus CD4+ T cells. *J Rheumatol* 35: 804-810.
24. Hedrich CM, Rauen T, Kis-Toth K, Kyttaris VC, Tsokos GC (2012) cAMP-responsive element modulator alpha (CREM $\alpha$ ) suppresses IL-17F protein expression in T lymphocytes from patients with systemic lupus erythematosus (SLE). *The Journal of biological chemistry* 287: 4715-25.
25. Lofgren SE, Frostegard J, Truedsson L, Pons-Estel BA, D'Alfonso S, et al. (2012) Genetic association of miRNA-146a with systemic lupus erythematosus in Europeans through decreased expression of the gene. *Genes and immunity* 13: 268-74.
26. Kurien BT, Scofield RH (2008) Autoimmunity and oxidatively modified autoantigens. *Autoimmun Rev* 7: 567-573.
27. Kurien BT, Scofield RH (2003) Free radical mediated peroxidative damage in systemic lupus erythematosus. *Life Sci* 73: 1655-1666.
28. Craig WY (1995) Autoantibodies against oxidized low density lipoprotein: a review of clinical findings and assay methodology. *J Clin Lab Anal* 9: 70-74.
29. Matsuura E, Lopez LR (2004) Are oxidized LDL/beta2-glycoprotein I complexes pathogenic antigens in autoimmune-mediated atherosclerosis? *Clinical and developmental immunology* 11: 103-11.
30. Kurien BT, Scofield RH (2006) Lipid peroxidation in systemic lupus erythematosus. *Indian J Exp Biol* 44: 349-356.
31. Petri M, Orbai AM, Alarcon GS, Gordon C, Merrill JT, et al. (2012) Derivation and validation of the Systemic Lupus International Collaborating Clinics classification criteria for systemic lupus erythematosus. *Arthritis Rheum* 64: 2677-86.
32. Drosos AA, Petris CA, Petroutsos GM, Moutsopoulos HM (1989) Unusual eye manifestations in systemic lupus erythematosus patients. *Clin Rheumatol* 8: 49-53.
33. Donzis PB, Insler MS, Buntin DM, Gately LE (1984) Discoid lupus erythematosus involving the eyelids. *Am J Ophthalmol* 98: 32-36.
34. Huey C, Jakobiec FA, Iwamoto T, Kennedy R, Farmer ER, et al. (1983) Discoid lupus erythematosus of the eyelids. *Ophthalmology* 90: 1389-1398.
35. Kopsachilis N, Tsaousis KT, Tourtas T, Tsinopoulos IT (2013) Severe chronic blepharitis and scarring ectropion associated with discoid lupus erythematosus. Clinical and experimental optometry: *Journal of the Australian Optometrical Association* 96: 124-5.
36. Kuhn A, Landmann A (2014) The classification and diagnosis of cutaneous lupus erythematosus. *J Autoimmun* 48-49: 14-9.

37. Sticherling M, Bonsmann G, Kuhn A (2008) Diagnostic approach and treatment of cutaneous lupus erythematosus. *J Dtsch Dermatol Ges* 6: 48-59.
38. Kretz CC, Norpo M, Abeler-Dörner L, Linke B, Haust M, et al. (2010) Anti-annexin I antibodies: a new diagnostic marker in the serum of patients with discoid lupus erythematosus. *Exp Dermatol* 19: 919-921.
39. Pandhi D, Singal A, Rohtagi J (2006) Eyelid involvement in disseminated chronic cutaneous lupus erythematosus. *Indian J Dermatol Venereol Leprol* 72: 370-2.
40. Jensen JL, Bergem HO, Gilboe IM, Husby G, Axell T (1999) Oral and ocular sicca symptoms and findings are prevalent in systemic lupus erythematosus. *Journal of oral pathology and medicine* 28: 317-22.
41. Biswas D, Mathias A, Dayal R, Aggarwal A, Misra R, et al. (2008) Presence of antibodies to SSB/La is associated with decreased phagocytic efficiency of neutrophils in patients with systemic lupus erythematosus. *Clin Rheumatol* 27: 717-22.
42. Yagci A, Gurdal C (2014) The role and treatment of inflammation in dry eye disease. *Int Ophthalmol* 34: 1291-1301.
43. Alves M, Fonseca EC, Alves MF, Malki LT, Arruda GV, et al. (2013) Dry eye disease treatment: a systematic review of published trials and a critical appraisal of therapeutic strategies. *Ocul Surf* 11: 181-192.
44. Turner K, Pflugfelder SC, Ji Z, Feuer WJ, Stern M, et al. (2000) Interleukin-6 levels in the conjunctival epithelium of patients with dry eye disease treated with cyclosporine ophthalmic emulsion. *Cornea* 19: 492-6.
45. Gürdal C, Genç I, Saraç O, Gönül I, Takmaz T, et al. (2010) Topical cyclosporine in thyroid orbitopathy-related dry eye: clinical findings, conjunctival epithelial apoptosis, and MMP-9 expression. *Curr Eye Res* 35: 771-7.
46. Pflugfelder SC, De Paiva CS, Villarreal AL, Stern ME (2008) Effects of sequential artificial tear and cyclosporine emulsion therapy on conjunctival goblet cell density and transforming growth factor-beta2 production. *Cornea* 27: 64-9.
47. Kunert KS, Tisdale AS, Gipson IK (2002) Goblet cell numbers and epithelial proliferation in the conjunctiva of patients with dry eye syndrome treated with cyclosporine. *Arch Ophthalmol* 120: 330-337.
48. Brignole F, Pisella PJ, De Saint Jean M, Goldschild M, Goguel A, et al. (2001) Flow cytometric analysis of inflammatory markers in KCS: 6-month treatment with topical cyclosporin A. *Investigative ophthalmology and visual science* 42: 90-5.
49. Solomon A, Rosenblatt M, Li DQ, Liu Z, Monroy D, et al. (2000) Doxycycline inhibition of interleukin-1 in the corneal epithelium. *Invest Ophthalmol Vis Sci* 41: 2544-2557.
50. Cordero-Coma M, Anzaar F, Sobrin L, Foster CS (2007) Systemic immunomodulatory therapy in severe dry eye secondary to inflammation. *Ocul Immunol Inflamm* 15: 99-104.
51. Ohsie LH, Murchison AP, Wojno TH (2012) Lupus erythematosus profundus masquerading as idiopathic orbital inflammatory syndrome. *Orbit* 31: 181-183.
52. Arthurs BP, Khalil MK, Chagnon F, Lindley SK, Anderson DP, et al. (1999) Orbital infarction and melting in a patient with systemic lupus erythematosus. *Ophthalmology* 106: 2387-2390.
53. Ricciari V, Sili Scavalli A, Spadaro A, Taccari E, Zoppini A (1994) Lupus erythematosus panniculitis: an immunohistochemical study. *Clin Rheumatol* 13: 641-644.
54. Messmer EM, Foster CS (1999) Vasculitic peripheral ulcerative keratitis. *Surv Ophthalmol* 43: 379-396.
55. Heiligenhaus A, Dutt JE, Foster CS (1996) Histology and immunopathology of systemic lupus erythematosus affecting the conjunctiva. *Eye (Lond)* 10: 425-432.
56. Adan CB, Trevisani VF, Vasconcellos M, de Freitas D, de Souza LB, et al. (2004) Bilateral deep keratitis caused by systemic lupus erythematosus. *Cornea* 23: 207-209.
57. Yagci A (2012) Update on peripheral ulcerative keratitis. *Clin Ophthalmol* 6: 747-754.
58. Sitaula R, Shah DN, Singh D (2011) The spectrum of ocular involvement in systemic lupus erythematosus in a tertiary eye care center in Nepal. *Ocul Immunol Inflamm* 19: 422-425.
59. Young S (2005) Ocular involvement in connective tissue disorders. *Curr Allergy Asthma Rep* 5: 323-326.
60. Nguyen QD, Foster CS (1999) Scleral patch graft in the management of necrotizing scleritis. *Int Ophthalmol Clin* 39: 109-131.
61. Zink JM, Singh-Parikshak R, Johnson CS, Zacks DN (2005) Hypopyon uveitis associated with systemic lupus erythematosus and antiphospholipid antibody syndrome. *Graefes Arch Clin Exp Ophthalmol* 243: 386-8.
62. Alderaan K, Sekicki V, Magder LS, Petri M (2015) Risk factors for cataracts in systemic lupus erythematosus (SLE). *Rheumatol Int* 35: 701-708.
63. Schaumberg DA, Glynn RJ, Christen WG, Ajani UA, Stürmer T, et al. (2001) A prospective study of blood pressure and risk of cataract in men. *Ann Epidemiol* 11: 104-110.
64. Richter GM, Torres M, Choudhury F, Azen SP, Varma R, et al. (2012) Risk factors for cortical, nuclear, posterior subcapsular, and mixed lens opacities: the Los Angeles Latino Eye Study. *Ophthalmology* 119: 547-54.
65. Yazici AT, Kara N, Yüksel K, Altinkaynak H, Baz O, et al. (2011) The biomechanical properties of the cornea in patients with systemic lupus erythematosus. *Eye (Lond)* 25: 1005-1009.
66. Brock-Utne JG, Good CJ (1971) Glaucoma and systemic lupus erythematosus. *Br Med J* 4: 747.
67. Wisotsky BJ, Magat-Gordon CB, Puklin JE (1998) Angle-closure glaucoma as an initial presentation of systemic lupus erythematosus. *Ophthalmology* 105: 1170-1172.
68. Wagemans MA, Bos PJ (1989) Angle-closure glaucoma in a patient with systemic lupus erythematosus. *Doc Ophthalmol* 72: 201-207.
69. Gold DH, Morris DA, Henkind P (1972) Ocular findings in systemic lupus erythematosus. *Br J Ophthalmol* 56: 800-804.
70. Arevalo JF, Lowder CY, Muci-Mendoza R (2002) Ocular manifestations of systemic lupus erythematosus. *Curr Opin Ophthalmol* 13: 404-410.
71. Stafford-Brady FJ, Urowitz MB, Gladman DD, Easterbrook M (1988) Lupus retinopathy. Patterns, associations, and prognosis. *Arthritis Rheum* 31: 1105-1110.
72. Ostovan VR, Ghorbani A (2013) Chorea and retinal vessel occlusion in a patient with systemic lupus erythematosus. *Iran J Neurol* 12: 66-8.
73. Wu C, Dai R, Dong F, Wang Q (2014) Purtscher-like retinopathy in systemic lupus erythematosus. *Am J Ophthalmol* 158: 1335-1341.
74. Ushiyama O, Ushiyama K, Koarada S, Tada Y, Suzuki N, et al. (2000) Retinal disease in patients with systemic lupus erythematosus. *Ann Rheum Dis* 59: 705-708.
75. Takizawa Y, Ishigaki K, Maruyama J, Setoguchi K, Ishida T (2012) A case of severe bilateral lupus chorioretinopathy without major organ involvement. *Int J Rheum Dis* 15: e153-5.
76. Lee WJ, Cho HY, Lee YJ, Lee BR, Shin JP (2013) Intravitreal bevacizumab for severe vaso-occlusive retinopathy in systemic lupus erythematosus. *Rheumatol Int* 33: 247-251.
77. Ho TY, Chung YM, Lee AF, Tsai CY (2008) Severe vaso-occlusive retinopathy as the primary manifestation in a patient with systemic lupus erythematosus. *J Chin Med Assoc* 71: 377-380.
78. Damato E, Chilov M, Lee R, Singh A, Harper S, et al. (2011) Plasma exchange and rituximab in the management of acute occlusive retinal vasculopathy secondary to systemic lupus erythematosus. *Ocul Immunol Inflamm* 19: 379-81.
79. Papadaki TG, Zacharopoulos IP, Papaliodis G, Iaccheri B, Fiore T, et al. (2006) Plasmapheresis for lupus retinal vasculitis. *Arch Ophthalmol* 124: 1654-1656.
80. Shaharir SS, Mustafar R, Mohd R, Mohd Said MS, Gafor HA (2015) Persistent hypertension in lupus nephritis and the associated risk factors. *Clin Rheumatol* 34: 93-97.

81. Choe JY, Park SH, Kim JY, Jung HY, Kim SK (2010) A case of systemic lupus erythematosus presenting as malignant hypertension with hypertensive retinopathy. *Korean J Intern Med* 25: 341-344.
82. Mendrinos E, Mavrakanas N, Kiel R, Pournaras CJ (2009) Bilateral combined central retinal artery and vein occlusion in systemic lupus erythematosus resulting in complete blindness. *Eye (Lond)* 23: 1231-1232.
83. Yen YC, Weng SF, Chen HA, Lin YS (2013) Risk of retinal vein occlusion in patients with systemic lupus erythematosus: a population-based cohort study. *Br J Ophthalmol* 97: 1192-1196.
84. Au A, O'Day J (2004) Review of severe vaso-occlusive retinopathy in systemic lupus erythematosus and the antiphospholipid syndrome: associations, visual outcomes, complications and treatment. *Clin Experiment Ophthalmol* 32: 87-100.
85. Chang PC, Chen WS, Lin HY, Lee HM, Chen SJ (2010) Combined central retinal artery and vein occlusion in a patient with systemic lupus erythematosus and anti-phospholipid syndrome. *Lupus* 19: 206-209.
86. Nishiguchi KM, Ito Y, Terasaki H (2013) Bilateral central retinal artery occlusion and vein occlusion complicated by severe choroidopathy in systemic lupus erythematosus. *Lupus* 22: 733-735.
87. Hickman RA, Denniston AK, Yee CS, Toescu V, Murray PI, et al. (2010) Bilateral retinal vasculitis in a patient with systemic lupus erythematosus and its remission with rituximab therapy. *Lupus* 19: 327-329.
88. Aristodemou P, Stanford M (2006) Therapy insight: The recognition and treatment of retinal manifestations of systemic vasculitis. *Nat Clin Pract Rheumatol* 2: 443-451.
89. Baglio V, Gharbiya M, Balacco-Gabrieli C, Mascaro T, Gangemi C, et al. (2011) Choroidopathy in patients with systemic lupus erythematosus with or without nephropathy. *J Nephrol* 24: 522-529.
90. Nguyen QD, Uy HS, Akpek EK, Harper SL, Zacks DN, et al. (2000) Choroidopathy of systemic lupus erythematosus. *Lupus* 9: 288-298.
91. Aronson AJ, Ordoñez NG, Diddie KR, Ernest JT (1979) Immune-complex deposition in the eye in systemic lupus erythematosus. *Arch Intern Med* 139: 1312-1313.
92. Cho HY, Nasir HH, Sobrin L (2014) Focal laser photocoagulation and photodynamic therapy for lupus choroidopathy. *Lupus* 23: 412-416.
93. Chan WM, Li EK, Chan AY, Lam DS (2003) Bilateral retinal detachment in a young woman. *Lancet* 361: 2044.
94. Chin YC, Bhargava M, Khor CC, Cheung CM, Wong TY (2014) Polypoidal choroidal vasculopathy and systemic lupus erythematosus. *Lupus* 23: 319-322.
95. Fuentes-Paez G, Celis-Sanchez J, Torres J, Martínez-Osorio H, Herreras JM (2005) Serpiginous choroiditis in a patient with systemic lupus erythematosus. *Lupus* 14: 928-929.
96. Kobak S, Deveci H (2010) Retinopathy due to antimalarial drugs in patients with connective tissue diseases: are they so innocent? A single center retrospective study. *Int J Rheum Dis* 13: e11-5.
97. Shein J, Shukla D, Reddy S, Yannuzzi LA, Cunningham ET Jr (2008) Macular infarction as a presenting sign of systemic lupus erythematosus. *Retin Cases Brief Rep* 2: 55-60.
98. Feinglass EJ, Arnett FC, Dorsch CA, Zizic TM, Stevens MB (1976) Neuropsychiatric manifestations of systemic lupus erythematosus: diagnosis, clinical spectrum, and relationship to other features of the disease *Medicine (Baltimore)* 55: 323-39
99. Jabs DA, Miller NR, Newman SA, Johnson MA, Stevens MB (1986) Optic neuropathy in systemic lupus erythematosus. *Arch Ophthalmol* 104: 564-568.
100. Lessell S (1979) The neuro-ophthalmology of systemic lupus erythematosus. *Doc Ophthalmol* 47: 13-42.
101. Siatkowski RM, Scott IU, Verm AM, Warn AA, Farris BK, et al. (2001) Optic neuropathy and chiasmopathy in the diagnosis of systemic lupus erythematosus. *J Neuroophthalmol* 21: 193-8.
102. Brandt KD, Lessell S, Cohen AS (1975) Cerebral disorders of vision in systemic lupus erythematosus. *Ann Intern Med* 83: 163-169.
103. Keane JR (1995) Eye movement abnormalities in systemic lupus erythematosus. *Arch Neurol* 52: 1145-1149.
104. Montehermoso A, Cervera R, Font J, Ramos-Casals M, García-carrasco M, et al. (1999) Association of Antiphospholipid Antibodies With Retinal Vascular Disease in Systemic Lupus Erythematosus. *Semin Arthritis Rheum* 28: 326-32.
105. Miserocchi E, Baltatzis S, Foster CS (2001) Ocular features associated with anticardiolipin antibodies: a descriptive study. *Am J Ophthalmol* 131: 451-456.
106. Ilhan F, Celiker U, Godekmerdan A, Kan E (2005) The antiphospholipid antibody syndrome research in patients with retinal venous occlusion. *Arch Med Res* 36: 372-375.
107. Atsumi T, Khamashta MA, Haworth RS, Brooks G, Amengual O, et al. (1998) Arterial disease and thrombosis in the antiphospholipid syndrome: a pathogenic role for endothelin 1. *Arthritis Rheum* 41: 800-807.
108. Castañón C, Amigo MC, Bañales JL, Nava A, Reyes PA (1995) Ocular vaso-occlusive disease in primary antiphospholipid syndrome. *Ophthalmology* 102: 256-262.
109. Sobecki R, Korporowicz D, Terpińska-Pakuła K (2004) [Ophthalmic signs in antiphospholipid syndrome. Patient description]. *Klin Oczna* 106: 661-663.
110. Dunn JP, Noorily SW, Petri M, Finkelstein D, Rosenbaum JT, et al. (1996) Antiphospholipid antibodies and retinal vascular disease. *Lupus* 5: 313-322.
111. Fitzpatrick EP, Chesen N, Rahn EK (1990) The lupus anticoagulant and retinal vaso-occlusive disease. *Ann Ophthalmol* 22: 148-152.
112. Snyers B, Lambert M, Hardy JP (1990) Retinal and choroidal vaso-occlusive disease in systemic lupus erythematosus associated with antiphospholipid antibodies. *Retina* 10: 255-260.
113. Giorgi D, Pace F, Giorgi A, Bonomo L, Gabrieli CB (1999) Retinopathy in systemic lupus erythematosus: pathogenesis and approach to therapy. *Hum Immunol* 60: 688-696.
114. Giorgi D, Balacco Gabrieli C (1999) Optic neuropathy in systemic lupus erythematosus and antiphospholipid syndrome (APS): clinical features, pathogenesis, review of the literature and proposed ophthalmologic criteria for APS diagnosis. *Clin Rheumatol* 8: 124-31.
115. Vaphiades MS, Brock W, Brown HH, Petursson G, Westfall CT (2001) Catastrophic antiphospholipid antibody syndrome manifesting as an orbital ischemic syndrome. *J Neuroophthalmol* 21: 260-263.
116. Keeling D, Mackie I, Moore GW, Greer IA, Greaves M; British Committee for Standards in Haematology (2012) Guidelines on the investigation and management of antiphospholipid syndrome. *Br J Haematol* 157: 47-58.
117. Irini P, Chatziralli, Kanonidou E, Chatzirallis A, Dimitriadis P, Keryttopoulos P (2011) Episcleritis Related to Drug-Induced Lupus Erythematosus following Influximab Therapy: A Case Report. *Case Reports in Medicine* 2011: 1-3.
118. Kersey JP, Broadway DC (2006) Corticosteroid-induced glaucoma: a review of the literature. *Eye (Lond)* 20: 407-416.
119. Hollander DA, Aldave AJ (2004) Drug-induced corneal complications. *Curr Opin Ophthalmol* 15: 541-548.
120. Payne JF, Hubbard GB 3rd, Aaberg TM Sr, Yan J (2011) Clinical characteristics of hydroxychloroquine retinopathy. *Br J Ophthalmol* 95: 245-250.
121. Levy GD, Munz SJ, Paschal J, Cohen HB, Pince KJ, et al. (1997) Incidence of hydroxychloroquine retinopathy in 1,207 patients in a large multicenter outpatient practice. *Arthritis Rheum* 40: 1482-1486.
122. Marmor MF, Kellner U, Lai TY, Lyons JS, Mieler WF; American Academy of Ophthalmology (2011) Revised recommendations on screening for chloroquine and hydroxychloroquine retinopathy. *Ophthalmology* 118: 415-422.
123. Kirou KA, Gkrouzman E (2013) Anti-interferon alpha treatment in SLE. *Clin Immunol* 148: 303-312.