

Efficacy of Single Day-Light Photodynamic Therapy Session with Aminolevulinic Acid 5% Thermosetting Gel with a Penetration-Empowering Facial Mask in the Treatment of Severe Actinic Damage of the Face and Scalp

Mario Puviani^{1*}, Massimo Milani²

¹Medica Plus Dermatology Clinic, Modena, Italy; ²Medical Department, Cantabria Labs Difa Cooper, Caronno Pertusella, Italy

ABSTRACT

Introduction: Photodynamic therapy (PDT) is an effective treatment of actinic keratosis (AK) and severe photo aging. Day-light PDT (DL-PDT) is considered an alternative of C-PDT with similar efficacy but with significantly lower procedure-associated pain. A new formulation of ALA at “low” concentration (5%) in a thermosetting gel is available for C-PDT or DL-PDT. When used for PDT the incubation time of this gel is in general 2-2.5 hours. This formulation with high content of water could be feasible for application with penetration-empowering dual mask which could optimize and speed-up the penetration of the active compound through the skin. This mask device comes in two layers. The first layer is wet and in contact with the applied gel. The second layer, which is dry and overlaid on the first, allows the key ingredients to penetrate the stratum-corneum utilizing a micro-current circuit using two anodes placed on each side of the mask acting as natural batteries. This mask could reduce the incubation time of the photosensitizer needed to allow adequate skin penetration before the PDT procedure.

Study aim: To evaluate in a pilot-study the efficacy and tolerability of DL-PDT with a thermosetting 5% ALA gel applied using a specific mask penetration-enhancer device.

Subjects and methods: A total of 15 men aged >50 years with severe actinic damage of the face or scalp were enrolled in this pilot study. ALA 5% gel was applied (2.5 ml) on the face and scalp. The empowering mask was then put on the treatment area with an incubation time of 1.5 hour. A single day-light session of 20-30 minute (according to the UV fluence of the day) was performed. The primary outcome was the evolution of a 7-item actinic damage score (ADS) evaluating: elastosis, hyperpigmentation, telangiectasia, fine wrinkles, deep wrinkles, stellate pseudo-scar, and presence of actinic keratosis lesions. For each parameter, a 4-grade scale score (0=sign absent; 3: sign severe) was calculated. Therefore, the maximum level of ADS was 21. The baseline visit was performed just before the DL-PDT session; the final evaluation visit was performed two months after the DL-PDT session. A patient-assessed procedure-related pain score using a 4-point scale (0: no pain; 3: severe pain) was performed at the end of the DL-session.

Results: Before DL-PDT, the ADS, mean (SD), score was 16 (5). A total of 74 AK clinically relevant lesions were also present at baseline. At the final visit, the ADS score was significantly reduced to 5(5), corresponding to a -69% reduction. AK lesions at the final visit were reduced by 70% (from 74 to 22). DL-PDT was in general very well tolerated. The procedure-related pain score mean (SD) value was 0.5 (0.5).

Conclusion: In subjects with severe actinic damage, a single DL-PDT session with ALA 5% thermosetting gel, with penetration-empowering mask application, was very effective and well tolerated in reducing clinical signs of skin photo damage and reducing AK lesion number.

*Correspondence to: Mario Puviani, MD, Medica Plus Dermatology Clinic, Via Caduti in Guerra 101, Modena, Italy, E-mail: mariopuf@libero.it

Received: July 31, 2019; Accepted: August 07, 2019; Published: August 14, 2019

Citation: Puviani M, Milani M (2019) Efficacy of Single Day-Light Photodynamic Therapy Session with Aminolevulinic Acid 5% Thermosetting Gel with a Penetration-Empowering Facial Mask in the Treatment of Severe Actinic Damage of the Face and Scalp. J Clin Exp Dermatol Res. 10:502. DOI: 10.35248/2155-9554.19.10.502.

Copyright: © 2019 Puviani M, et al. This is an open-access article distributed under the terms of the Creative Commons Attribution License, which permits unrestricted use, distribution, and reproduction in any medium, provided the original author and source are credited.

Keywords: Aminolevulinic acid; Actinic keratosis; Day-light photo dynamic therapy

INTRODUCTION

Photodynamic therapy (PDT) is an effective treatment of actinic keratosis and severe photoaging. Treatment of actinic keratosis (AK) and field cancerization with photodynamic therapy (PDT) is an effective therapeutic approach with a significant reduction in the number of AK lesions (-75% or more) associated with a significant cosmetic improvement of the photodamaged skin [1]. Recently, also the daylight PDT (DL-PDT) has proven to be as effective as the conventional PDT (CPDT) but with a better tolerability. Day-light PDT (DL-PDT) is considered an alternative of C-PDT with similar efficacy but with significantly lower procedure-associated pain. The concept of photodynamic therapy (PDT) was introduced at the beginning of the 20th century [2]. PDT is based on the interaction of three components-visible lights, oxygen and a photosensitizer. The sensitizer is applied either systemically or topically. Most photosensitizers selectively accumulate in neoplastic cells. The most utilized photosensitizer in PDT is a precursor of Protoporphyrin IX (PpIX): the 5-aminolevulinic acid (ALA). 5-

ALA is, in fact, a metabolite of heme biosynthesis [3,4]. Intracellularly, it is converted to PpIX. In most cases, 5-ALA is applied in creams, emulsions or ointments at a concentration of 10–20%. A new formulation of ALA at “low” concentration (5%) in a thermosetting gel is available for C-PDT or DL-PDT (ALAFast; Cantabria Labs Difa Cooper). This formulation, thanks to its high content in water, could be feasible for application with penetration-empowering dual mask which could optimize and speed-up the penetration of the active compound through the skin. This mask device (Franz Infusion Dual Mask System) comes in two layers [5]. The first layer is wet and in contact with the applied gel. The second layer, which is dry and overlaid on the first, allows the key ingredients to penetrate the stratum-corneum utilizing a micro-current circuit using two anodes placed on each side of the mask acting as natural batteries. The mask is designed for the face but it could be used also for the bald scalp also (Figure 1). This mask could reduce the incubation time of the photosensitizer needed to allow adequate skin penetration before the PDT procedure [6].

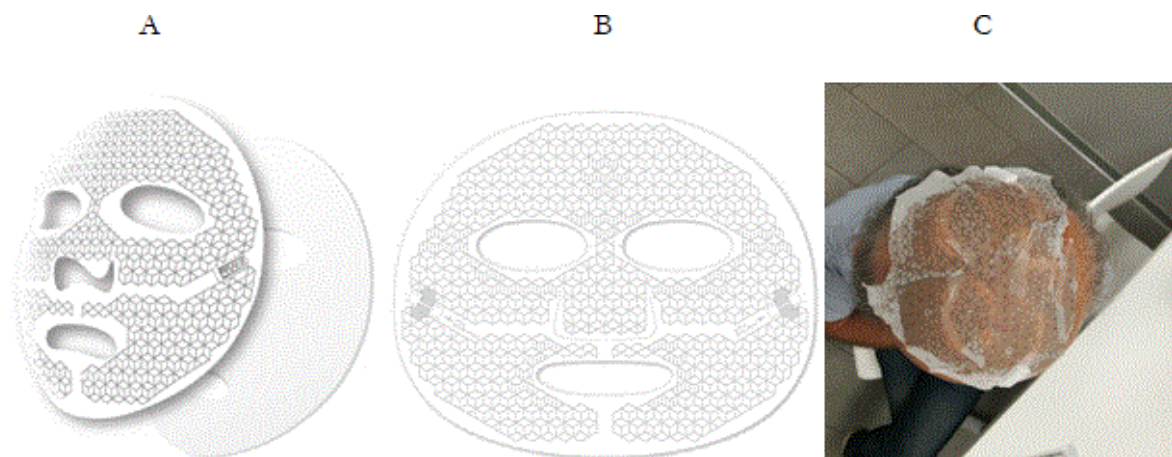

Figure 1: The Dual Mask Enhancer System (A: the two layers; B: the external layer; C: use of the mask on scalp).

STUDY AIM

To evaluate in a pilot-study the efficacy and tolerability of DL-PDT with a thermosetting 5% ALA gel applied using a specific penetration enhancer mask device.

SUBJECTS AND METHODS

Study design

We conducted a monocenter, pilot, prospective study in patients with multiple AK lesions suitable for photodynamic therapy.

Subjects

Eligible subjects were men or women, aged 18 years or more with at least 6 clinically typical, visible AK lesions on the scalp or face. Non-eligible criteria were history of skin conditions other than AK (i.e. eczema, psoriasis or xeroderma

pigmentosum) or specific AK treatments in the previous 6 months, pregnancy or breast feeding. Informed written consent was obtained from all patients before their treatment. A total of 15 men aged >50 years with severe actinic damage of the face or scalp were enrolled in this pilot study. ALA 5% gel was applied (2.5 ml) on the face and scalp. The empowering mask was then put on the treatment area with an incubation time of 1.5 hour (vs. 2-2.5 hours when the gel is applied alone). A single day-light session of 20-30 minute (according to the UV fluence of the day) was performed. In more details, the daylight illumination was performed between 11 a.m. and 3 p.m. At the end of daylight exposure, residual ALA gel was wiped off, followed by application of a lenitive cream. Patients were instructed to avoid daylight for the following 24 h.

Study outcomes

The primary outcome was the evolution of a 7-item actinic damage score (ADS) evaluating: elastosis, hyperpigmentation, telangiectasia, fine wrinkles, deep wrinkles, stellate pseudoscar, and presence of actinic keratosis lesions. For each parameter, a 4-grade scale score (0=sign absent; 3: sign severe) was calculated. A secondary outcome of the trial was the change in AK lesions number from baseline to month 2. The baseline visit was performed just before the DL-PDT session; the final evaluation visit was performed two months after the single DL-PDT session. A patient-assessed procedure-related pain score using a 4-point scale (0: no pain; 3: severe pain) was performed just at the end of the DL-session.

Statistical analysis

Statistical analysis was performed using GraphPad statistical software ver. 13.0 (La Jolla, CA, USA). Continuous variables were expressed as mean \pm Standard Deviation (SD). The endpoints of the trial were the evolution of ADS score and the

evolution of AK mean number from baseline and after treatment. The paired T test, the Wilcoxon and the Mann-Whitney tests were used for the analysis of the study. We calculated the 95% Confidence intervals of the difference in all the variables. According to the nature of a pilot study no sample size calculation was performed.

RESULTS

At baseline the ADS, mean (SD), score was 16 (5). Total AK lesions count at baseline was 78, an average of 5.2 AK lesions per subjects. At the final visit the ADS score was reduced to 5(5) with an absolute difference of -11 (95% CI from -9 to -13). DL-PDT sessions reduced the total AK lesion count to 21, representing a -73% reduction in comparison with baseline with an average of 1.4 AK lesions per subjects with an absolute difference in AK lesion number of -57 (95% CI from -52 to -62). The procedure-related pain score mean (SD) value was 0.5(0.5) (Figure 2). Figure 3 show a clinical case just before DL-PDT session and after 1 and 2 months.

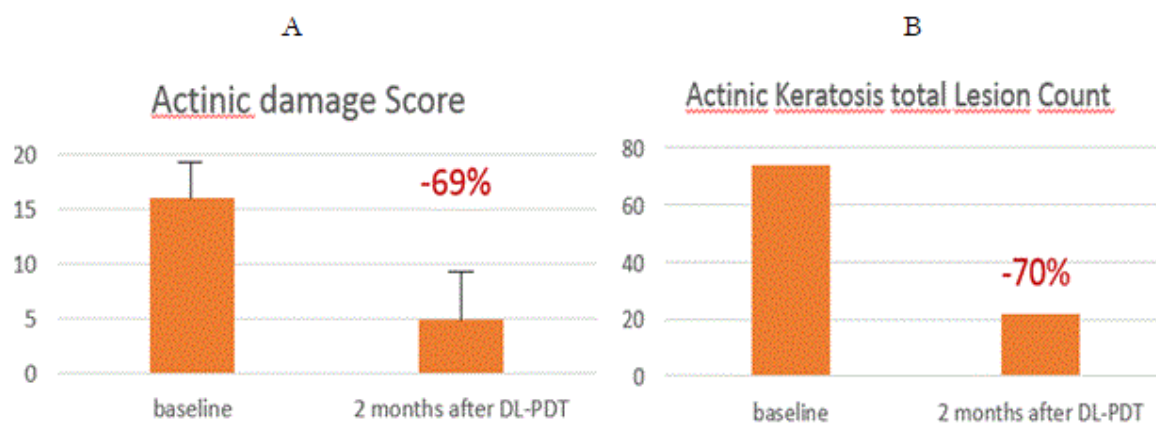


Figure 2: Evolution of Actinic Damage Score (A) and AK lesion count (B) at baseline and at 2 months after the DL-PDT.

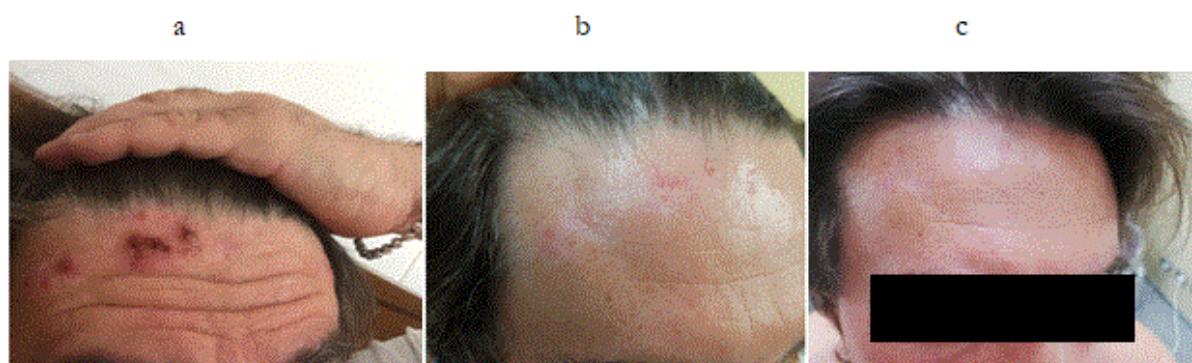


Figure 3: A subject at baseline, just after DL-PDT (a) session 1 (b) session 2 and (c) months after DL-PDT.

DISCUSSION

In this pilot study, we demonstrated that a single DL-PDT session performing with a 5% ALA gel using a penetration enhancer mask, with an incubation time of 1.5 hour, is effective and well tolerated as treatment of skin actinic damage and AK lesions with a reduction of AK lesion number of 70% which is similar with the clinical results obtained with 16% cream of

methyl aminolevulinic acid (MAL). Topical photodynamic therapy (PDT) using red light source 570–670 nm (the so called Conventional PDT) or sun light (DL-PDT) is acknowledged to be an effective and safe treatment for AK with favorable cosmetic outcomes [7,8]. Sunlight can activate photodynamic therapy (PDT), and this is a proven strategy to reduce pain caused by the conventional PDT treatment. Both C-PDT and DL-PDT involves the topical application of a photosensitizer, 5-

aminolevulinic acid (ALA), or its methyl ester-methyl aminolevulinate (MAL) which are precursor of the endogenous photosensitizer, Protoporphyrin IX, and subsequent illumination of the skin lesion with light of the appropriate wavelength [9]. The combination of photosensitizer, a light source and tissue oxygen, leads to the chemical destruction of any tissues which have either selectively taken up the photosensitizer or have been locally exposed to light, with recruitment of inflammatory cells, increased immune response, and vascular compromise. Single oxygen can also destroy photosensitizing agent itself preventing further action, a process referred to as photo bleaching. The wavelength of the light source needs to be appropriate for exciting the photosensitizer to produce reactive oxygen species. These reactive oxygen species generated through PDT are free radicals generated through electron abstraction or transferred from a substrate molecule and highly reactive state of oxygen known as singlet oxygen. Daylight photodynamic therapy (DL-PDT) is a simple and practical treatment option for AK I and II and for actinic damage of the face and scalp that allows treatment of multiple lesions and large areas with high tolerability. When ALA is used for both C-PDT and DL-PDT concentration of 10-20% are commonly utilized. A new thermosetting gel containing ALA 5% is available [10-14]. This formulation allows a more convenient application procedure without occlusion and better and more efficient release of the active compound in comparison with traditional ALA formulations like creams or ointments. This gel has demonstrated to be efficacious and well tolerated in PDT treatment of subjects with acne. So far there are no data regarding the efficacy of this gel in AK treatment. This gel applied with a penetration enhancer mask has shown promising efficacy results in the treatment of actinic damage and AK with DL-PDT [15,16]. Our study is a pilot trial; therefore, the results we have obtained should be confirmed by larger comparative trials.

CONCLUSION

In subjects with severe actinic damage, a single DL-PDT session with ALA 5% thermosetting gel, with penetration-empowering mask application, was very effective and well tolerated in reducing clinical signs of skin photodamage.

TRANSPARENCY

Declaration of funding

This was an independent non-sponsored trial.

Declaration of financial/other relationships

MM is an employee of Cantabria Lab, Difa Cooper. The other author (MP) reports no conflicts of interest.

Contribution statement

MP conducted the trial performing visits and instrumental evaluations. MM was involved in study protocol design. Both authors contributed toward data analysis, drafting and critically

revising the paper and agree to be accountable for all aspects of the work.

Acknowledgment

None reported.

REFERENCES

1. Kormeili T, Yamauchi PS, Lowe NJ. Topical photodynamic therapy in clinical dermatology. *Br J Dermatol*. 2004;150:1061-1069.
2. Lacour JP, Ulrich C, Gilaberte Y, Von Felbert V, Basset - Seguin N, Dreno B, et al. Daylight photodynamic therapy with methyl aminolevulinate cream is effective and nearly painless in treating actinic keratoses: A randomised, investigator - blinded, controlled, phase III study throughout Europe. *J Eur Acad Dermatol Venereol*. 2015; 29:2342-2348.
3. Morton CA, Wulf HC, Szeimies RM, Gilaberte Y, Basset - Seguin N, Sotiriou E, et al. Practical approach to the use of daylight photodynamic therapy with topical methyl aminolevulinate for actinic keratosis: A European consensus. *J Eur Acad Dermatol Venereol*. 2015; 29:1718-1723.
4. Dougherty TJ, Gomer CJ, Henderson BW, Jori G, Kessel D, Korbek M, et al. Photodynamic therapy. *JNCI*. 1998; 90:889-905.
5. Henderson BW, Dougherty TJ. How does photodynamic therapy work? *Photochemistry and Photobiology*. 1992; 55:145-157.
6. Kennedy JC, Marcus SL, Pottier RH. Photodynamic therapy (PDT) and photodiagnosis (PD) using endogenous photosensitization induced by 5-aminolevulinic acid (ALA): Mechanisms and clinical results. *Lasers Surg Med*. 1996;14:289-304.
7. Wachowska M, Muchowicz A, Firczuk M, Gabrysiak M, Winiarska M, Wańczyk M, et al. Aminolevulinic acid (ALA) as a prodrug in photodynamic therapy of cancer. *Molecules*. 2011; 16:4140-4164.
8. Bourre L, Thibaut S, Briffaud A, Lajat Y, Patrice T. Potential efficacy of a delta 5-aminolevulinic acid thermosetting gel formulation for use in photodynamic therapy of lesions of the gastrointestinal tract. *Pharmacol Res*. 2002;45:159-165.
9. Pariser DM, Lowe NJ, Stewart DM, Jarratt MT, Lucky AW, Pariser RJ, et al. Photodynamic therapy with topical methyl aminolevulinate for actinic keratosis: results of a prospective randomized multicenter trial. *J Am Acad Dermatol*. 2003;48:227-232.
10. Fargnoli MC, Piccioni A, Neri L, Tambone S, Pellegrini C, Peris K. Conventional vs. daylight methyl aminolevulinate photodynamic therapy for actinic keratosis of the face and scalp: An intra - patient, prospective, comparison study in Italy. *J Eur Acad Dermatol Venereol*. 2015;29:1926-1932.
11. Dodds A, Chia A, Shumack S. Actinic keratosis: rationale and management. *Dermatology and Therapy*. 2014;4:11-31.
12. Foster TH, Murrant RS, Bryant RG, Knox RS, Gibson SL, Hilf R. Oxygen consumption and diffusion effects in photodynamic therapy. *Radiation Research*. 1991;126:296-303.
13. Calzavara-Pinton P, Hædersdal M, Barber K, Basset-Seguin N, Del Pino FME, Foley P, et al. Structured expert consensus on actinic keratosis: Treatment algorithm focusing on daylight PDT. *J Cutan Med Surg*. 2017;21:3S-16S.
14. Collaud S, Peng Q, Gurny R, Lange N. Thermosetting gel for the delivery of 5-aminolevulinic acid esters to the cervix. *J Pharm Sci*. 2008;97:2680-2690.
15. Jeong B, Kim SW, Bae YH. Thermosensitive sol-gel reversible hydrogels. *Adv Drug Deliv Rev*. 2012;64:154-162.
16. Serini SM, Cannizzaro MV, Dattola A, Garofalo V, Del Duca E, Ventura A, et al. The efficacy and tolerability of 5 - aminolevulinic

acid 5% thermosetting gel photodynamic therapy (PDT) in the treatment of mild - to - moderate acne vulgaris. A two - center,

prospective assessor - blinded, proof - of - concept study. Clin Cosmet Investig Dermatol. 2019;18:156-162.