

An Unusual Case of Intoxication: High Blood Alcohol Levels without Alcohol Ingestion

Filippo Sanfilippo^{1,2*}, Ajay Raithatha¹, Mimmo Scollo² and Renato Bernardini²

¹Department of Critical Care, Sheffield Teaching Hospitals NHS Foundation Trust, Northern General Hospital, Herries Road, Sheffield, S5 7AU, UK

²Department of Clinical and Molecular Biomedicine, section of Pharmacology and Biochemistry, University of Catania, V.le A. Doria 6, Catania 95100 Italy

*Corresponding author: Sanfilippo Filippo, Sheffield Teaching Hospitals NHS Foundation Trust, Northern General Hospital, Herries Road, Sheffield, S5 7AU, UK, Tel: 00447883681254; Email: filipposanfi@yahoo.it

Received date: Jan 29, 2015, Accepted date: Mar 10, 2015, Published date: Mar 14, 2015

Copyright: © 2015 Filippo S, et al. This is an open-access article distributed under the terms of the Creative Commons Attribution License, which permits unrestricted use, distribution, and reproduction in any medium, provided the original author and source are credited.

Abstract

We describe an unusual case of intentional intoxication through inhalational abuse of hairspray. On the scene, paramedics found a haemodynamically stable but unconscious female surrounded by more than 100 cans of hairspray. On arrival to the emergency department the patient had recovered consciousness, and was only mildly confused. Blood samples showed severe metabolic acidosis with an increased anion gap and, deranged Urea, Creatinine and Creatine phosphoKinase (CpK). The patient was then admitted to the high-dependency unit, while simultaneously receiving intravenous hydration. The metabolic features improved over the next few hours, and renal replacement therapy was not initiated. However the patient remained confused for a 24-hours period, in a "hangover-like" state, despite the metabolic parameters returning to normal. Interestingly the toxicology screen on admission subsequently showed high alcohol levels (206 mg/dl), despite no history of oral alcohol intake. The lady was known to chronically abuse and inhale hairspray. The patient was discharged 4 days later with full recovery.

We explain the prolonged confusional state by the presence of relatively high alcohol levels, induced by the inhaled hairspray. Polyanions (such as the acrylates contained in the hairspray) are well known to increase tissue permeability, and are used as drug-carriers. In this case polyanion activity on airways mucosa favoured the absorption of denatured alcohol, the main compound in the hairspray. Initially, the metabolism of polyanions produces acids causing bicarbonate consumption and increased anion gap. However the short half-life of these anions is typically associated with a fast recovery, with normal bicarbonate levels at 24-hours post-admission.

Keywords: Inhalational intoxication; Alcohol; Acrylates; Anion gap; Mucosae permeability

Case Report

A 36 year-old Caucasian lady was found unresponsive by her sister, who called an ambulance. On arrival, paramedics noted the patient was surrounded by more than 100 cans of hairspray. On the scene Glasgow Coma Score (GCS) was 10/15 (E₂M₅V₃) and the following vital signs were recorded: heart rate 63 beats per minute (sinus rhythm), blood pressure 92/49 mmHg, temperature 35.9 degrees Celsius and respiratory rate 24 breaths per minute. The family confirmed she was known to buy 'trolley-loads' of hairspray, and that she regularly inhaled it as a form of solvent abuse. There was no history or signs of alcohol intake or medication overdose at the scene, and the family confirmed she did not drink alcohol. There was a past medical history of mild depression with poor compliance to the psychiatric therapy, postural hypotension and gastro-oesophageal reflux disease. Prescribed medications were fluoxetine and lansoprazole, and temazepam as required.

On arrival at the Emergency Department (ED) no clinical signs of cardiovascular or upper airway compromise (stridor or bronchospasm) were detected. The chest radiograph and electrocardiogram were normal. On physical examination there were widespread residuals of hairspray involving about 33% of the total body surface area (face, back, chest, abdomen and buttocks). The

plastic surgery team confirmed there were no burns, and hairspray residuals easily came off once washed with warm water. The patient's conscious level was improving at the time of ED admission, with only mild confusion (GCS 14/15, E₄M₆V₄) and an abbreviated mental test score was 4/10. The patient remained tachypnoeic but no other significantly positive findings were detected in the physical examination. Arterial blood gas analysis in the ED showed acute severe metabolic acidosis, with only partial respiratory compensation, despite a low value of PaCO₂ (Table 1). Full blood count analysis was normal. Abnormal laboratory results were: raised CpK (549 IU/L) and CKMB (19.7 IU/L), together with a finding of acute renal failure (Urea 17.6 mmol/l and Creatinine 266 µmol/l). Troponin I was negative on admission and remained negative 8 hours later. The toxicology screen showed blood alcohol levels of 206 mg/dl (the UK driving limit being 80 mg/dl), while paracetamol and salicylate levels were undetectable. Urine toxicology screen was positive for benzodiazepines.

The patient was transferred to the High Dependency Unit (HDU) for neurological observation and monitoring of renal function and acid-base status, an infusion of 2 litres of Compound Sodium Lactate (Hartmann's solution) had already been administered. A Bicarbonate infusion was considered, however there had already been an improvement in the metabolic acidosis by the time of HDU arrival. No bicarbonates or diuretics were given and fluid-therapy was continued to maintain a diuresis of 1-2 ml/kg/h, in order to facilitate toxin washout. Eighteen hours after admission the metabolic acidosis had completely resolved, and a mild respiratory alkalosis was recorded at

last arterial gas analysis prior to ward discharge (Table 1). Four days after admission the patient was discharged home, follow-up having been arranged with the psychiatrist. Creatinine and Urea levels were within the normal range at discharge.

Time	Time 0 (Arrival in ED)	1 hours post admission (Transfer to HDU)	8 hours post admission	18 hours post admission (Discharge to the ward)
pH	7.205	7.31	7.41	7.51
PaCO ₂ (KPa)	3.42	2.79	2.21	4.11
HCO ₃ ⁻ mmol/l	7.2	10.2	10.2	24.6
Na ⁺ mmol/l	143	141	136	137
K ⁺ mmol/l	3.9	3.5	4.2	3.4
Cl ⁻ mmol/l	107	103	103	102
lactate mmol/l	2.6	2.4	1.0	0.8
glucose mmol/l	6.8	4.7	4.1	7.4
anion-gap mmol/l	32.7	31.6	26.9	13.8

Table 1: The most significant arterial blood gases are reported. Hospital admission is considered time 0. The transfer to the High Dependency Unit happened 2 hours after hospital arrival.

Discussion

Overdoses account for 5% to 10% of ED admissions in the United Kingdom where the rate of self-poisoning is amongst the highest in Europe, paracetamol being the commonest cause [1]. Hairspray and other constituent products are used by hairdressers, as well as the general public, but are not a common cause of intentional poisoning.

We examined the literature in order to identify studies and case reports on professional and accidental exposure to the compounds contained in these products. The side effects of hair dyes and hairspray have been previously investigated for those with occupational exposure. Among them, risk of cancer [2-4], female reproductive complications [5], dermatitis and respiratory asthmatic/obstructive disease [6-8] have been particularly screened for.

In the current literature we found only one case report of acute poisoning through intentional ingestion of hair product, in a suicide attempt [9]. In this particular case the clinical picture evolved with worsening renal function due to sodium bromate poisoning, and one week later the patient became anuric and required 5 days of haemodialysis before full recovery.

To the best of our knowledge, this is the first report on intoxication by intentional inhalation of hairspray. The mechanism of intoxication is quite unusual resulting in high serum levels of alcohol and acidosis with increased anion gap, but without evidence of acute alcohol ingestion.

Exploring the possible toxicological mechanisms involved in this case, we reviewed the literature for systemic and single organ toxicity

of the constituent components of hairspray (Figure 1). In particular we focused primarily on the mechanisms of renal and central nervous system impairment, and then also on possible sources for muscular or myocardial dysfunction.

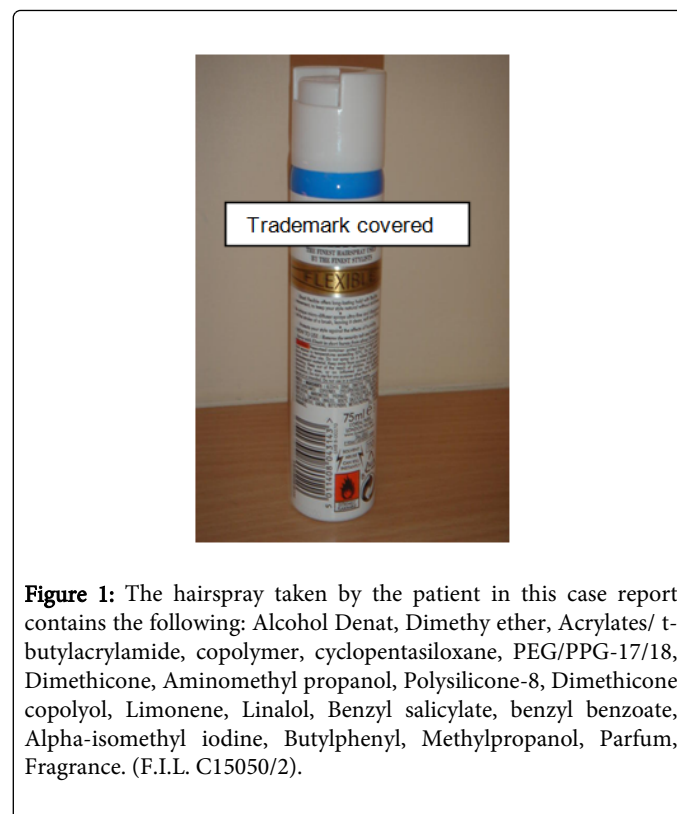


Figure 1: The hairspray taken by the patient in this case report contains the following: Alcohol Denat, Dimethy ether, Acrylates/ t-butylacrylamide, copolymer, cyclopentasiloxane, PEG/PPG-17/18, Dimethicone, Aminomethyl propanol, Polysilicone-8, Dimethicone copolyol, Limonene, Linalol, Benzyl salicylate, benzyl benzoate, Alpha-isomethyl iodine, Butylphenyl, Methylpropanol, Parfum, Fragrance. (F.I.L. C15050/2).

We postulate that the relatively prolonged confusional state, seen in this case, was due primarily to the high blood alcohol levels in combination with benzodiazepines (urine toxicology screen was positive and the patient was known to take temazepam). The patient, family and the general practitioner subsequently confirmed that the patient had no history of alcohol or substance misuse, and it was noted that there was no evidence of alcohol at the scene.

In the absence of ingestion, we explain the high blood alcohol levels as follows. The hairspray contained acrylates (polyanions), known to enhance the permeability of different mucosae (i.e. nasal, buccal and ocular) [10-12]. These polyanions possess a high muco-adhesiveness and improve the bioavailability of several drugs, when topically applied. These substances act by modifying the trans epithelial electrical resistance, and thus cause a reversible opening of the intercellular tight junctions [13]. Subsequent to inhaling multiple hairspray cans, the patient's upper airways mucosa was exposed to a significant load of these polyanions thus increasing mucosal permeability. This in turn favoured the absorption of the alcohol contained in the hairspray itself, as the principal constituent.

Subsequently, these polyanions are rapidly absorbed, metabolized and eliminated as acids and alcohols [14,15]. An experimental study by Kutzman et al. has shown a half-life for elimination of acrylic acid in the order of 20-40 minutes in animals [15]. The primary detoxification of these compounds, results in the release of acrylic acid and the corresponding alcohol [16]. In the case presented it is likely that production of acrylic acid caused bicarbonate consumption, and consequently induced an increased anion gap. The rapid turnover of

these polyanions can explain the quick metabolic improvement seen with normalisation of blood pH, bicarbonate and anion gap at 18 hours post admission. We think the metabolic findings observed are less likely to have been alcohol-induced renal impairment, as this is usually followed by a normal anion gap and less severe acidosis [17].

Another finding was the deranged CpK levels. We feel this is likely consequent to muscle breakdown and dehydration, which could potentially have had a complementary role in the renal impairment in addition. It could be speculated that activity of acrylates in chelating Ca^{2+} [18], and hence causing biochemical muscular impairment, may have played a role in the abnormal CpK levels. Troponin I analyses were negative and the CK-MB isoform was only 3.6% of the total CpK, hence a cardiac event can be excluded. In addition in the ED and HDU the patient's rhythm, monitored with continuous ECG, displayed no abnormalities. An underlying cardiovascular mechanism is unlikely to have led to this patient's collapse.

In relation to further explaining the clinical presentation, this lady was known to chronically abuse and inhale hairspray. Animal data has previously shown that alcohol dependence and high blood alcohol levels can be produced, by exposure to an ethanol-enriched atmosphere (by vaporizing ethanol) [19]. We postulate a similar mechanism, coupled with a psychiatric background, determined the attitude of this lady to chronically inhale hairspray.

Four months later the patient was readmitted to the ED with an acute onset of abdominal pain, the family again confirmed she was continuing to inhale hairspray. Patients with chronic exposure to solvents could also be at risk of accumulation of lead in the bloodstream, increasing the risk of bone marrow and renal toxicity [20]. In examining whether this might have been a possible mechanism for the clinical status of the patient in the case presented, it was noted that full blood count and biochemistry did not show any abnormality. Normal results were also found retrospectively from previous hospital admissions. These findings, together with the full and rapid recovery of kidney function during the case described, make chronic heavy metal poisoning less likely in this patient. Advice to repeat full blood count, biochemistry and serum lead in 6-12 months' time was given to the lady.

Conclusion

This case is an unusual case of acute intentional intoxication through inhalational abuse of hairspray. We conclude that the ability of acrylates to enhance upper airway mucosal permeability facilitated alcohol absorption and high blood alcohol levels in this patient, in the context of no history of alcohol ingestion. Solvent exposure should be considered, when high blood alcohol levels are detected without history or suspicion of ingestion.

In this case, the load of polyanions absorbed led also to an abrupt bicarbonate consumption and thus to a severe metabolic acidosis with increased anion gap. The relatively fast metabolism and elimination of these substances, augmented by an aggressive hydration, determined a rapidly improving clinical picture with normal bicarbonate levels within 18 hours of hospital admission.

References

1. Greene SL, Dargan PI, Jones AL (2005) Acute poisoning: understanding 90% of cases in a nutshell. *Postgrad Med J* 81: 204-216.

2. Takkouche B, Regueira-Méndez C, Montes-Martínez A (2009) Risk of cancer among hairdressers and related workers: a meta-analysis. *Int J Epidemiol* 38: 1512-1531.

3. Harling M, Schablon A, Schedlbauer G, Dulon M, Nienhaus A (2010) Bladder cancer among hairdressers: a meta-analysis. *Occup Environ Med* 67: 351-358.

4. Connelly JM, Malkin MG (2007) Environmental risk factors for brain tumors. *Curr Neurol Neurosci Rep* 7: 208-214.

5. Peters C, Harling M, Dulon M, Schablon A, Torres Costa J, et al. (2010) Fertility disorders and pregnancy complications in hairdressers - a systematic review. *J Occup Med Toxicol* 5: 24.

6. Harth V, Raulf-Heimsoth M, Brüning T, Merget R (2006) Isolated late asthmatic reaction after exposure to ammonium persulfate in a hairdresser. *Contact Dermatitis* 54: 62-63.

7. Albin M, Rylander L, Mikoczy Z, Lillienberg L, Dahlman Höglund A, et al. (2002) Incidence of asthma in female Swedish hairdressers. *Occup Environ Med* 59: 119-123.

8. Hollund BE, Moen BE, Egeland GM, Florvaag E (2003) Prevalence of airway symptoms and total serum immunoglobulin E among hairdressers in Bergen: a four-year prospective study. *J Occup Environ Med* 45: 1201-1206.

9. Kutom A, Bazilinski NG, Magana L, Dunea G (1990) Bromate intoxication: hairdressers' anuria. *Am J Kidney Dis* 15: 84-85.

10. Salama NN, Eddington ND, Fasano A (2006) Tight junction modulation and its relationship to drug delivery. *Adv Drug Deliv Rev* 58: 15-28.

11. González-Mariscal LI, Nava P, Hernández S (2005) Critical role of tight junctions in drug delivery across epithelial and endothelial cell layers. *J Membr Biol* 207: 55-68.

12. Mrsny RJ (2005) Modification of epithelial tight junction integrity to enhance transmucosal absorption. *Crit Rev Ther Drug Carrier Syst* 22: 331-418.

13. Di Colo G, Zambito Y, Zaino C (2008). Polymeric Enhancers of Mucosal Epithelia Permeability: Synthesis, Transepithelial Penetration-Enhancing Properties, Mechanism of Action, Safety Issues. *J Pharm Sci* 97:1652-1680.

14. Fujisawa S, Atsumi T, Kadoma Y (2000) Cytotoxicity of methyl methacrylate (MMA) and related compounds and their interaction with dipalmitoylphosphatidylcholine (DPPC) liposomes as a model for biomembranes. *Oral Dis* 6: 215-221.

15. Kutzman RS, Meyer GJ, Wolf AP (1982) The biodistribution and metabolic fate of [^{11}C]acrylic acid in the rat after acute inhalation exposure or stomach intubation. *J Toxicol Environ Health* 10: 969-979.

16. Linhart I, Vosmanská M, Smejkal J (1994) Biotransformation of acrylates. Excretion of mercapturic acids and changes in urinary carboxylic acid profile in rat dosed with ethyl and 1-butyl acrylate. *Xenobiotica* 24: 1043-1052.

17. Kraut JA, Kurtz I (2008) Toxic alcohol ingestions: clinical features, diagnosis, and management. *Clin J Am Soc Nephrol* 3: 208-225.

18. Aslam SN, Newman MA, Erbs G, Morrissey KL, Chinchilla D, et al. (2008) Bacterial polysaccharides suppress induced innate immunity by calcium chelation. *Curr Biol* 18: 1078-1083.

19. Goldstein DB, Pal N (1971) Alcohol dependence produced in mice by inhalation of ethanol: grading the withdrawal reaction. *Science* 172: 288-290.

20. Uzma N, Salar BM, Kumar BS, Aziz N, David MA, et al. (2008) Impact of organic solvents and environmental pollutants on the physiological function in petrol filling workers. *Int J Environ Res Public Health* 5: 139-146.