

Intravitreal Cysticercosis

Nidhi Relhan^{1,2*}, Avinash Pathengay² and Harry W Flynn Jr^{1*}

¹Department of Ophthalmology, Bascom Palmer Eye Institute University of Miami, Miller School of Medicine, Miami, USA

²Kode Venkatadri Chowdry Campus, LV Prasad Eye Institute, Andhra Pradesh, India

*Corresponding authors: Harry W Flynn Jr, MD Department of Ophthalmology, Bascom Palmer Eye Institute, 900 N. W. 17th Street, Miami, FL 33136; Tel: 305 326-6118 Fax: 305 326-6417; E-mail: hflynn@med.miami.edu

Nidhi Relhan, MD Department of Ophthalmology, Bascom Palmer Eye Institute, 900 N. W. 17th Street, Miami, FL 33136; Tel: 305 326-6118; Fax: 305 326-6417; E-mail: relhan_nidhi@yahoo.co.in

Received date: Apr 22, 2015; Accepted date: Apr 24, 2015; Published date: Apr 27, 2015

Copyright: © 2015 Flynn HW, et al. This is an open-access article distributed under the terms of the Creative Commons Attribution License, which permits unrestricted use, distribution, and reproduction in any medium, provided the original author and source are credited.

Description

An 8 year old girl presented with a slow onset of decreased vision in right eye severe intraocular inflammation and barely visible retinal structures (Figure 1a). Visual acuity in the right eye was 1/200. There was a motile intravitreal globular structure seen (inferiorly-cysticercus cyst-Figure 1a). Although her serology for cysticercus was negative, a computed tomography (CT) scan brain was negative for neurocysticercosis. The patient was treated by vitrectomy, removal of

the cysticercus and silicone oil injection (as she had superior retinal detachment). She was treated with an oral antihelminthic drug (Albendazole-15 mg/kg/day ie 400 mg twice daily and tapering dose of oral steroids along with topical steroids). Figure 1b shows clear view to the retina with quiet eye in the postoperative period. The child's vision improved to 20/40 after cyst removal and is maintained at 1 year of follow-up.

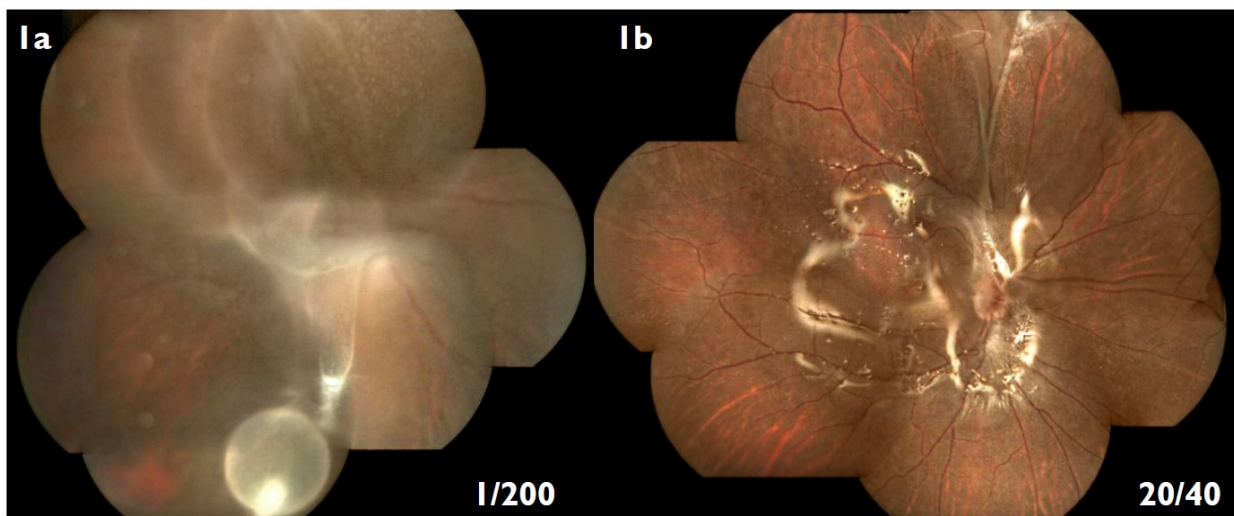


Figure 1: a) Right eye fundus having intense inflammation in the vitreous cavity obscuring all details with visible cysticercus cyst in the inferior part of the vitreous cavity. b) shows postoperative fundus picture with attached retina, superior retinal band and silicone oil reflex.