

Paranglioma Diagnosed in the Last Trimester of Pregnancy (The Great Masquerader)

Manas Malik*

Department of Gynecology and Obstetrics, DJ College of Science and Research, Modinagar, Uttar Pradesh, India

PARAGANGLIOMA

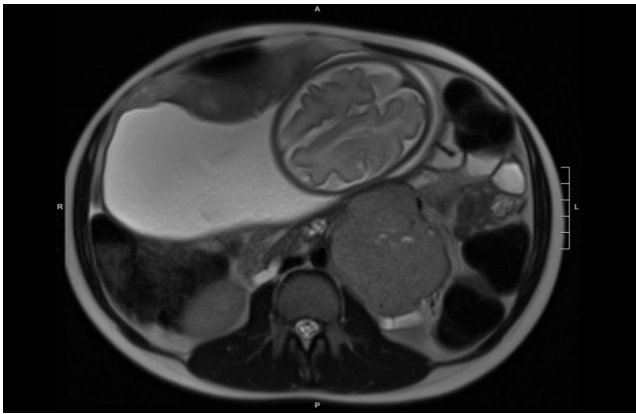


Figure 1: Magnetic Resonance Imaging (MRI).

Image is depiction of Magnetic Resonance Imaging (MRI) is shown without intravenous contrast at 32 weeks of gestation (Figure 1). The paranglioma (asterisk) immediately posterior to the uterus is shown. Parangliomas are found as very rare neuroendocrine

tumours that are located outside the adrenal gland. Its diagnosis is delayed as its clinical symptoms are similar to that of preeclampsia or gestational hypertension. There are controversies on immediate or interval tumour removal which is diagnosed in the third trimester. There are loopholes in guidelines regarding surgical cesarean delivery technique and obstetrical considerations for tumor excision at time of delivery. There is consideration of secondary hypertension in adolescent during pregnancy. There are some challenges for the treatment of hemorrhagic such as preoperative management with alpha blockade. To reduce the morbidity we require a multidisciplinary approach. There should be genetic counseling for women diagnosed with paranglioma and their neonates.

Correspondence to: Manas Malik, Department of Gynecology and Obstetrics, DJ College of Science and Research, Modinagar, Uttar Pradesh, India, Tel: 99385424; E-mail: manasmalik595@gmail.com

Citation: Malik M (2020) Paranglioma Diagnosed in the Last Trimester of Pregnancy (The Great Masquerader). *Gynecol Obstet (Sunnyvale)* 10:531. doi: 10.35248/2161-10932.2020.10.531

Received date: July 26, 2020; **Accepted date:** August 02, 2020; **Published date:** August 09, 2020

Copyright: © 2020 Malik M. This is an open-access article distributed under the terms of the Creative Commons Attribution License, which permits unrestricted use, distribution, and reproduction in any medium, provided the original author and source are credited.