

A Case Report on the Treatment of Methicillin-Resistant Staphylococcus Aureus (MRSA) Infected Tibial Internal Fixation with Calcium Sulfate

Rui Zhou* and Anand Pillai

Department of Trauma and Orthopaedics, University Hospital South Manchester, Manchester, UK

Abstract

The formation of biofilm is one of the main contributing factors for unsuccessful treatment of osteomyelitis. It is formed through bacterial adhesion to the fragments of dead bone. Poor perfusion or devascularization of an infected bone with changes in local pH further limits the diffusion of parenteral antibiotics.

Calcium Sulfate, a biocompatible and completely absorbable local carrier for antibiotics, has shown promising results in treating osteomyelitis. It is associated with less systemic effects and compliance issues when compared with conventional treatment of surgical debridement and prolonged systemic antibiotics.

Keywords: Calcium Sulfate; Ilizarov frame; Osteomyelitis; *Staphylococcus aureus*

Introduction

Despite gradual advances in surgical techniques and antimicrobial agents, the treatment of osteomyelitis remains a challenge. Its management is often difficult as it requires extensive surgical debridement and prolonged antibiotic therapy [1,2]. However, the relapse rate remains high; the primary contributing factor is the formation of a bacterial biofilm. Systemic antibiotics have poor penetration and often require three to four fold increase in concentration to achieve bactericidal activities [3]. Long-term systemic antibacterial therapy can become problematic due to compliance, drug toxicity and dead-space formation.

To counter these problems, systems that release antibiotics locally have been created. Stimulan (Biocomposites Ltd, Keele, UK) is a biodegradable synthetic calcium sulfate, which is completely absorbed and replaced by new bone. Biodegradable and absorbable carriers offer the advantage of avoiding the need for a second removal operation. Synthetic calcium sulfate with 100% purity was first introduced in 2000. This avoids potential toxicity associated with natural mineral sources of calcium sulfate [4].

Case Presentation

A 71-year-old man was referred to us with persistent osteomyelitis of his distal tibia fracture following an internal fixation in August 2013 (Figures 1 and 2). He was treated with an above knee backslab and sent home by emergency department after being diagnosed with closed injury to his right distal tibia and fibula fracture. His medical history included hypertension and a previous history of deep vein thrombosis, which had been treated with Warfarin. When he presented to fracture clinic ten days later, he had developed pressure ulcers over his left heel and medial malleolus.

Orthopaedic surgeons at the referring hospital decided to treat with an external fixator to allow soft tissue healing before definitive surgery. After three weeks of external fixation, the wound over his right medial malleolus had healed. Open reduction and internal fixation of his right tibia fracture was performed in September 2013 (Figures 3 and 4).

Seven weeks later, skin over the medial malleolus broke down again and left the distal part of tibial plate exposed (Figure 5). His tibia fracture failed to heal secondary to osteomyelitis.

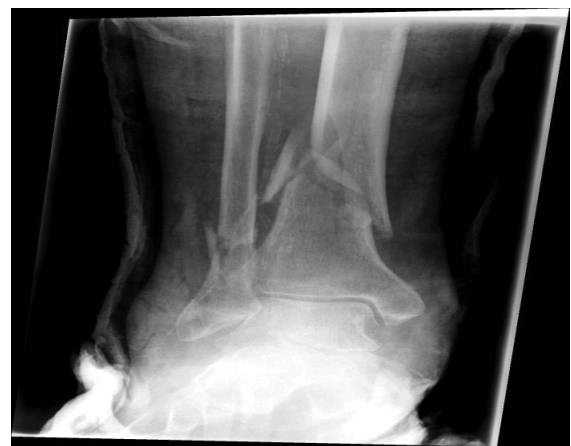

Figure 1: AP radiograph of distal tibia and fibula fracture.

Investigations

Microbacterial culture from superficial wound swab grew MRSA. Intra-operative bone and deep tissue samples showed MRSA, enterococcus and E. coli. All isolates were sensitive to the combination of teicoplanin and gentamicin. Computed Tomography (CT) angiogram confirmed patient lower limb circulation.

Treatment

At referring hospital, he received eight weeks of intravenous teicoplanin and gentamicin with standard MRSA eradication therapy. Throughout the duration of his intravenous antibiotics, he stayed

*Corresponding author: Mr. Rui Zhou, Department of Trauma and Orthopaedics, University Hospital South Manchester, Manchester, UK, Tel: 00447834608594; E-mail: ruizhou0525@gmail.com

Received July 13 2015; Accepted July 22, 2015; Published July 30, 2015

Citation: Zhou R, Pillai A (2015) A Case Report on the Treatment of Methicillin-Resistant Staphylococcus Aureus (MRSA) Infected Tibial Internal Fixation with Calcium Sulfate. Orthop Muscular Syst 4: 195. doi:10.4172/2161-0533.1000195

Copyright: © 2015 Zhou R, et al. This is an open-access article distributed under the terms of the Creative Commons Attribution License, which permits unrestricted use, distribution, and reproduction in any medium, provided the original author and source are credited.

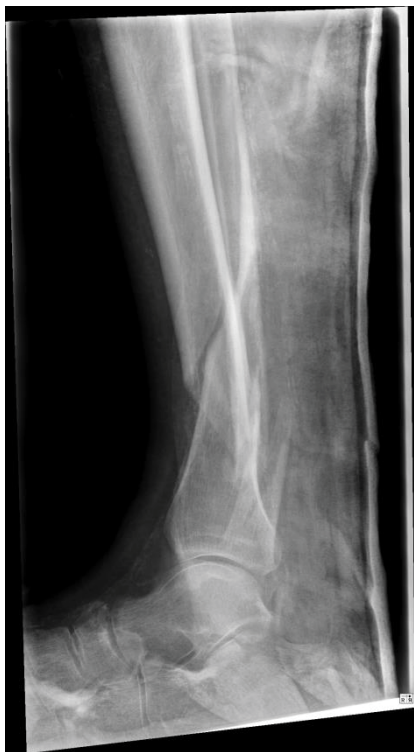
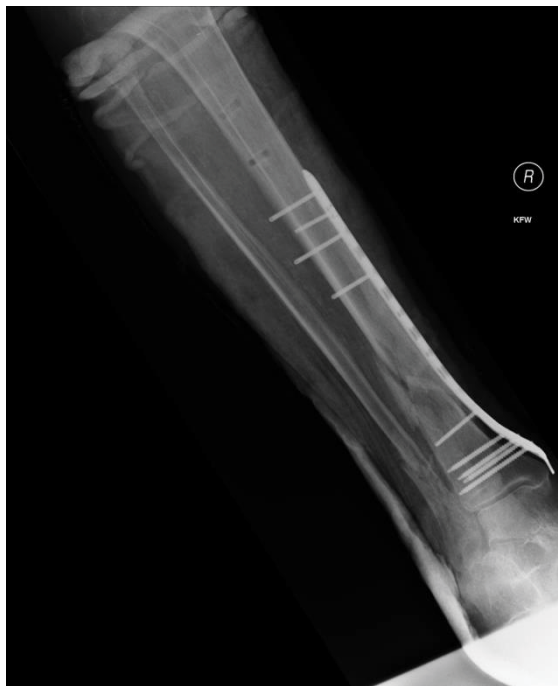
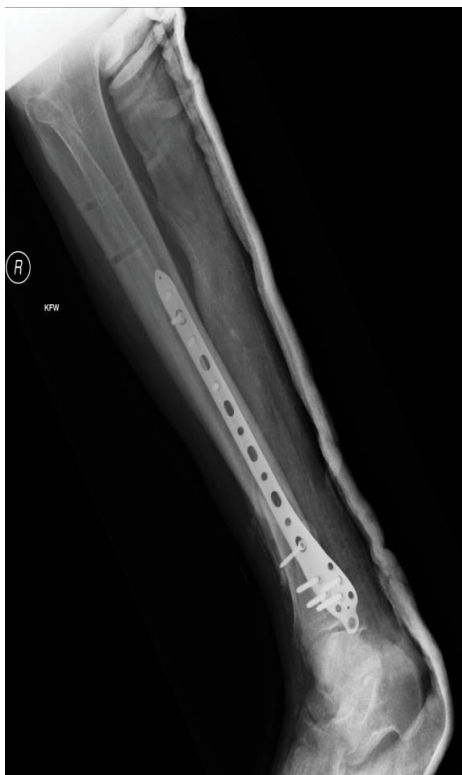Figure 2: Lateral radiograph of distal tibia and fibula fracture.



Figures 4: Postoperative AP radiograph of internal fixation.



Figures 3: Postoperative Lateral radiograph of internal fixation.

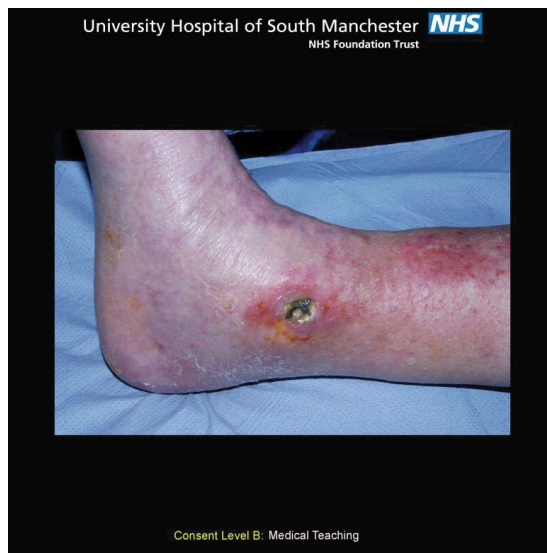

Figure 5: Medical photograph showing skin breakdown over the medial malleolus with exposure of internal fixation in January 2014.

isolated in a side room. However, this failed to resolve his osteomyelitis and pressure ulcer over the medial malleolus. He was given the option of an above knee amputation, and referred to a foot and ankle specialist at University Hospital South Manchester for a second opinion with plastic surgery input.

In May 2014, his tibia non-union secondary to osteomyelitis was stabilised with Ilizarov frame. Calcium sulfate beads containing

gentamicin were applied to the fracture site and the medial malleolus (Figures 6 and 7). Internal fixation was removed during operation. Vacuum therapy was applied over the medial malleolus. Patient had two days of intravenous teicoplanin post-operatively before discharging home.

In theatre environment, Stimulan powder mixes easily and quickly with gentamicin liquid so there is no soaking required. This reduces unnecessary use of precious theatre time during mixing. Calcium sulfate from Stimulan kit can be modified in three sizes of bead (3 mm, 4.8 mm or 6 mm) or as a paste for injection to provide flexibility depending on the size of the defect. In this case, we applied 4.8 mm calcium sulfate beads at both the fracture site and the medial malleolus.

Outcome and follow-up

At six weeks follow-up, most of the calcium sulfate beads were absorbed which was shown radiologically (Figures 8 and 9).

Three months postoperatively, CT scan of lower leg demonstrated callus formation and fracture union (Figures 10 and 11). Further magnetic resonance imaging showed no signs of osteomyelitis.

Tissue viability nurses followed his pressure ulcers. The wound over the medial malleolus healed three weeks after the operation (Figure 12). The heel pressure ulcer was treated with dressings impregnated with surghoney.

Discussion

In an attempt to overcome the issues related to the treatment of osteomyelitis, systems of local antibiotic release have been developed. One of the most commonly used materials is polymethylmethacrylate (PMMA) [5]. It is not biodegradable therefore a second operation is required for it to be removed once the antibiotic is released. If it is left in place, it will prevent bone ingrowth [6] and become a potential space

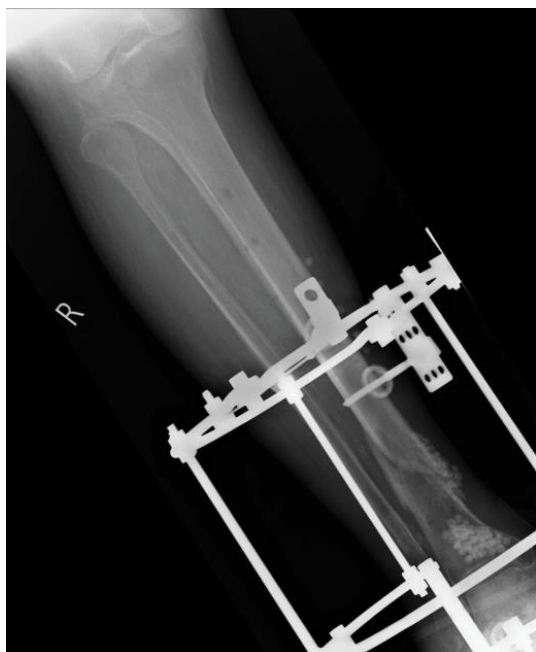
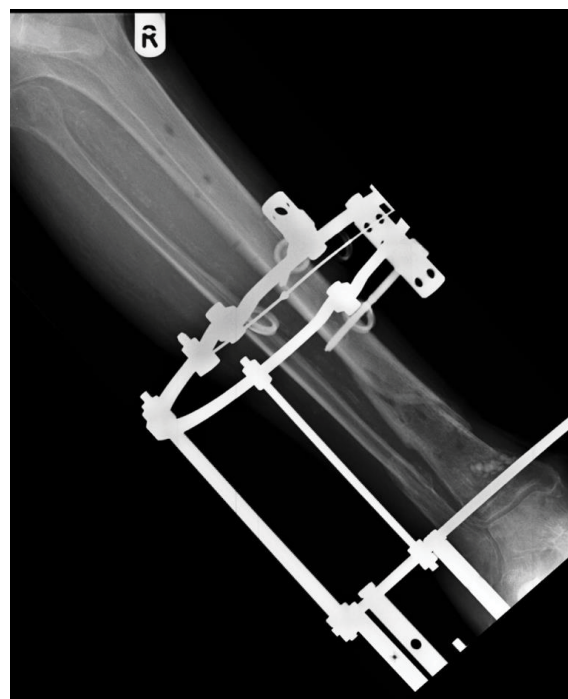
Figure 6: Immediate postoperative AP radiograph of Ilizarov frame in May 2014. Hyperdense areas in the tibia illustrated the areas where Stimulan was applied.




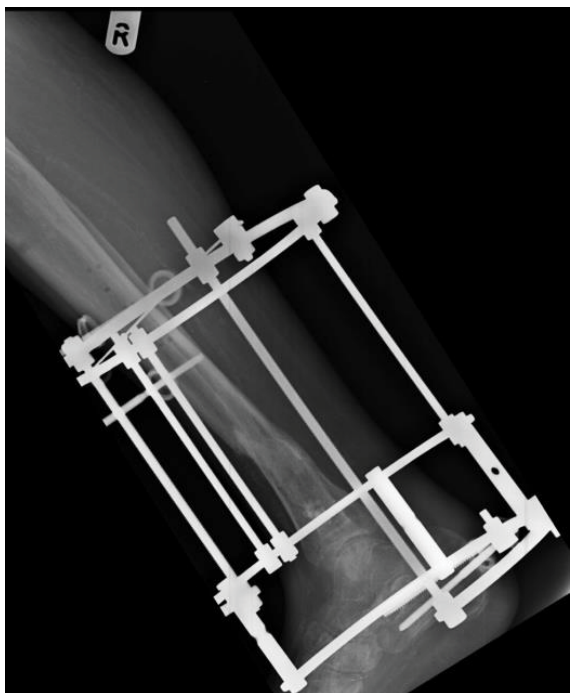
Figure 7: Immediate postoperative Lateral radiograph of Ilizarov frame in May 2014. Hyperdense areas in the tibia illustrated the areas where Stimulan was applied.



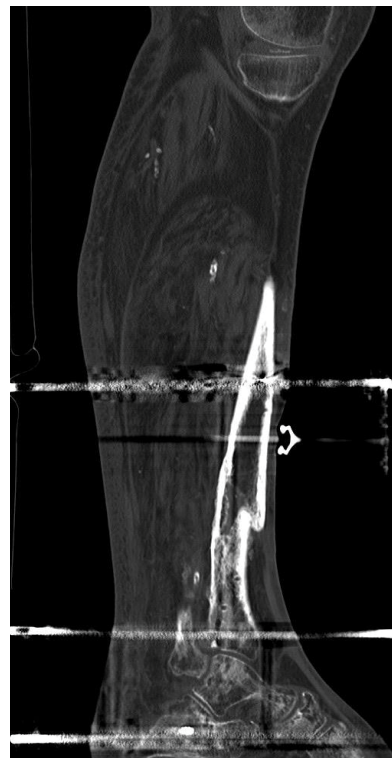
Figures 8: Six weeks postoperative AP radiograph.

for future infection [7].

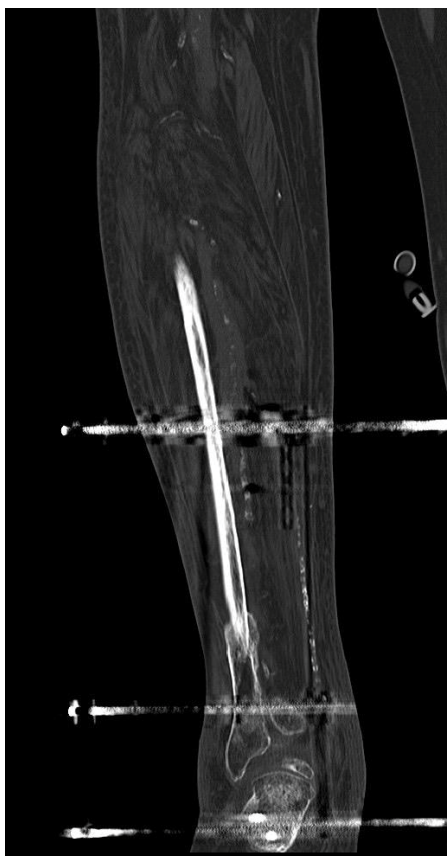
Over the last two decades, several biodegradable and absorbable carriers such as polylactic acid, hydroxyapatite, calcium phosphate and collagen materials have been developed [8]. The advantages of calcium sulfate include its biodegradability, predictable elution properties, osteoconductivity, and ability to fill dead space [9]. Recent studies have shown that osteoblasts attach to and absorb calcium sulfate [10]. It provides an osteoconductive environment for vascular ingrowth. Calcium sulfate has the potential to release effective local antibiotic



Figures 9: Six weeks postoperative Lateral radiograph.



Figures 11: Sagittal CT images showing union of the tibial fracture with Ilizarov frame still in situ in August 2014.



Figures 10: Coronal CT images showing union of the tibial fracture with Ilizarov frame still in situ in August 2014.

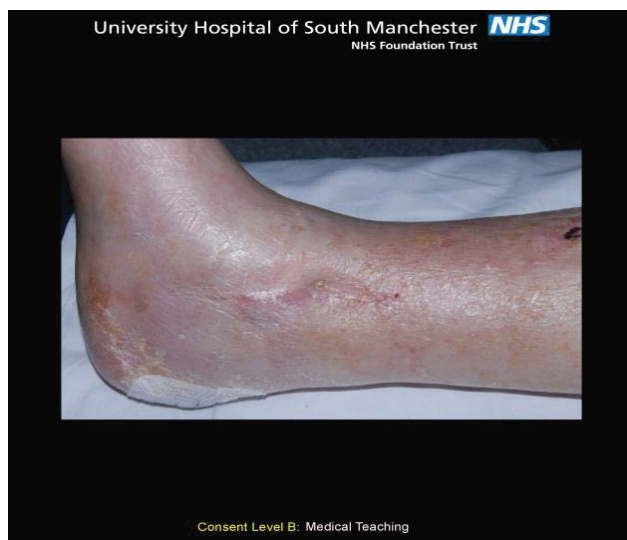

Figure 12: Medical photograph showing skin healed over the medial malleolus.

concentrations for a period of at least forty-two days without affecting the chemical nature and antimicrobial efficacy [11]. Results *in vitro* have revealed that Stimulan admixed with 10% moxifloxacin was very

effective in achieving complete eradication of the causative pathogen in an experimental model of osteomyelitis caused by MRSA [12,13].

Calcium sulfate as a carrier is a new treatment option for osteomyelitis associated with internal fixation. In our experience it has less systemic effects, releases more effective antibiotic concentrations locally, reduces the length of parenteral antibiotic use and reduces the length of inpatient stay.

References

1. Lambe DW, Ferguson KP, Mayberry-Carson KJ, Tober-Meyer B, Costerton JW (1991) Foreign-body-associated experimental osteomyelitis induced with *Bacteroides fragilis* and *Staphylococcus epidermidis* in rabbits. *Clin Orthop Relat Res* 285-294.
2. Mader JT, Shirliff ME, Bergquist SC, Calhoun J (1999) Antimicrobial treatment of chronic osteomyelitis. *Clin Orthop Relat Res*: 47-65.
3. Ceri H, Olson ME, Stremick C, Read RR, Morck D, et al. (1999) The Calgary Biofilm Device: new technology for rapid determination of antibiotic susceptibilities of bacterial biofilms. *J Clin Microbiol* 37: 1771-1776.
4. Panagopoulos P, Tsaganos T, Plachouras D, Carrer DP, Papadopoulos A, et al. (2008) *In vitro* elution of moxifloxacin and fusidic acid by a synthetic crystallic semihydrate form of calcium sulfate (Stimulan). *Int J Antimicrob Agents* 32: 485-487.
5. Regis D, Sandri A, Samaila E, Benini A, Bondi M, et al. (2013) Release of gentamicin and vancomycin from preformed spacers in infected total hip arthroplasties: measurement of concentrations and inhibitory activity in patients' drainage fluids and serum. *ScientificWorldJournal* 2013: 752184.
6. Walsh WR, Morberg P, Yu Y, Yang JL, Haggard W, et al. (2003) Response of a calcium sulfate bone graft substitute in a confined cancellous defect. *Clin Orthop Relat Res* : 228-236.
7. Gitelis S, Brebach GT (2002) The treatment of chronic osteomyelitis with a biodegradable antibiotic-impregnated implant. *J Orthop Surg (Hong Kong)* 10: 53-60.
8. Kanellakopoulou K, Giamarellos-Bourboulis EJ (2000) Carrier systems for the local delivery of antibiotics in bone infections. *Drugs* 59: 1223-1232.
9. Helgeson MD, Potter BK, Tucker CJ, Frisch HM, Shawen SB (2009) Antibiotic-impregnated calcium sulfate use in combat-related open fractures. *Orthopedics* 32: 323.
10. Sidqui M, Collin P, Vitte C, Forest N (1995) Osteoblast adherence and resorption activity of isolated osteoclasts on calcium sulfate hemihydrate. *Biomaterials* 16: 1327-1332.
11. Aiken SS, Cooper JJ, Florance H, Robinson MT, Michell S (2015) Local release of antibiotics for surgical site infection management using high-purity calcium sulfate: an *in vitro* elution study. *Surg Infect (Larchmt)* 16: 54-61.
12. Kanellakopoulou K, Galanopoulos I, Soranoglou V, Tsaganos T, Tziortzioti V, et al. (2009) Treatment of experimental osteomyelitis caused by methicillin-resistant *Staphylococcus aureus* with a synthetic carrier of calcium sulfate (Stimulan) releasing moxifloxacin. *Int J Antimicrob Agents* 33: 354-359.
13. Coetzee AS (1980) Regeneration of bone in the presence of calcium sulfate. *Arch Otolaryngol* 106: 405-409.