

Hepatic Steatosis Grade III

Roever L^{*} and Diniz ALD

Federal University of Uberlândia, Brazil

***Corresponding author:** Leonardo S. Roever-Borges, MHS, Department of Clinical Research, Av. Pará, 1720 - Bairro Umarama, Uberlândia - MG - CEP 38400-902, Brazil, Tel: +553488039878; E-mail: leonardoroever@hotmail.com

Received date: June 13, 2015; **Accepted date:** June 15, 2015; **Published date:** June 22, 2015

Copyright: © 2015 Roever L, et al. This is an open-access article distributed under the terms of the Creative Commons Attribution License, which permits unrestricted use, distribution, and reproduction in any medium, provided the original author and source are credited.

Description

Patient 35 years of age with diagnosis of obesity (BMI: 42), and chronic hypertension.

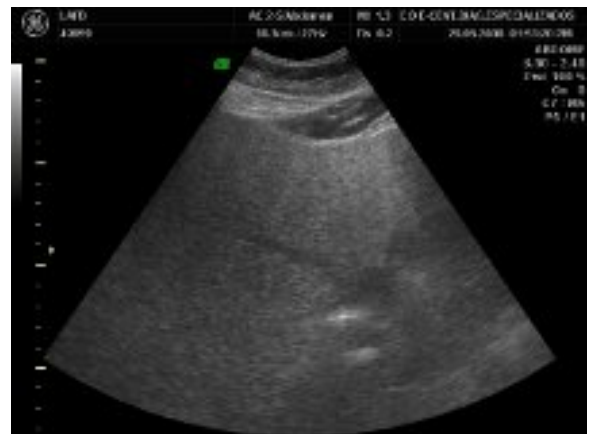


Figure: Image of liver parenchyma with diffuse hyperechogenicity the signals associated with the deletion of important limits the walls of hepatic veins and diaphragmatic line.