

## Comment on Scleral Shield Technique

Tamer Ismail Gawdat\*

Ophthalmology Department, Faculty of Medicine, Cairo University, Cairo, Egypt

\*Corresponding author: Tamer Ismail Gawdat, Ophthalmology Department, Faculty of Medicine, Cairo University, Cairo, Egypt, Tel: +201222146383; E-mail: [tamer.gawdat@yahoo.com](mailto:tamer.gawdat@yahoo.com)

Received date: June 13, 2015, Accepted date: July 27, 2015, Published date: July 31, 2015

Copyright: © 2015 Gawdat TI. This is an open-access article distributed under the terms of the Creative Commons Attribution License, which permits unrestricted use, distribution, and reproduction in any medium, provided the original author and source are credited.

### Short Communication

Evisceration is a commonly performed procedure for treating various end-stage ocular conditions. It aims at the removal of the contents of the diseased eye sparing the sclera. In order to obtain good functional and cosmetic outcomes, an appropriate implant is usually placed within the sclera to augment the orbital volume and enhance the prosthesis motility [1].

Many modifications to evisceration have been reported, mainly posterior and radial sclerotomies [2] as well as scleral quadrisection technique [3]. They all aimed at enhancing implant protection, placing a larger size orbital implant, minimizing the risk of postoperative exposure in addition to obtaining good motility.

The scleral shield is a simple surgical modification during evisceration that aims at providing an extra protective layer for the inserted implant and minimizing the possibility of its exposure without violating the continuity of the scleral shell or resecting the optic nerve [4].

Our published series in 2014 included 30 patients who underwent evisceration and primary porous polyethylene (Medpor®) (Porex Surgical, Inc., College Park, Georgia, USA) ball implantation. Causes of intervention included blind disfiguring and/or painful globes following trauma (15 patients), endophthalmitis (7 patients), and end stage of glaucoma (8 patients).

All of these eyes were eviscerated under general anesthesia using an evisceration spoon to separate the uveal tissue from the scleral shell. The delivery of the globe contents was assisted by suction machine. In the cases that followed, removal of contents was facilitated by injecting saline in the suprachoroidal space using a blunt cannula to induce choroidal detachment. The inside of the globe was then cleaned with a gauze swab making sure that no uveal remnants are left [4].

Porous polyethylene balls were used for all patients. This material is nontoxic, non-allergic, and highly biocompatible with favorable surgical outcomes after implantation [5].

One radial relaxing incision was made on both the nasal and the temporal sides of the eviscerated globe. A sizing ball was used to determine the proper size of the implant where it could be covered by the sclera without tension. Radial incisions were extended until the implant could be inserted. In our original work, the scleral wound edges over the anterior pole of the implant were sutured using 6/0 polyglactin sutures (Vicryl; Ethicon Inc., Bridgewater, New Jersey, USA) [4]. The excess scleral tissue on each side of the implant was excised to form a free scleral graft (Figure 1). This graft was placed over the suture line and fixated by 6/0 Vicryl sutures to the underlying sclera, adding an extra protective layer to the implant (Figure 2). The overlying Tenon capsule and conjunctiva were then closed in separate layers by 6/0 Vicryl sutures [4] (Figure 3). This creates four layers over

the implant; the scleral shell, free scleral graft sutured over the main suture line thus acting like a shield protecting the main wound. The tenon capsule and finally the conjunctiva follow this.

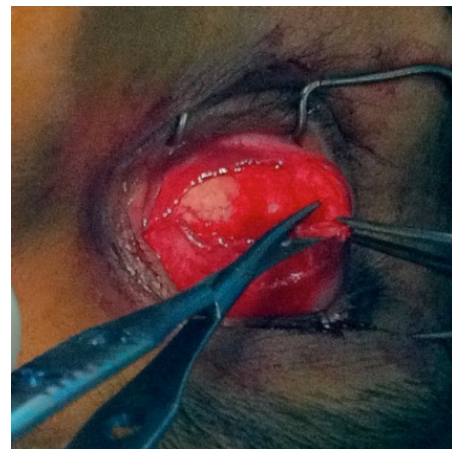

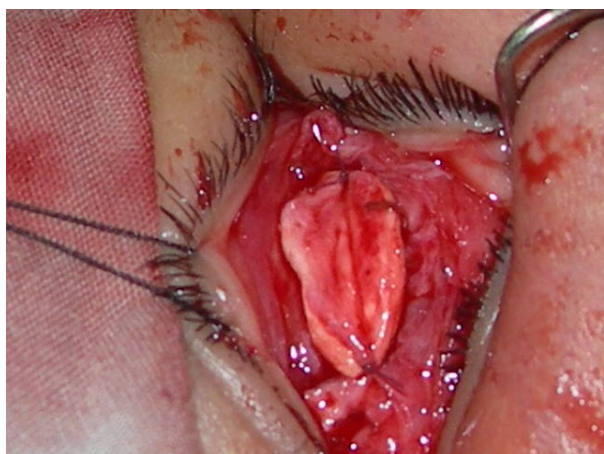
Figure 1: Scleral tissue excision from implant.

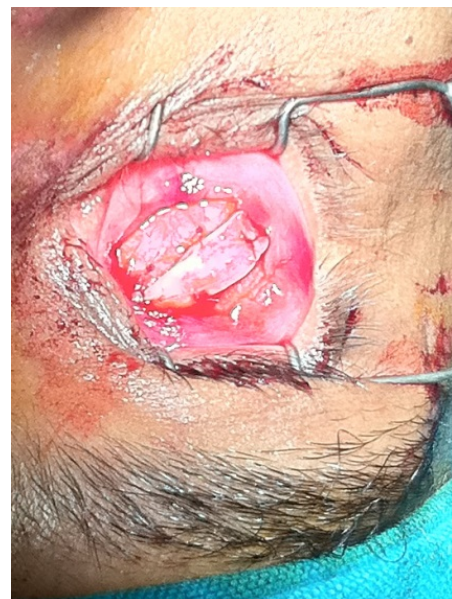
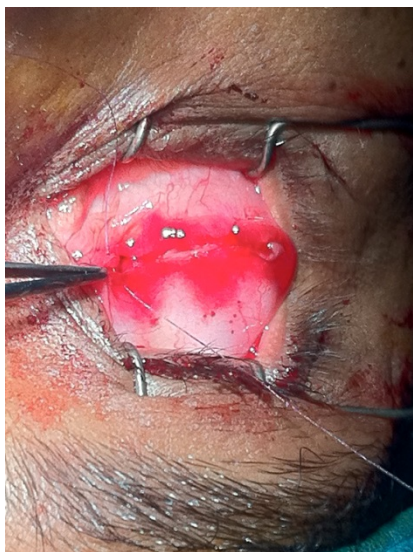
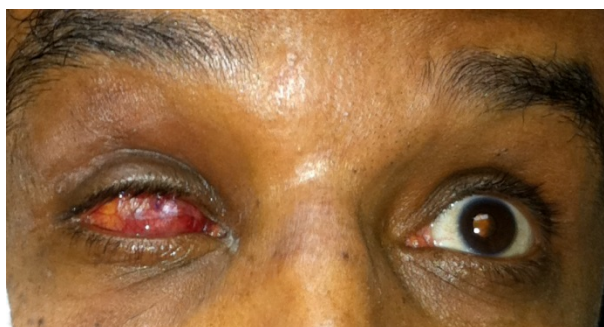Figure 2: Graft placement and fixation over the suture line.



**Figure 3:** Closing of Tenon capsule and conjunctiva by 6/0 Vicryl sutures.



**Figure 4:** Sutures of the graft and main suture lines.



**Figure 5:** Wound integrity and implants protection.

In the 20 cases that followed the published work, a fine modification was done. Excess scleral tissue was resected from one side only thus providing a bigger graft instead of resecting two small free scleral grafts from both sides of the implant. It is believed that this bigger single graft has considerable advantages as it makes this step of shorter duration and it covers not only the suture line but also the whole dome of the implant. Additionally, the sutures of the graft are away from the main suture lines of the other three layers (Figure 4). Thus enhancing wound integrity and implants protection [4] (Figure 5).

It was possible to place size 18 and 20 mm implants in most patients of the original work as well as the 20 cases that followed, only one patient received a 16 mm implant and 2 patients received 22 mm implants due to exceptionally large globes [4].

Although porous polyethylene implants reported high rates of postoperative exposure [5], neither the 30 eyes included in the original research nor the cases done later using the modified scleral wide patch technique had implant exposure over the follow-up period: ( $6.34 \pm 0.5$  years) for the former and ( $2 \pm 0.5$  years) for the latter. None of the patients developed conjunctival granulomas, cysts, or infection. All patients were cosmetically satisfied [4].

Scleral free graft adds an extra layer to reinforce protection of the inserted implant in addition to the usual covering layers, i.e., sclera, Tenon capsule, and conjunctiva. The relatively small size of the graft ( $3 \times 7$  mm maximum) as well as 2 vascular layers coverage allows graft survival. The placement of this graft covers and supports the suture line and reduces its friction with the applied prosthesis later on, hence minimizing the exposure rate. The additional advantage of keeping the integrity of the sclera ensures proper implant placement and better protection, hence reducing the possibility of its migration.

The graft placement also provides more contact with the back of the ocular prosthesis placed postoperatively and it is believed to improve the prosthesis motility and cosmetic results, however, this is still under study and validation.

In conclusion, scleral shield is a simple surgical step that reinforces the scleral wound over the implant, adding a fourth protective layer while maintaining the continuity of the sclera with promising results.

Although in the original study integrated balls were used, the technique is feasible for all types of implants with comparable outcomes. The small sample size was one of the study limitations, yet this has become a regular practice, this series had reached 50 cases with favorable outcomes. Over the past 6 year of follow up for the studied cases, no exposure or complications were reported. However, a longer period of follow-up will also validate the efficacy of this technique in preventing implant exposure as most implants were around 18-20 mm in diameter. Evaluation of this technique is still required for implants of larger sizes.

## References

1. Viswanathan P, Sagoo MS, Olver JM (2007) UK national survey of enucleation, evisceration and orbital implant trends. *Br J Ophthalmol* 91: 616-619.
2. Stephenson CM (1987) Evisceration of the eye with expansion sclerectomies. *Ophthal Plast Reconstr Surg* 3: 249-251.
3. Lee SY, Kwon OW, Hong YJ, Kim HB, Kim SJ (1995) Modification of the scleral openings to reduce tissue breakdown and exposure after hydroxyapatite implantations. *Ophthalmologica* 209: 319-322.

4. Gawdat TI, Ahmed RA (2014) Scleral shield: primary results of a new surgical Technique in augmenting porous orbital implant protection. Eur J Ophthalmol 24: 948-952.
5. Jung SK, Cho WK, Paik JS, Yang SW (2012) Long-term surgical outcomes of porous polyethylene orbital implants: a review of 314 cases. Br J Ophthalmol 96: 494-498.