

## Retrospective Study of Periocular Non Melanoma Skin Cancer Treated with the Combination of IFN alpha2b and Gamma (HeberPAG)

Garcia-Vega Yanelda<sup>1</sup>, Anasagasti-Angulo Lorenzo<sup>2</sup>, Valenzuela-Silva Carmen<sup>1</sup>, Navarro-Mestre Marianlie<sup>3</sup>, Maribeth-Ordoñez Sintia<sup>3</sup>, Acosta-Medina Doraiquis<sup>3</sup>, Rodríguez-García MA<sup>3</sup>, Collazo-Caballero Sonia<sup>3</sup>, Tijerino-Arrieta Edgar<sup>4</sup>, Duncan-Roberts Yaquelin<sup>1</sup>, Arteaga-Hernández Ernesto<sup>3</sup>, Jiménez-Barban Yanisel<sup>6</sup>, Vila-Pinillo Dayami<sup>5</sup>, Torres-Valerio Esteban<sup>5</sup>, Vazquez-Castillo Mariela<sup>7</sup>, López-Saura Pedro<sup>1</sup> and Bello-Rivero Iraldo<sup>1</sup>

<sup>1</sup>Center for Genetic Engineering and Biotechnology (CIGB), Clinical Research Department, Calle 134 entre 23 y 25, Cubanacán, Playa, Havana, Cuba

<sup>2</sup>National Institute of Oncology and Radiobiology, Vedado, Havana, Cuba

<sup>3</sup>"Hermanos Ameijeiras" Hospital, Dermatology Department, San Lázaro y Belascoain, Vedado, Havana, Cuba

<sup>4</sup>Policlinic "Noelio Capote", Jaruco, Mayabeque, Cuba

<sup>5</sup>Policlinic "Luis Li Trejent", Guines, Mayabeque, Cuba

<sup>6</sup>Ophthalmologic Center, "Enrique Cabrera" Hospital, Havana. Calle E y Aldabó. Alta Habana. Boyeros, Havana, Cuba

<sup>7</sup>Patent Department, Center for Genetic Engineering and Biotechnology (CIGB), Clinical Research Department, Calle 134 entre 23 y 25, Cubanacán, Playa, Havana, Cuba

\*Corresponding author: Iraldo Bello Rivero, Center for Genetic Engineering and Biotechnology, Clinical Research Department. P.O. Box 6332, Havana, Cuba, Tel: (53) - 7 - 2087379; Email: iraldo.bello@cigb.edu.cu

Received date: Aug 07, 2015; Accepted date: Sep 21, 2015; Published date: Sep 26, 2015

Copyright: © 2015 Yanelda GV et al. This is an open-access article distributed under the terms of the Creative Commons Attribution License, which permits unrestricted use, distribution, and reproduction in any medium, provided the original author and source are credited.

### Abstract

**Background:** Non-melanoma skin cancer can cause considerable morbidity when located on the eyelids and periocular skin. Basal cell carcinoma is the commonest periocular malignancy and although metastases are extremely rare, local invasion can cause significant and sometimes severe morbidity. Interferons may provide a non-surgical approach to the management of these tumors. The aim of this work was to evaluate retrospectively, the effect of a formulation containing IFNs alpha2b and gamma in synergistic proportions (HeberPAG) on patients with periocular NMSC.

**Methods:** The patients were identified from the data base from Department of Peripheral Tumors at "National Institute of Oncology and Radiobiology" in Havana; Dermatological Department at "Hermanos Ameijeiras" and "Enrique Cabrera" Hospitals; and policlinics from rural zone in Mayabeque; Cuba. The applications of IFN combination were practiced by medical doctors specialized in dermato-oncology. The employed doses for IFN combination were from  $0.875 \times 10^6$  IU to  $27 \times 10^6$  IU.

**Results:** The series include 18 basal cell carcinoma and 3 squamous cell carcinoma of the skin with predominant clinical forms mixed (33.3%) and nodular (38.1%), 3 cases were terebrant, 2 ulcerated and 1 pigmented. The median time of tumor evolution was 16.5 months with an initial diameter of 8.25 cm. At week 12 after the end of treatment, a 47.6% complete response rate was obtained. A partial response was achieved in 5 patients (23.8%). A high response rate was obtained with overall response (CR+PR) in 71.4%. All patients reported at least 1 adverse event. The most frequent (>20%) were fever, chills, anorexia, cephalaea, perilesional erythema and edema, asthenia, arthralgia and general discomfort.

**Conclusions:** HeberPAG is an alternative useful to surgery in patients with periocular non-melanoma skin cancer when other therapies have failed or are not possible. The encouraging result justifies further confirmatory trials in periocular region.

**Keywords:** Periocular; Non-melanoma skin cancer; IFNs

### List of Abbreviations

BCC: Basal Cell Carcinoma; CR: Complete Response; CIGB: Center for Genetic Engineering and Biotechnology; IFN: Interferon; IU: International Units; NMSC: Non-Melanoma Skin Cancer; OR: Overall Response; PR: Partial Response; PDT: Photodynamic Therapy; SCCS: Squamous Cell Carcinoma of the Skin; RT: Radiotherapy; SD: Stable Disease

### Background

The most common form of skin cancer is basal cell carcinoma (BCC), accounting for 80-90% of skin malignancies [1,2]. BCC is the commonest periocular malignancy and although metastases are extremely rare, local invasion can cause significant and sometimes severe morbidity [3,4]. BCC can cause considerable morbidity when located on the eyelids (80-95%). The tumor arises most commonly in the lower eyelid (50-72 %), followed by the medial canthus (9.6-27.6%), the upper eyelid, and the lateral canthus [5]. Review of the literature showed all authors agreed that BCC occurs most commonly

in the lower eyelid. However, the remaining anatomical location and the incidence of occurrence differ from author to author.

Squamous cell carcinoma of the skin (SCCS) is an invasive epithelial malignancy showing keratinocytic differentiation. It is the second most common malignant neoplasm of the eyelids, comprising 5-10% of all eyelid malignancies. The incidence for eyelid SCCS has been reported to be between 0.09 and 2.42 cases per 100 000 population [6].

It has been suggested that some as yet unidentified mesodermal factor(s) may work as an intrinsic promoter in the pathogenesis of BCC, because it is strongly dependent on its surrounding stroma, metastasizes very rarely, and BCC transplants can survive only if transplantation is performed with the surrounding stroma [7]. Although UV radiation is accepted as the main cause of BCC, sun exposure only partly explains the etiology of periorbital BCC. Although the mechanism is unknown, trauma, chronic irritation, inflammation, and scars due to burns or other causes have been implicated as etiologic factors in some BCCs [8]. Similar pathogenesis for SCCS has been described [5].

Recurrence of BCC is not uncommon, approximately 12% with most treatment modalities. An estimated 40%-50% of patients with a primary carcinoma will develop at least one or more further BCC within 5 years [9]. The rate of recurrence is positively correlated with tumor size and facial location. Up to 90% of recurrent cases occur on the head and neck. Aggressive histological BCC types are more prone to incomplete excision, recurrence, and metastasis. Some techniques, as cryosurgery, curettage, radiotherapy (RT), photodynamic therapy (PDT), do not allow histological confirmation of tumor clearance [10].

Tumors with aggressive histology tend to recur insidiously without early symptoms, leading to a delay in recognition that may compound the challenge of management. In a study of baso-squamous tumors, recurrence predictive factors included male gender, positive resection margins, and perineural or lymphatic invasion [11]. Perineural spread is reported to occur in up to 14% of facial SCCSs. The risk of recurrence has been reported to be around 50%, in cases of head and neck SCCS with perineural invasion treated by simple excision only [12]. Postoperative radio-therapy is recommended in all patients with asymptomatic microscopic perineural invasion [13], since the results of treatment are poor, once clinical signs or symptoms of perineural spread have developed.

Surgical excision remains the mainstay of treatment, and excellent results are obtained if the tumor is completely removed [14]. BCC have traditionally been excised with 3-4 mm margins, combined with primary repair. When the eyelid margin is involved, these excision margins often result in a defect which requires sophisticated reconstructive surgery as direct closure is only possible with the smallest lesions. However, in many patients the excision of BCCs with 4 mm margins results in the removal of significant amounts of normal tissue [15].

Radiotherapy, cryotherapy, laser ablation, PDT, chemotherapy, and immunotherapy have all been described and may be useful for inoperable or widespread disease [16]. When advanced SCCS requires systemic palliation, treatment with conventional chemotherapy, such as cisplatin, is often precluded by patient's age or medical comorbidities [17].

Imiquimod may be an alternative to surgery for patients with primary facial superficial BCCs, but long-term clearance is not as good as some of the other treatment modalities. It is not recommended for

recurrent disease but is a good treatment option for elderly frail patients and patients who are not keen on surgical treatment [18].

Due to the clearance rates being lower than for surgical treatments, PDT is not generally recommended for management of nodular BCCs on the head or neck. While primary superficial BCCs on the face may be amenable to treatment is not recommended for recurrent disease [19].

Thus, conservative (medical) approaches are desirable, especially in the eye region with its delicate structures. One candidate for a non-surgical treatment modality is immunotherapy.

Intralesional injections of interferon (IFN) were reported to be effective in treating BCC in an initial study in 1986. The initial study and a subsequent multicenter study of similarly IFN-treated BCCs (superficial and nodular) resulted in 100% and 81% cure rates, respectively. The perilesional technique of injecting IFN appears to be more efficacious than the intralesional method based on cure rates previously described in other studies [20]. The use of IFNs in the treatment of SCCS has been also reported, with a broad range of response (60%-100%) and low recurrence rate (4%) [20-22]. IFNs have been employed in the treatment of eyelids BCC [23].

Synergistic effects of combined treatment with IFN-alpha2b and IFN-gamma have been noted, suggesting that they operate on similar genes through different mechanisms. The cooperative induction of cytokine-specific transcription factors is one mechanism for producing reinforcing effects of distinct cell-surface ligands while still maintaining the specificities of the individual inducers [24]. A combination of IFN-alpha2b and IFN-gamma (HeberPAG, Heber Biotec SA, Havana, Cuba) applied peri- and intralesionally 3x/wk for three weeks was used for the treatment of 12 BCCs and 4 SCCSs in 16 elderly patients with extensive and recurrent tumors who had previously failed other treatments. Almost half of the patients had complete response to the treatment [25].

We refer a retrospective study of near to the eye (peri-ocular) NMSC cancer treated with HeberPAG.

## Methods

### Retrospective study

This was a retrospective study of patients treated with Heberpag (HeberBiotec, SA, Havana; approved for clinical use in basal cell carcinoma of any subtype, localization and size by Cuban Regulatory Authority in 2008). The study was conducted with the consent of ethical committees from the participating institutions. The ethical committees from the National Institute of Oncology and Radiobiology (also approved the research in the "Noelio Capote" policlinic); "Hermanos Ameijeiras" Hospital, "Enrique Cabrera" Hospital and "Luis Li Trejent" policlinic approved the research.

Adult patients (18 years of age or older), who signed their informed consent to receive the treatment with HeberPAG, were identified from the data base from department of dermatology at Department of Peripheral Tumors at National Institute of Oncology and Radiobiology in Havana (5-year follow-up period, January 2004 to January 2009), Dermatological Department at "Hermanos Ameijeiras" Hospital (2-year follow-up period, July 2010-July 2012), and Ophthalmologic Center at "Enrique Cabrera" Hospital, policlinics "Noelio Capote", community of Jaruco and "Luis Li Trejent", community of Guines (rural zones), in Mayabeque (1-year follow-up period -July 2011-July

2012). Each patient had a medical history, a physical examination, a skin examination for disease assessment, documentation of concurrent medications, and laboratory tests (hemoglobin determination and platelets and white blood cell total and differential counts). A punch biopsy of not more than 25% of the total lesion size confirmed the diagnosis before enrolment.

The trial protocol was approved by the Ethics Committee and the Scientific Review Board of the “Hermanos Ameijeiras” Hospital, Havana, in accordance with the ethical principles stated in the Declaration of Helsinki.

We included all patients both genders, older than 18 years, with periocular (near to the eye), histologically and clinically proven non-melanoma skin cancer (BCC or SCCS), who gave their written informed to receive the treatment of the stabilized pharmaceutical formulation containing a synergistic combination of 3.5 MIU IFNs alpha2b and gamma and sodium hydrogen-phosphate, dextran 40, sodium chloride, and human albumin (HeberPAG, Heber Biotec SA, Havana, Cuba). Treated patients were those with BCC or SCCS of every subtype and size, localized periocular. The study included patients having additional therapies (ChT) during the course of treatment with HeberPAG.

All the patients treated in the medical cabinets (3 times a week), suited in the health institution participating in the treatment of patients.

We recorded the patients’ age at the time of treatment, periocular location of the skin lesion, complications of the treatment, the final ophthalmic side-effects and the clinical resolution of the lesion following completion of HeberPAG therapy. The time from the completion of treatment to the last follow-up was recorded. The institutional ethics review board approval was granted for this retrospective study.

The applications of IFN combination were practiced by medical doctors specialized in dermato-oncology with practical experience in the administration of the product. The employed doses for IFN combination were from  $0.875 \times 10^6$  IU to  $27 \times 10^6$  IU.

The doses and therapeutic schedule of chemotherapy followed the established therapeutic guidelines for these tumors. The chemotherapeutic doses were calculated following the Calver procedure [26]. The indicated cytostatic drugs were: Cisplatin: 50-100 mg/m<sup>2</sup>; Carboplatin: 100 mg/m<sup>2</sup>; Adriamycin: 50-70 mg/m<sup>2</sup>.

Subjects were examined as outpatients. At each visit during and after treatment, the investigators assessed the lesions and evaluated tissue conditions. Patients’ follow-up examinations were done after treatment onset. Lesion diameter (d) measurements were done using a Folding Magnifier or ruler and documented with photographs. Twelve weeks following therapy, the treatment sites were examined for clinical and/or histological evidence of remaining tumor. The response was measured according to Response Evaluation Criteria In Solid Tumors (RECIST). It was categorized as complete response (CR): Disappearance of all target lesions; partial response (PR): at least a 30% decrease in the sum of diameters of target lesions; Progressive Disease (PD): at least a 20% increase in the sum of diameters of target lesions and stable disease (SD): neither sufficient shrinkage to qualify for PR nor sufficient increase to qualify for PD. The complete response (CR) was confirmed by computerized axial tomography in bone infiltration cases.

Long-term evaluation every 3 months for 5 year included clinical assessment for local relapses and tumor development at other locations. Response rates were based on the tumor area by measuring the diameter.

### Statistic

Data were double entered and validated on Microsoft Access and then imported into SPSS version 13.0 for further analysis. Continuous variables are expressed as median (25<sup>th</sup> and 75<sup>th</sup> percentiles) and categorical variables are given as absolute values and percentages. The Bayesian confidence intervals were estimated for the proportions of clinical response. A Bayesian logistic regression was adjusted to explore the relationship between clinical response and baseline/demographics characteristic.

### Results

#### Patients’ demographic and baseline characteristics

Table 1 showed the characteristics of the study sample. Twenty-one patients were selected for this series. Nine were male and twelve female. The median age was 66 years (25<sup>th</sup>-75<sup>th</sup> percentile: 58-80). Almost patients were white (90.5%).

Variable		Frequency	%
Sample size		21	
Gender	Male	9	42.9
	Female	12	57.1
Skin color	White	19	90.5
	Mestizo	2	9.5
Smoking habits	Yes	3	14.3
	No	18	85.7
Alcoholism	Yes	4	19.0
	No	17	81.0
Age (years)		66 (58-80)	
Qualitative data are in (%) and quantitative in median (25 <sup>th</sup> -75 <sup>th</sup> percentile).			

**Table 1:** Characteristics of the study sample.

There was not observed prevalence for smoking (14.3%) or alcohol consumption (19.0%). The series include 18 BCC and 3 SCCS with predominant clinical forms nodular (38.1%) and mixed (33.3%), 3 cases were terebrant, 2 ulcerated and 1 pigmented. The median time of tumor evolution was 16.5 (25<sup>th</sup>-75<sup>th</sup> percentile: 12-36) months with an initial diameter of 10 cm (25<sup>th</sup>-75<sup>th</sup> percentile: 5.5-11) and 16.5 months of disease evolution. Ten patients had been recurrent to other previous treatments, among them the most frequent were surgery (80%) and radiotherapy (60%). For these results see Table 2.

Biopsy confirmation was done for all patients. Three millimeters punch biopsy was done and fixed in 5% formalin and paraffin-embedded for routine light microscopy.

Variable		Frequency	%
Sample size		21	
Type	BCC	18	85.7
	SCCS	3	14.3
Clinical form	Nodular	8	38.1
	Mixed	7	33.3
	Terebrant	3	14.3
	Ulcerated	2	9.5
	Pigmented	1	4.8
Previous recurrence		10	47.6
Surgery		8	80.0
RT		6	60.0
Cryosurgery		1	10.0
5 fluorouracil		1	10.0
Time of evolution (months)		16.5 (12-36)	
Initial high diameter (cm)		10 (5.5-11)	
Qualitative data are in n (%) and quantitative in median (25 <sup>th</sup> -75 <sup>th</sup> percentile).			

**Table 2:** Initial assessment of the lesions.

### Treatment compliment

Most of patients (66.7%) received dose  $\leq 3.5 \times 10^6$  international units (IU). More than 50% of patients received HeberePAG perilesioanly (Table 3). The 76% of patients completed the treatment, 5

Variable		Frequency	%	95% C.I.	95% C.I. for OR
Sample size			21		
Clinical response	CR	10	47.6	(27.1-68.2)	(52.3- 89.0)
	PR	5	23.8	(7.5-41.9)	
	SD	5	23.8	(7.5-41.9)	
	PD	1	4.8	(0.2-17.6)	
Esthetic	Good	10	47.6	(90.4-99.9)	
CR: Complete Response; PR: Partial Response; SD: Stable Disease; PD: Progressive Disease; C.I: Confidence Interval; OR: Objective Response					

**Table 4:** Clinical and Esthetic response.

The probability that objective response would be more than 50% is high (Table 4). A significant influence of baseline and demographic characteristics was not observed respect to CR neither OR. Male patients obtained more CR (66.7%). One of the 3 patients with SCCS tumor had CR. Patients with terebrant lesions did not have CR. The duration of responses have a mean of 26.2 months with a median of 22.6 months. Figures 1-4 show some lesions before and after therapy.

patients interrupted for different causes: death; the product did not penetrate the tumor tissue and spilled off; voluntary abandonment, severe adverse event; and the use of unpermitted drugs.

		Frequency	%
Sample size		21	
Dose	$\leq 3.5$	14	66.7
	(3.5-7.0]	1	4.8
	(7.0-10.5]	2	9.5
	>10.5	4	19.0
Interruption		5	23.8
Administration route	Intralesional	7	33.3
	Perilesional	13	61.9
	Both	1	4.8

**Table 3:** Data about treatment.

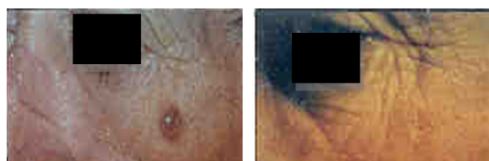All the patients were indicated dipyrone or paracetamol associated to the difenhidramine for the relief of the adverse events. Patients maintained during all the treatment time, the specific drugs for the control of the concurrent illnesses.

### Efficacy analysis

Clinical results are summarized in Table 4. At week 12 from the end of treatment, a 47.6% complete response (CR) rate was obtained. A partial response (PR) was achieved in 5 patients (23.8%). A high response rate was obtained with overall response (OR=CR+PR) in 71.4%.

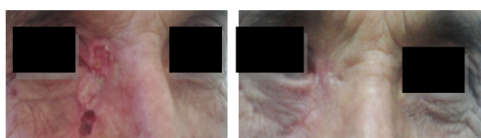
### Safety evaluation

The complications or adverse reactions are presented in the Table 5. All patients reported at least 1 adverse event. The most frequent (>20%) were fever, chills, anorexia, cephalgia, perilesional erythema and edema, asthenia, arthralgia and general discomfort.



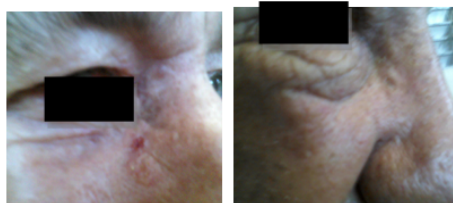
**Before treatment After treatment**

**Figure 1:** Patient (M, 65 years old) with nodular BCC treated with 3,5 MIU HeberPAG perilesional 3 time a week × 3 consecutive weeks with CR.



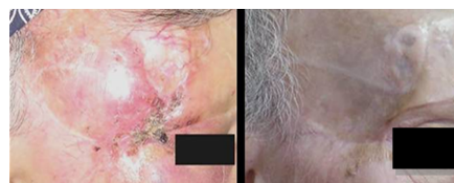**Before treatment After treatment**

**Figure 2:** Patient (M, 66 years old) with recurrent SCCS after surgery, with CR after HeberPAG treatment.



**Before treatment After treatment**

**Figure 3:** Patient (M, 77 years old) with BCC in medial canthus, with CR after HeberPAG treatment.



**Before treatment After treatment**

**Figure 4:** Patient (F, 68 years old) with advanced, recurrent and infiltrative BCC (previous treatments: surgery, RT, bone resection), treated with HeberPAG 10 M+cisplatin. The tumor achieved partial response (remained nodular lesion in upper-eyelid was excised with free borders).

	Frequency	%
Sample size		21
Fever	14	66.7
Chills	12	57.1
Anorexia	8	38.1
Cephalaea	8	38.1
Erythema/ perilesional edema	6	28.6
Asthenia	6	28.6
Arthralgia	5	23.8
General discomfort	5	23.8
Diarrhea	4	19.0
Myalgia	3	14.3
Vomiting	3	14.3
Decreased leukocytes	3	14.3
Chemosis	2	9.5
buccal dryness	2	9.5
Somnolence	2	9.5
Nauseas	2	9.5
Cardiac decompensating	2	9.5
Flu	2	9.5
Weakness	1	4.8
Cerebral ischemia	1	4.8
Pain	1	4.8
Sepsis	1	4.8
Abulia	1	4.8
Dyspnea	1	4.8
Arrhythmia	1	4.8

## Discussion

The management of periocular non melanoma skin cancer (NMSC) depends fundamentally from their aggressiveness, magnitude of infiltration, tumor size, and/or resistance to standard treatment, physical state of the patient, etc. The surgical resolution could be, in some cases, an effective treatment; nevertheless, in most cases, with additional reconstructive surgery, that takes more money and time. The reconstruction in the affected zone may cause, eyelid retraction, cicatricial ectropion or entropion, ptosis, lagophthalmos, dry eye, tumor recurrence, trichiasis, infection, graft failure, scarring and hyper or hypopigmentation [27,28].

On the other hand, patients with several recurrences and/or resistance to other treatment cannot be tributaries of other therapies.

There has been growing interest in the use of immunotherapy as nonsurgical options for NMSC. Periocular skin lesions specially will benefit from immunotherapy, however scarce data about this topic are found in the literature.

Dyspepsia	1	4.8
Weight loss	1	4.8
Abdominal pain	1	4.8
Bone pain	1	4.8
Shortness of breath	1	4.8
Decreased platelet	1	4.8
Facial edema	1	4.8
Pruritus	1	4.8
Insomnia	1	4.8
Acute hypertension	1	4.8
Elevated ALT	1	4.8

**Table 5:** Adverse events.

We set out to share our experience using HeberPAG, a new pharmaceutical combination of IFNs alpha2b and gamma and recount the efficacy of the treatment and frequency and severity of the side effects associated with this therapy with a number of different periocular skin lesions. The number of patients in this study was small, and the study has limitations arising from its retrospective nature.

In the treated cases, BCC was more frequent than SCCS. The predominant clinical forms were nodular and mixed, with median tumors size of 8.25 cm of diameter and some with large extensions out of the periocular zone. The risk factors for the subclinical large extension of such tumors include tumor diameter over 2 cm, localized in the central part of the face or ears, long evolution time, incomplete eradication of the tumor, and perineural or perivascular infiltration. The extensive tumor (>4 cm) or irregular edges associates more often with residual positive margins after surgical excision and have higher rate of recurrence than the smallest or well defined tumors [11].

Most patients suffered of concurrent cardiovascular or respiratory, or digestive illnesses, or diabetes, in concordance with epidemiological characteristics of Cuban population for these ages [29]. The concomitant treatment followed by patients apparently did not influence the results obtained with HeberPAG administration.

With the HeberPAG treatment was achieved an OR in 71.4% of cases (CR 47.6%+PR 23.8%). The responses in these so difficult to treat cases, even low or partial or the stabilization deserve the attention of international community because they are patients without other treatment options.

Similar results are infrequent in the literature. Recently, FDA has approved Vismodegib for the treatment of advanced basal cell carcinoma [30]. This product functions as an inhibitor of Hedgehog Pathway. When comparing the efficacy of Vismodegib vs HeberPAG in the treatment of periocular non-melanoma skin cancer (this report, OR=75.4 %; with duration of the responses=22.6 months) or as showed Anasagasti et al. [25] (OR=87.0 %; 47% CR, 40% PR and 13% stable disease, with duration of the responses=38 months) in advanced non-melanoma skin cancer; is evident that HeberPAG is superior in clinical effect than Vismodegib (OR=55%; with duration of response 9.5 months). Vismodegib adverse reactions were reported in more than 30% of patients included muscle spasms, alopecia, taste disturbance,

weight loss, and fatigue. Serious adverse events were reported in 25% of patients [31]. However, HeberPAG is a substantial safe drug, with transient mild adverse reactions (flu-like symptoms), which can be greatly reduced by pretreatment medications.

Similar reports were obtained in patients with less aggressive tumors, of lower size, without exhausting other therapeutic possibilities or that failed treatment one time either employing IFN- $\alpha$  along [32], combined with chemotherapy [33] or with other procedures [23], all of them with variable outcomes.

Imiquimod may be an alternative to surgery for patients with primary facial superficial BCCs, but long-term clearance is not as good as some of the other treatment modalities. It is not recommended for recurrent disease but is a good treatment option for elderly frail patients and patients who are not keen on surgical treatment [18]. Nodular BCC is more difficult to treat with imiquimod, most likely because of the skin barrier and the deeper localization of tumour cells [34].

Due to the clearance rates being lower than for surgical treatments, PDT is not generally recommended for management of nodular BCCs on the head or neck. While primary superficial BCCs on the face may be amenable to treatment is not recommended for recurrent disease [9]. Topical 5-Fluorouracil 5% (Efudex) is sometimes used to treat small, superficial BCCs and should only be used on low risk sites. It therefore is not recommended in the management of facial BCCs [35].

It was reported high percentages of complete sustained response for 5 years, during the treatment of invasive recurrent NMSC with chemotherapy of the cantus medium and orbit [35] but these cases were not of the magnitude of reported in our series of cases. Besides, the literature reports a high percentage of relapses before 12 months after treatment end. Additionally, the 50% of NMSC that recurred did during the two first years and a 66% during 3 year, after being treated [36]. Even in the case that some one relapsed, it would be possible to repeat the treatment and to achieve a new period of diseases stabilization without arriving to major surgery.

The adverse events reported in this study are similar to the described for the biosimilars reported in the literature, as for type of adverse event, intensity and relation of causality, what indicates us that our synergistic formulation of IFNs possesses similar therapeutic safety profile as other market pharmaceutical presentation of IFNs.

The frequency of adverse events and its small magnitude, as well as the clinical effect of HEBERPAG, suggest that this new IFN formulation is harmless and sure, being able to be employed in similar therapeutic designs and prolonged treatment schedules, with the aims to offer to these patients an efficacious and safe therapeutic option.

Mohs surgery provides the best chance of cure for all BCCs arising on the face with 5-year recurrence rates of anything up to 6.5% [37]. However, due to time and cost limitations, it should be reserved for the treatment of high-risk primary or recurrent BCCs on the face.

HeberPAG treatment may be preferable to surgery in patients with poor hemostasis, including those using anticoagulants. Other situations include patients with a higher risk of poor wound healing, such as patients with diabetes and the older population, and those for which surgery would be deforming or would destroy function. Another benefit of HeberPAG treatment is that it may allow more selective destruction of tumor cells versus benign cells compared with other destructive/ surgical treatments.

An additional benefit of this technique includes restoration of normal skin margins, which is cosmetically pleasing and can facilitate clinical recognition of recurrences. Although hypopigmentation occurred to some degree in several cases (particularly in large nodular tumors), the thickness and texture of the treated areas are approximated that of the non-treated surrounding skin [19].

The achieved results have a clear impact because convert the use of HeberPAG in a new potent antitumoral treatment to offer to patients with periocular NMSC. The potential goals for the use of HeberPAG are the protection of eye and surrounded structures and preservation of vision, to avoid reconstructive surgery and a satisfactory cosmetic effect. We recommend the use of HeberPAG to treat BCC of any subtype (all BCCs), size and localization.

## Conclusions

HeberPAG was safe and showed effect for the treatment of periocular NMSC and is a useful alternative to surgery in patients with NMSC when other therapies have failed or are not possible. The encouraging result justifies further confirmatory trials.

## Competing interests

Authors YGV, CVS, MVC, PLS and IBR are employees of the Center for Genetic Engineering and Biotechnology, Havana network, where the synergistic formulation of IFNs alpha and gamma is produced. The rest of the authors have no competing interests at all.

## Authors' contributions

LAA, SCC, DAM, MNM, SMO, ETA, were the medical doctors that treated the patients. MARG supervised the treatment of patients. EAH, DVP, EVT, conducted the diagnosis of tumors. YGV, YDR, reordered the data of treated patients and took part in the results discussions and manuscript writing. CVS participated in data statistic analysis. MVC participated in the reviewing of literature to write the introduction and for discussion. PLS supervised the data collection and participated in results discussions. IBR supervised the data collection and took part in results discussions and wrote the manuscript. All authors read and approved the final manuscript.

## Acknowledgements

The authors wish to thank nurses and technicians from the Hospital and policlinics participating from the study, and Cimara Bermudez, Hugo Nodarse, Ketty Cruz, and Grettel Melo from CIGB, for their assistance in pharmaceutical product conservation and distribution. The authors received free HeberPAG from Heber Biotec, Havana, Cuba. The Ministry of Public Health of Cuba took care of hospital facilities and medical attention of the patients, including diagnostic procedures laboratory test and the rest of the medicaments.

## References

1. Gloster HM Jr, Brodland DG (1996) The epidemiology of skin cancer. *Dermatol Surg* 22: 217-226.
2. Fink JA, Akelman E (1995) Nonmelanotic malignant skin tumors of the hand. *Hand Clin* 11: 255-264.
3. Cook BE Jr, Bartley GB (2001) Treatment options and future prospects for the management of eyelid malignancies: an evidence-based update. *Ophthalmology* 108: 2088-2098.
4. Riedel KG, Beyer-Machule CK (2000) Basal cell carcinoma. In: Albert DM, Jakobiec FA (eds.) *Principles and Practice of Ophthalmology*. Saunders, Philadelphia, Pa, USA, pp. 3361-3365.
5. Prokosch V, Thanos S, Spaniol K, Stupp T (2011) Long-term outcome after treatment with 5% topical imiquimod cream in patients with basal cell carcinoma of the eyelids. *Graefes Arch Clin Exp Ophthalmol* 249: 121-125.
6. Donaldson MJ, Sullivan TJ, Whitehead KJ, Williamson RM (2002) Squamous cell carcinoma of the eyelids. *Br J Ophthalmol* 86: 1161-1165.
7. Patterson JW (1992) Basal cell carcinoma. In: Demis DJ, Thiers BH, Burgdorf WHC (eds.) *Clinical Dermatology*. JB Lippincott, Philadelphia, pp. 1-26.
8. Erbagci Z, Erbagci I, Erkilic S (2003) High incidence of demodicidosis in eyelid basal cell carcinomas. *Int J Dermatol* 42: 567-571.
9. Madan V, Lear JT, Szeimies RM (2010) Non-melanoma skin cancer. *Lancet* 375: 673-685.
10. Bath-Hextall FJ, Perkins W, Bong J, Williams HC (2007) Interventions for basal cell carcinoma of the skin. *Cochrane Database of Systematic Reviews*.
11. Walling HW, Fosko SW, Geraminejad PA, Whitaker DC, Arpey CJ (2004) Aggressive basal cell carcinoma: presentation, pathogenesis, and management. *Cancer Metastasis Rev* 23: 389-402.
12. Goepfert H, Dichtel WJ, Medina JE, Lindberg RD, Luna MD (1984) Perineural invasion in squamous cell skin carcinoma of the head and neck. *Am J Surg* 148: 542-547.
13. McNab AA, Francis IC, Bengler R, Crompton JL (1997) Perineural spread of cutaneous squamous cell carcinoma via the orbit. *Clinical features and outcome in 21 cases*. *Ophthalmology* 104: 1457-1462.
14. Doxanas MT, Green WR, Iliff CE (1981) Factors in the successful surgical management of basal cell carcinoma of the eyelids. *Am J Ophthalmol* 91: 726-736.
15. Glatt HJ, Olson JJ, Putterman AM (1992) Conventional frozen sections in periocular basal-cell carcinoma: a review of 236 cases. *Ophthalmic Surg* 23: 6-8.
16. Hsuan JD, Harrad RA, Potts MJ, Collins C (2004) Small margin excision of periocular basal cell carcinoma: 5 year results. *Br J Ophthalmol* 88: 358-360.
17. Bauman JE, Eaton KD, Martins RG (2007) Treatment of recurrent squamous cell carcinoma of the skin with cetuximab. *Arch Dermatol* 143: 889-892.
18. Smith V, Walton S (2011) Treatment of facial Basal cell carcinoma: a review. *J Skin Cancer* 2011: 380371.
19. Amini S, Viera MH, Valins W, Berman B (2010) Nonsurgical innovations in the treatment of nonmelanoma skin cancer. *J Clin Aesthet Dermatol* 3: 20-34.
20. Tucker SB, Polasek JW, Perri AJ, Goldsmith EA (2006) Long-term follow-up of basal cell carcinomas treated with perilesional interferon alfa 2b as monotherapy. *J Am Acad Dermatol* 54: 1033-1038.
21. Edwards L, Berman B, Rapini RP, Whiting DA, Tyring S, et al. (1992) Treatment of cutaneous squamous cell carcinomas by intralesional interferon alfa-2b therapy. *Arch Dermatol* 128: 1486-1489.
22. Kim KH, Yavel RM, Gross VL, Brody N (2004) Intralesional interferon alpha-2b in the treatment of basal cell carcinoma and squamous cell carcinoma: revisited. *Dermatol Surg* 30: 116-120.
23. Fenton S, Kennedy S, Moriarty P (2002) The role of interferon alpha 2b as an adjunctive treatment in the management of aggressive basal cell carcinoma of the eyelids. *Acta Ophthalmol Scand* 80: 674-675.
24. Levy D E, Lew D J, Decker T, Kessler D S, and Darnell J E, Jr, (1990) Synergistic interaction between interferon-alpha and interferon-gamma through induced synthesis of one subunit of the transcription factor ISGF3. *EMBO J* 9: 1105-1111.
25. Anasagasti-Angulo L, Garcia-Vega Y, Barcelona-Perez S, Anasagasti-Angulo L, Garcia-Vega Y, et al. (2009) Treatment of advanced, recurrent, resistant to previous treatments basal and squamous cell skin carcinomas

- with a synergistic formulation of interferons. Open, prospective study. *BMC Cancer* 9: 262-274.
26. Calvert AH, Newell DR, Gumbrell LA, O'Reilly S, Burnell M, et al. (1989) Carboplatin dosage: prospective evaluation of a simple formula based on renal function. *J Clin Oncol* 7: 1748-1756.
27. García Martín E, Fernández Tirado FJ (2010) [Periocular basal cell carcinoma treatment tendencies]. *Arch Soc Esp Oftalmol* 85: 261-262.
28. Hayano SM, Whipple KM, Korn BS, Kikkawa DO (2012) Principles of Periocular Reconstruction following Excision of Cutaneous Malignancy. *J Skin Cancer* 2012: 438502.
29. <http://www.cigb.edu.cu/invbiomed/anoario04/index.htm>
30. [http://www.accessdata.fda.gov/drugsatfda\\_docs/label/2012/203388lbl](http://www.accessdata.fda.gov/drugsatfda_docs/label/2012/203388lbl)
31. Von Hoff DD, LoRusso PM, Rudin CM, Reddy JC, Yauch RL, et al. (2009) Inhibition of the hedgehog pathway in advanced basal-cell carcinoma. *N Engl J Med* 361: 1164-1172.
32. Stenquist B, Wennberg AM, Gisslén H, Larkö O (1992) Treatment of aggressive basal cell carcinoma with intralesional interferon: evaluation of efficacy by Mohs surgery. *J Am Acad Dermatol* 27: 65-69.
33. Marks R, Motley RJ (1995) Skin cancer. Recognition and treatment. *Drugs* 50: 48-61.
34. Sapijaszko MJ1 (2005) Imiquimod 5% cream (Aldara) in the treatment of basal cell carcinoma. *Skin Therapy Lett* 10: 2-5.
35. Neudorfer M, Merimsky O, Lazar M, Geyer O (1993) Cisplatin and doxorubicin for invasive basal cell carcinoma of the eyelids. *Ann Ophthalmol* 25: 11-13.
36. Rowe DE, Carroll RJ, Day CL Jr (1989) Long-term recurrence rates in previously untreated (primary) basal cell carcinoma: implications for patient follow-up. *J Dermatol Surg Oncol* 15: 315-328.
37. Smeets NW, Kuijpers DI, Nelemans P, Ostertag JU, Verhaegh ME, et al. (2004) Mohs' micrographic surgery for treatment of basal cell carcinoma of the face--results of a retrospective study and review of the literature. *Br J Dermatol* 151: 141-147.