

## Abdominal Ectopic Pregnancy Case

Abinet Sisay\*

Obstetrician and Gynecologist, Debre Markos Hospital P.O. Box 463, Debre Markos, Ethiopia

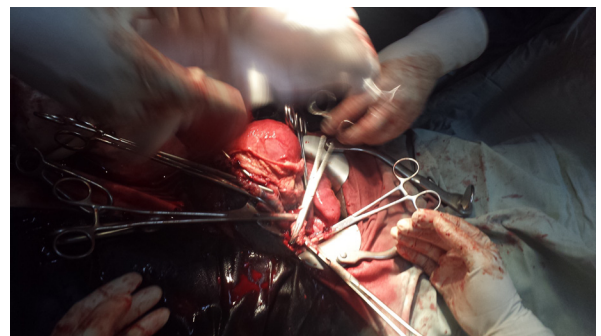
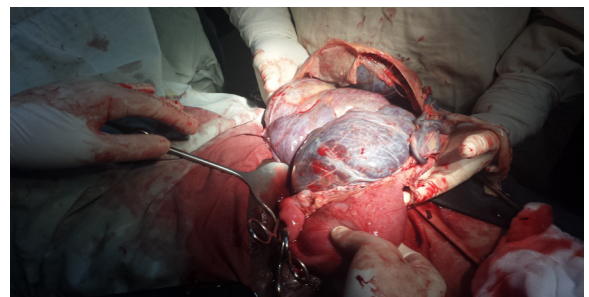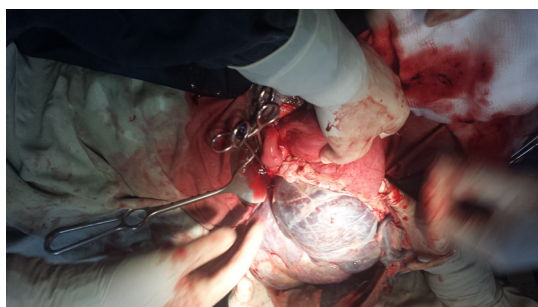
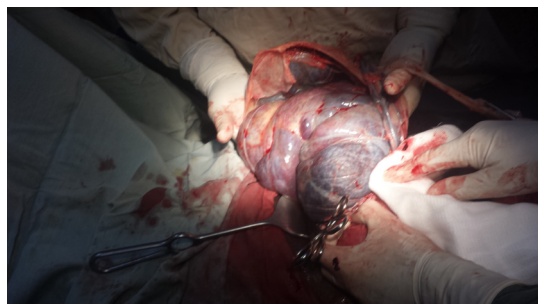
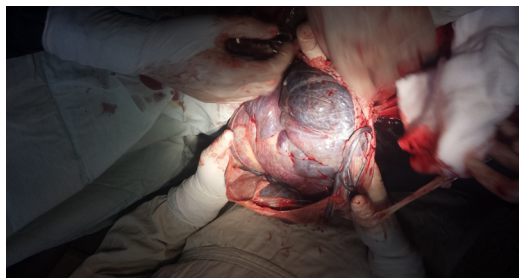The mother was a 30 years old primigravid from the countryside and she never had ANC. She doesn't remember LNMP but claimed to be amenorrhea for 09 months and she presented to the hospital with lower abdominal pain for more than one week duration. She doesn't have any vaginal bleeding recently but retrospectively she told us that she had minimal vaginal bleeding for two days after amenorrhea of 02 months but she didn't go to any health institution and the bleeding stopped by itself.

By the time she presented to the hospital her vital signs were all within the normal range. On abdominal examination the fetus was in transverse lie and there was an easily palpable fetal part. Fetal heart beat was positive and there is no area of tenderness.

Up on ultrasound examination there was singleton intrauterine pregnancy and it's transverse lie and head located on the right flank area. Amniotic fluid volume was adequate. So the patient was taken

to the Operation Theater with a preoperative diagnosis of Term with Transverse Lie+R/O Abdominal Ectopic Pregnancy.

And laparotomy was done as you saw it on the video taken by my cell phone to effect the delivery of is 3 kilo gram alive female neonate with APGAR scores of 7 and 9 at the first and fifth minutes respectively. Mother and the baby left the hospital on the fourth Postoperative without any complication.



\*Corresponding author: Abinet Sisay, Obstetrician and Gynecologist, Debre Markos Hospital P.O. Box 463, Debre Markos, Ethiopia, Tel: +251-911-239622; E-mail: [drabinet@yahoo.com](mailto:drabinet@yahoo.com)

Received October 22, 2015; Accepted October 29, 2015; Published November 04, 2015

Citation: Sisay A (2015) Abdominal Ectopic Pregnancy Case. *Reprod Syst Sex Disord* 4: 1101. doi:[10.4172/2161-038X.10001101](https://doi.org/10.4172/2161-038X.10001101)

Copyright: © 2015 Sisay A. This is an open-access article distributed under the terms of the Creative Commons Attribution License, which permits unrestricted use, distribution, and reproduction in any medium, provided the original author and source are credited.

