

## Oral Ribavirin Treatment Failure for Severe Parainfluenza Type 1 Infection in a Patient with End Stage Interstitial Lung Disease Successfully Treated with DAS181

Bogdanovich T<sup>1</sup>, Kwak EJ<sup>1</sup>, Silveira FP<sup>1</sup>, Pakstis DL<sup>1</sup>, Lanza P<sup>2\*</sup>, and Moss RB<sup>2</sup>

<sup>1</sup>Division of Infectious Diseases, University of Pittsburgh, Pittsburgh, PA, USA

<sup>2</sup>Ansun Biopharma, Inc., San Diego, CA, USA

\*Correspondence author: Lanza P, Ansun Biopharma, Inc., 3030 Callan Road, San Diego CA 92121, USA, Tel: 858-452-2631; Fax: 858-452-0133; E-mail: [planza@ansunbiopharma.com](mailto:planza@ansunbiopharma.com)

Received date: January 27, 2016; Accepted date: February 18, 2016; Published date: February 28, 2016

Copyright: © 2016 Lanza P, et al. This is an open-access article distributed under the terms of the Creative Commons Attribution License, which permits unrestricted use, distribution, and reproduction in any medium, provided the original author and source are credited.

### Abstract

Parainfluenza virus (PIV) infections can cause serious respiratory infections and death in immunocompromised patients. No antiviral drugs have proven efficacy against PIV. DAS181, a sialidase fusion protein has been shown to inhibit infection with PIV strains both *in vitro* and in animal model. The clinical course of immunocompromised patients with PIV-1 infection is described. After being diagnosed with PIV infection, patient was treated for 18 days with oral Ribavirin (RBV) but failed to respond clinically and no virus clearance was obtained. However, patient tested negative for PIV after a 10-days DAS181 treatment course. This case exemplifies failure of oral RBV treatment of severe Parainfluenza virus infection and subsequent viral clearance associated with administration of inhaled DAS181. Large scale randomized trials are warranted to determine the therapeutic efficacy of DAS181 against PIV related lung disease.

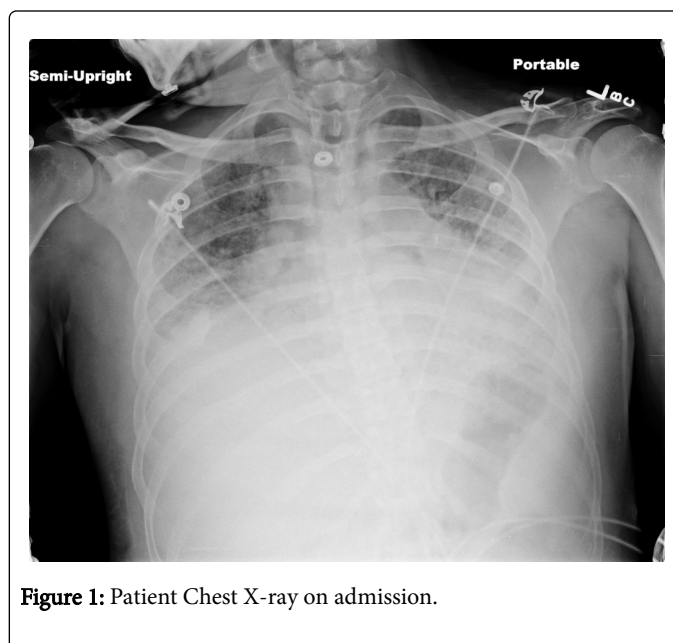
### Abbreviations

ALT: Alanine Transaminase; AST: Aspartate transaminase; FDA: Food and Drug Administration; HCT: Hematopoietic Cell Transplant; IND: Investigational New Drug; NP: Nasopharyngeal; PIV: Parainfluenza Virus; RBV: Ribavirin; RVP: Respiratory Viral Panel

**Keywords:** DAS181; Parainfluenza virus; Hematopoietic cell transplant; Sialidase; Immunocompromised; Resistance

### Case Report

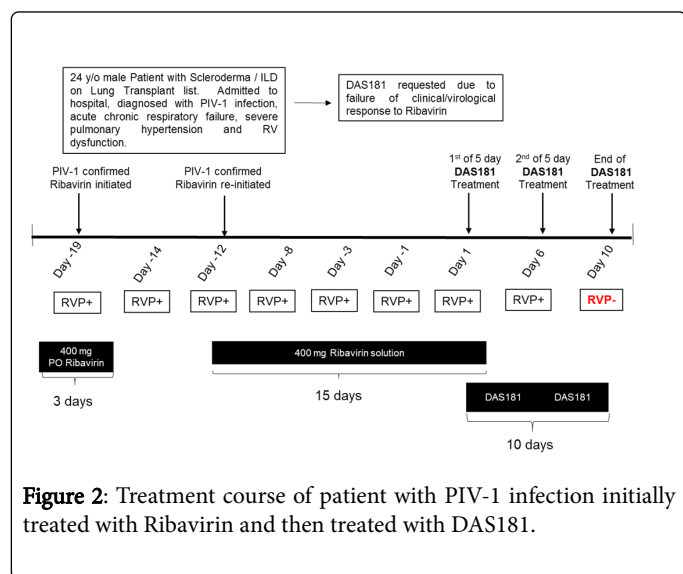
The patient was a 24 year old man listed for double lung transplantation for end stage interstitial lung disease due to systemic scleroderma. He initially presented to an outside medical center with hypoxemic respiratory failure; he was maintained on 100% oxygen high flow nasal cannula alternating with a non-rebreather mask and Bilevel Positive Airway Pressure as needed. He was found to have Parainfluenza type 1 (PIV-1) infection based on nasopharyngeal (NP) swab testing. He was started on oral Ribavirin (400 mg PO TID for 3 days) and received IVIG for 3 days without clinical improvement. He was transferred to our center in consideration for possible lung transplantation and required intubation and tandem Heart placement for new right heart failure on the second day after his transfer. Chest X-ray on admission showed pneumonia (Figure 1). His NP swab on admission was still positive for PIV-1 (Figure 2) and the patient was made inactive on the lung transplant list. A bronchoalveolar lavage bacterial culture obtained on admission was negative but he was kept on empiric antibacterial therapy with piperacillin/tazobactam. He was continued on oral Ribavirin (400 mg PO TID) for additional 15 days but remained persistently positive for PIV-1 on NP swabs (Figure 2).



**Figure 1:** Patient Chest X-ray on admission.

Due to lack of clinical or virological response, Ribavirin was discontinued after a total of 18 days and the patient was started on the investigational antiviral agent DAS181 [1] under an emergency IND approved by the U.S. FDA. He received DAS181 daily via nebulizer for a complete 10 day treatment course. On day 1 and day 2 he received 1.9 and 3.2 mg of DAS181, respectively. Starting on day 3 until completion of treatment, patient received 4.5 mg of DAS181. DAS181 was well tolerated and his oxygen requirement decreased from 12 L/min to 8L/min while on therapy. On the 8<sup>th</sup> day of DAS181

treatment he developed mild elevation of liver enzymes, which peaked at ALT 229 IU/L, AST 304 IU/L and alkaline phosphatase 224 IU/L. Of note the patient had elevated liver enzymes at the beginning of his admission, prior to therapy with DAS181. The elevation of liver enzymes prior to treatment had been attributed to right ventricular dysfunction and liver congestion and it had normalized prior to administration of DAS181. An NP swab on the 10<sup>th</sup> day of DAS181 treatment was negative for PIV by Respiratory Viral Panel (RVP) PCR (Figure 2). During the treatment course the patient's immune suppression regimens and immune status remained stable with his lymphocyte count on admission was  $1.3 \times 10^9/L$  and  $2.0 \times 10^9/L$  on the day of death.



Unfortunately, the patient developed new left-sided heart failure compounding right ventricular failure as described above and was determined to be not a suitable candidate for heart-lung transplantation despite clearance of his PIV-1 infection. It was felt that cardiac disease could be due to underlying scleroderma. The patient was placed on comfort care and passed away on day 30 of his transfer and 4 days after completion of therapy with DAS181. An autopsy limited to the lungs and heart was performed and showed diffuse pneumonia in background of hemorrhage with thrombotically occluded vessels and patchy necrosis overlying extensive fibrotic parenchymal replacement and findings of scleroderma-related cardiac disease. Post-mortem lung cultures showed rare *Staphylococcus aureus* and a respiratory virus panel on the autopsy lung tissue was negative for PIV-1 by RVP.

Treatment or prevention options for patients with PIV infections are limited as there are no FDA approved antivirals or vaccines. Ribavirin has shown both *in vitro* and *in vivo* activity against PIV and is often used for the treatment of PIV [2-4]; however, retrospective studies in the hematopoietic cell transplant (HCT) patients have not shown it to be efficacious in terms of viral shedding, symptom duration, hospital stay, progression or mortality [5-7]. There are very few drugs under development for the treatment of PIV infection [8]. DAS181 is a sialidase catalytic domain/amphiregulin glycosaminoglycan binding sequence fusion protein that enzymatically cleaves the sialic acid residues from the respiratory epithelial cell surface that are essential for viral entry and infection [9]. It has shown efficacy against PIV *in vitro*, as well as in a cotton rat infection model [10,11]. DAS181 had been used in 3 immunocompromised patients with respiratory infections,

including 2 HCT recipients with PIV infection [12,13]. Nebulized DAS181 was successful in clearing the infection from 2 HCT recipients with severe PIV low respiratory tract infections requiring mechanical ventilation; however, 1 of the patients developed recurrent PIV infection at the end of treatment and died [14].

This case exemplifies failure of oral RBV treatment of severe Parainfluenza virus infection and subsequent viral clearance associated with administration of inhaled DAS181 despite continued immunosuppression. A randomized placebo controlled trial examining DAS181 for the treatment of PIV in immunocompromised patients is currently underway.

## Acknowledgement

Ansun Biopharma, Inc. supplied the DAS181 for this case. R.B. Moss and P. Lanza are employees of Ansun Biopharma, Inc., the manufacturer of DAS181. The other authors have no other conflicts of interest to report.

## References

- Moss RB, Steigbigel RT, Sanders RL, Fang F (2011) Perspective: emerging challenges in the treatment of influenza and parainfluenza in transplant patients. *Adv Virol* 2011: 910930.
- Chakrabarti S, Collingham KE, Holder K, Fegan CD, Osman H, et al. (2001) Milligan, "Pre-emptive oral ribavirin therapy of paramyxovirus infections after haematopoietic stem cell transplantation: a pilot study," *Bone Marrow Transplantation* 28: 759-763.
- Chakrabarti S, Collingham KE, Holder K, Oyaide S, Pillay D, et al. (2000) Parainfluenza virus type 3 infections in hematopoietic stem cell transplant recipients: response to ribavirin therapy. *Clin Infect Dis* 31: 1516-1518.
- Stankova J, Carret AS, Moore D, McCusker C, Mitchell D (2007) Long-term therapy with aerosolized ribavirin for parainfluenza 3 virus respiratory tract infection in an infant with severe combined immunodeficiency. *Pediatr Transplant* 11: 209-213.
- Boeckh M (2008) The challenge of respiratory virus infections in hematopoietic cell transplant recipients. *Br J Haematol* 143: 455-467.
- Chemaly RF, Hanmod SS, Rathod DB, Ghantaji SS, Jiang Y, et al. (2012) The characteristics and outcomes of parainfluenza virus infections in 200 patients with leukemia or recipients of hematopoietic stem cell transplantation. *Blood* 119: 2738-2745.
- Nichols WG, Corey L, Gooley T, Davis C, Boeckh M (2001) Parainfluenzavirus infections after hematopoietic stem cell transplantation: risk factors, response to antiviral therapy, and effect on transplant outcome. *Blood* 98: 573-578.
- Chemaly RF, Shah DP, Boeckh MJ (2014) Management of respiratory viral infections in hematopoietic cell transplant recipients and patients with hematologic malignancies. *Clin Infect Dis* 59 Suppl 5: 344-351.
- Malakhov MP, Aschenbrenner LM, Smeed DF, Wandersee MK, Sidwell RW, et al. (2006) Sialidase fusion protein as a novel broad-spectrum inhibitor of influenza virus infection. *Antimicrob Agents Chemother* 50: 1470-1479.
- Moscona A, Porotto M, Palmer S (2010) A recombinant sialidase fusion protein effectively inhibits human parainfluenza viral infection *in vitro* and *in vivo*. *J Infect Dis* 202: 234-241.
- Jones BG, Hayden RT, Hurwitz JL (2013) Inhibition of primary clinical isolates of human parainfluenza virus by DAS181 in cell culture and in a cotton rat model. *Antiviral Res* 100: 562-566.
- Guzmán-Suarez BB, Buckley MW, Gilmore ET, Vocca E, Moss R, et al. (2012) Clinical potential of DAS181 for treatment of parainfluenza-3 infections in transplant recipients. *Transpl Infect Dis* 14: 427-433.
- Chen YB, Driscoll JP, McAfee SL, Spitzer TR, Rosenberg ES, et al. (2011) Treatment of parainfluenza 3 infection with DAS181 in a patient after allogeneic stem cell transplantation. *Clin Infect Dis* 53: 77-80.

**Citation:** Bogdanovich T, Kwak EJ, Silveira FP, Pakstis DL, Lanza P, et al. (2016) Oral Ribavirin Treatment Failure for Severe Parainfluenza Type 1 Infection in a Patient with End Stage Interstitial Lung Disease Successfully Treated with DAS181. *J Antivir Antiretrovir* 8: 020-022. doi: [10.4172/jaa.1000130](https://doi.org/10.4172/jaa.1000130)

---

14. Chalkias S, Mackenzie MR, Gay C (2014) DAS181 treatment of hematopoietic stem cell transplant patients with parainfluenza virus lung disease requiring mechanical ventilation. *Transpl Infect Dis* 16: 141-144.