

Hypertensive Phase of Ahmed Glaucoma Valve in Juvenile Onset Glaucoma of Sturge-Weber Syndrome

Shalini Mohan*, Jaya Gupta, Ramesh Chandra Gupta and Surendra Kumar Sachan

GSVM Medical College, Kanpur, UP, India

Abstract

This is a case report of a 24 years old male patient of juvenile onset glaucoma of Sturge-Weber Syndrome (SWS) with choroidal hemangioma. Glaucoma was uncontrolled on maximum antiglaucoma medications. Ahmed Glaucoma valve was implanted which later on complicated with hypertensive phase although it resolved with needling of the bleb. The case highlights that AGV implantation is a viable option for management of juvenile onset glaucoma of SWS but can be associated with reversible complications.

Keywords: Sturge-Weber syndrome; Ahmed glaucoma valve

Introduction

Sturge-Weber syndrome (SWS) is a rare, congenital neurocutaneous syndrome characterized by unilateral portwine stain in association with ipsilateral leptomeningeal angiomatosis. The most common ophthalmic association with SWS is presence of glaucoma followed by choroidal hemangioma [1]. Sixty percent of patients develop glaucoma in infancy due to anterior chamber angle anomalies and forty percent in childhood or early adulthood resulting from raised episcleral venous pressure [2].

Management of glaucoma is not easy because response to medical management is not good and best surgical procedure is very challenging. Various surgical procedures like trabeculotomy, goniotomy, trabeculectomy and augmentation with antimetabolites have been tried but their success rates is lesser when done for SWS than when used for primary congenital glaucoma [1,2]. A primary procedure of combined trabeculotomy- trabeculectomy was hence used with better results but the success rate without antimetabolites was poor [2]. Use of these agents to modulate wound healing can cause postoperative hypotony and other risks [2,3]. Moreover, the presence of a choroidal hemangioma, with a thin-walled endothelium, might increase the risk for expulsive hemorrhage when sudden intraoperative hypotony develops as seen during filtering surgery [2].

A promising newer approach is implantation of Glaucoma Drainage device (GDD) [2,3].

We present a case report of a 24 year old young male with SWS and choroidal hemangioma having uncontrolled glaucoma in which primary GDD implantation was complicated with Hypertensive phase which later on resolved.

Case Report

A 24 year old male patient was referred to Glaucoma clinic of a tertiary care hospital with a portwine stain at the left side of the face (Figure 1) involving the ophthalmic division of the Trigeminal nerve. The patient was already a diagnosed case of glaucoma left eye (LE) three years back and was using three topical antiglaucoma medications which were timolol 0.5%, brimonidine 0.15% and dorzolamide 2%. Detailed history did not reveal any episodes of seizures nor mental retardation.

He was examined in detailed and was found to have his best-corrected visual acuity (BCVA) of 6/6 (20/20) in both the eyes. The applanation tonometry revealed an IOP of 17 mmHg in right eye

(RE) and 26 mm Hg in his left eye (LE). Slit lamp examination of RE revealed no abnormality but LE revealed scleral pigmentation, tortuous conjunctival and episcleral vessels with normal anterior chamber depth on Van Herrick's grading. Gonioscopy of LE showed open angles with prominent Schwalbe's line along with iris processes. Dilated fundus examination revealed that the optic nerve head had cup-disc ratios of 0.3 in RE and 0.7 in LE. Central corneal thickness (CCT) was 545 microns and 540 microns in RE and LE, respectively. Fundus examination along with fluorescein angiography revealed choroidal hemangioma at posterior pole. Humphrey's visual fields of RE was normal but LE showed superior arcuate scotoma. CT-scan of the head showed "tram track" appearance. The diagnosis of SWS with glaucoma and choroidal hemangioma was made.

The IOP in LE was uncontrolled despite of maximum antiglaucoma medications. So, surgical intervention to control IOP was planned. The pros and cons of trabeculectomy were weighted against GDD implantation. Due to poor results of trabeculectomy and its associated complications in a patient with SWS a decision was taken to implant a

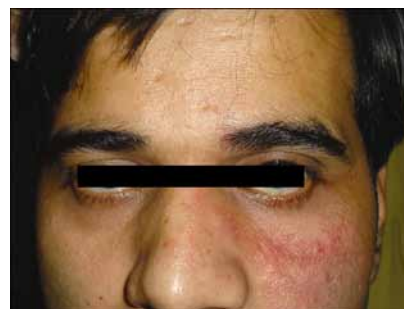

Figure 1: Portwine stain at left side of face.

***Corresponding author:** Shalini Mohan, MS, DNB, Assistant Professor, Glaucoma Services, Department of Ophthalmology, GSVM Medical College, Kanpur, UP, India, Tel: 919506740966; E-mail: drshalinimohan@gmail.com

Received June 06, 2012; Accepted June 18, 2012; Published June 23, 2012

Citation: Mohan S, Gupta J, Gupta RC, Sachan SK (2012) Hypertensive Phase of Ahmed Glaucoma Valve in Juvenile Onset Glaucoma of Sturge-Weber Syndrome. J Clin Exp Ophthalmol 3:226. doi:10.4172/2155-9570.1000226

Copyright: © 2012 Mohan S, et al. This is an open-access article distributed under the terms of the Creative Commons Attribution License, which permits unrestricted use, distribution, and reproduction in any medium, provided the original author and source are credited.

valved GDD i.e. Ahmed glaucoma valve (AGV) (New World Medical, Inc, Rancho Cucamonga, California, USA). AGV was implanted in superio-temporal quadrant in the LE (Figure 2). The tube was covered with partial thickness scleral flap. Intraoperative sudden decompression was avoided and an uneventful surgery as specified by manufacturers was done under local anesthesia. Anterior chamber was formed with Sodium hyaluronate 1.4% at the end of surgery to avoid postoperative hypotony. On first post operative day there was hyphema of 1 mm and coagulated blood could be seen along the tube. Patients was given topical steroid eyedrops (1% Prednisolone acetate, 8 times), topical antibiotic (Ofloxacin 0.3%, 4 times a day) and homatropine (2%, twice daily). Patient was asked to sleep with elevated head end of the bed. The hemorrhage resolved on 5th post operative day. The IOP was 14 mm Hg on non contact tonometer at 1st post operative day. After 2 weeks appplanation tonometry was done that revealed an IOP of 12 mm Hg. The steroid drop was tapered and other two drops were stopped 15 days post operatively. BCVA returned to 20/20 after resolution of hyphema.

Patient was followed up regularly, when at 6 weeks his tension increased to 30 mm Hg and slit lamp examination revealed a large, cystic, inflamed, angry looking bleb. A diagnosis of hypertensive phase of AGV was made. Digital massage was done and topical steroid eye drop was again stepped up along with addition of oral acetazolamide, topical timolol 0.5% and brimonidine 0.2% twice daily which controlled his IOP. Oral acetazolamide was withdrawn after 3 days which lead to increase in IOP to 24 mm Hg. The drugs were continued with digital massage but the bleb continued to be encysted and IOP uncontrolled. So, needling of the bleb was planned at 10 weeks of surgery. A 27 gauge needle was entered into the bleb and rotated well to break all the adhesions which lead to flattening of bleb on table. This lead to reduction of IOP to 14 mm Hg and withdrawal of both topical antiglaucoma medications. The total follow up after surgery is 2 years and 6 months and IOP is well controlled. Neither choroidal effusion nor increase in choroidal hemangioma was noted in 2 years and 6 months follow up period.

Discussion

The use of AGV has been reported in SWS to prevent on table hypotony which is seen in trabeculectomy and has been implicated in occurrence of choroidal haemorrhage [1,2].

The major surgical concern in our case was the age of the patient and the presence of choroidal hemangioma. For a 24-year-old patient, a goniotomy or trabeculotomy would not be suggested because it would be less successful. The patient with a fragile choroidal hemangioma carries a higher risk of massive hemorrhage if undergoing filtering surgery and a prophylactic sclerostomy is usually required [2].

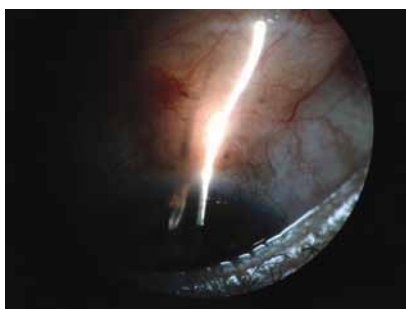


Figure 2: Ahmed Glaucoma Implant with superotemporal bleb in the patient.

The AGV has a unidirectional valve which prevents intraoperative and postoperative hypotony. It offers potential advantages over valveless implants, in which internal occlusion or external ligation is usually needed to avoid postoperative hypotony. Pediatric glaucomas do have long list of complications with AGV implantation [3].

But our patient was having juvenile onset glaucoma of Sturge-Weber syndrome. So AGV implantation was a viable option preventing intraoperative hypotony and its subsequent complication. Although it might be complicated with hypertensive phase especially in young adults as seen in our case. This might resolve with medical management only or bleb needling may be required for such patients. Patient should be counseled for this well known entity and surgeon should always be ready to deal with such a situation.

To our knowledge, this is the first case report of management of hypertensive phase of AGV by needling in juvenile onset glaucoma of SWS.

In summary, an AGV offers safety and efficacy in controlling late onset glaucoma in SWS combined with choroidal hemangioma. The surgical procedure is not associated with any irreversible complications, a one-stage implant is satisfactory and a prophylactic sclerostomy is not required.

References

1. Di Rocco C, Tamburrini G (2006) Sturge-Weber syndrome. *Childs Nerv Syst* 22: 909-921.
2. Wu SC, Lin KK (2006) Ahmed glaucoma valve implant for childhood glaucoma in Sturge-Weber syndrome with choroidal hemangioma. *Chang Gung Med J* 29: 528-531.
3. Hamush NG, Coleman AL, Wilson MR (1999) Ahmed glaucoma valve implant for management of glaucoma in Sturge-Weber syndrome. *Am J Ophthalmol* 128: 758-760.