

## Aspergillosis in Hydatid Cyst- A Rare Coexistence

Smita Mahapatra\*, Rupa Das, Chandrasekhar Mohapatra, Jayasree Rath and Susmita Behera

Department of Pathology, S.C.B. Medical College, Cuttack-753007, Orissa, India

### Abstract

Although the colonization of aspergillosis in hydatid cyst is common in immunocompromised patient, it is extremely rare in immunocompetent patient. A 42 years old patient who was operated for hydatid cyst one year back presented with fever and hemoptysis for one month. CT of thorax revealed a heterogeneous mass in left lobe of the lung with surrounding ground glass opacity. HIV ELISA was negative. Gross received was mucinous cystic structure containing brownish necrotic material. Microscopic finding of laminated cystic wall infiltrated with fungal hyphae was consistent with co-existence of hydatid cyst with aspergillosis. This was confirmed with PAS stain followed by culture. The patient very well responded to anti-fungal therapy following wedge resection.

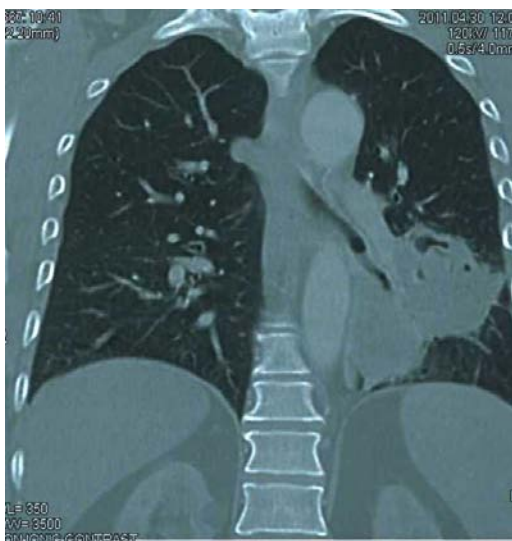**Keywords:** Hydatid cyst; Aspergillosis; Immunocompetent

### Introduction

Fungal infections can colonize in lung cavities mostly in immunocompromised patients. Aspergillosis can develop in cavities formed due to tuberculosis, bronchiectasis, sarcoidosis, lung abscess and cavitary neoplasms [1]. Pulmonary aspergillosis has been reported rarely in pulmonary cavities after the removal of hydatid cyst [2-4]. We report a case in an immunocompetent patient in whom co-existence of echinococcosis and aspergillosis was detected which is extremely rare. For the better management of the patient while dealing with hydatid cyst, concurrence of aspergillosis should be kept in mind.

### Case Report

A 42 years old male was presented with irregular fever and hemoptysis for a duration of one month. He had a history of hydatid cyst of left lung for which he was operated one year back. CT (computed tomography) of thorax showed a large heterogeneous mass of  $80 \times 73 \times 45 \text{ mm}^3$  with air bronchogram and bronchiologram seen involving posterior-medial basal segment of left lower lobe and posterior segment of left upper lobe with surrounding ground glass opacity, speculation from surface and extension along major fissure with satellite nodule (figure 1). Radiologically the provisional diagnosis of carcinoma of lung (broncho-alveolar carcinoma) was made.

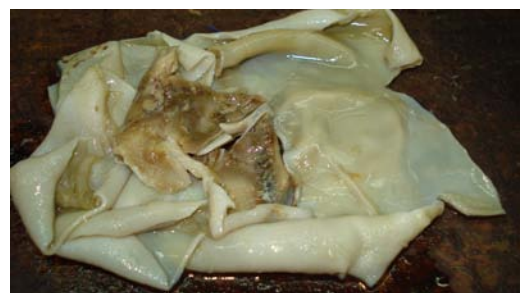

**Figure 1:** Large heterogeneous mass in left lobe with surrounding ground glass opacity (CT of thorax).

Routine laboratory examination did not reveal any abnormality except a mild degree of anemia, with a hemoglobin level of 10.6 g/dl. Total and differential counts were within normal limit. Serum was non-reactive for human immunodeficiency virus. Repeated sputum smears were negative for acid-fast bacilli. The patient underwent surgery, and a wedge resection specimen was sent for histopathological evaluation. Gross received was multiple bits of cystic structures together measuring  $20 \times 10 \times 2 \text{ cm}^3$  containing mucinous material. In cut-section, an area of brownish necrotic material was seen (figure 2). Microscopic examination of the cyst wall revealed the laminated membrane of a hydatid cyst with massive infiltration of fungal hyphae, consistent with aspergillosis (figure 3). Histochemically, periodic acid-Schiff (PAS) stain was applied and the co-existence of hydatid cyst with Aspergillosis was confirmed. Culture of the tissue grew *aspergillus fumigatus*. The patient was treated for hydatid disease with albendazole and itraconazole for aspergillosis. The patient was free of any recurrence of either the disease when followed up for another 10 months.

### Discussion

Hydatid cyst (echinococcosis) is a parasitic disease which is most commonly caused by *Echinococcus granulosus*, but *Echinococcus multilocularis* is the most common type causing pulmonary infection.



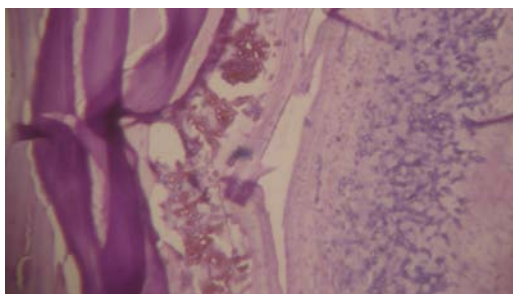
**Figure 2:** C/S of cystic structures containing brownish necrotic material.

\*Corresponding author: Smita Mahapatra, Department of Pathology, S.C.B. Medical College, Cuttack-753007, Orissa, India, Tel: 91-9437094138; E-mail: [doctorsmita@rediffmail.com](mailto:doctorsmita@rediffmail.com)

Received May 22, 2012; Accepted June 13, 2012; Published June 21, 2012

**Citation:** Mahapatra S, Das R, Mohapatra C, Rath J, Behera S (2012) Aspergillosis in Hydatid Cyst- A Rare Coexistence. Virol Mycol 1:106. doi:10.4172/2161-0517.1000106

**Copyright:** © 2012 Mahapatra S, et al. This is an open-access article distributed under the terms of the Creative Commons Attribution License, which permits unrestricted use, distribution, and reproduction in any medium, provided the original author and source are credited.



**Figure 3:** Photomicrograph of laminated hydatid cyst wall with infiltration of fungal hyphae (H&E,x100).

It most commonly involves two blood filtering organs, the lungs and liver, but can affect any organ of the body [5]. Aspergillosis is a saprophytic fungal infection. *Aspergillus fumigatus* is the most common cause of aspergillosis in human beings [6]. Aspergillus may cause allergic pulmonary aspergillosis, aspergilloma, and semi-invasive and invasive aspergillosis [6].

Development of aspergillosis in hydatid cyst cavities is rare. Aspergillosis in an operated hydatid cavity was reported after many years in one case and after six months in another case [3,4]. Although immunocompromised patients are more prone to aspergillosis, the co-existence of aspergillus and hydatid cyst has been reported in both immunocompromised and immunocompetent patients [7,8]. Our patient who was immunocompetent was unique in that in a post-operative cavity again hydatid cyst developed which was secondarily infected with aspergillus. Aspergillosis was invading the wall of ruptured hydatid cyst as seen in histopathology.

Approximately 60% of pulmonary hydatid disease affects the right lung and 50-60% involves the lower lobes [9] but, our case had developed the lesion in the left lung. The clinical presentation of pulmonary hydatid cysts depends on whether the cyst is intact or ruptured. Intact cysts are either incidental finding or present with

cough, dyspnoea or chest pain. A complicated cyst is that which has ruptured into a bronchus, pleural cavity or biliary tree. In ruptured cyst besides these symptoms, the patient may present with expectoration of cystic contents, repetitive hemoptysis, productive sputum, fever, or anaphylactic shock which might be the cause for hemoptysis in our case. Whether the hydatid cyst ruptured spontaneously or because of the invasion of aspergillosis is speculative. Wedge resection was opted for recurrent hemoptysis in our case since the surrounding lung tissue was healthy and this was recommended by others [10].

While dealing with hydatid cyst the co-existence of aspergillosis should always be kept in mind for the better management of the patient.

#### References

1. Addis B (1996) Pulmonary mycotic disease-pulmonary aspergillosis. In: Hasleton PS, editor *Spencer's Pathology of the Lung*, New York, USA: McGraw-Hill Professional 257-265.
2. Soubani AO, Chandrasekar PH (2002) The clinical spectrum of pulmonary aspergillosis. *Chest* 121: 1988-1999.
3. Ulasan NG, Dural K, Yildirim E, Ozisik K, Sakinci U (2003) An intracavitary aspergilloma after echinococcal cystectomy. *J Cardiovasc Surg(Torino)* 44: 289-290.
4. Aydemir B, Aydemir C, Okay T, Celik M, Dogusoy I (2006) An aspergilloma in an echinococcal cyst cavity. *Thorac Cardiovasc Surg* 54: 353-355.
5. King CH (2000) Cestodes (tapeworm) In: Mandell GL, Bennet JE, Dolin R, editors, *Mandell, Douglas and Bennett's principles and practice of infectious diseases*. (5th edn), Philadelphia USA: Churchill Living stone 2956-2964.
6. Sabonya RE (2005) Fungal disease including pneumocystis. *Thurbeck's pathology of the lung (3rd edn)*, New York, USA: Thieme 283-315.
7. Date A, Zachariah N (1995) Saprophytic mycosis with pulmonary echinococcosis. *J Trop Med Hyg* 98: 416-418.
8. Gupta N, Arora J, Nijhawan R, Aggarwal R, Anupama Lal (2006) Aspergillosis with pulmonary echinococcosis. *Cyto journal* 3:7
9. Bhatia G (1997) Echinococcus. *Semin Respir Infect* 12: 171-186.
10. Al-Kattan K, Ashour M, Hajjar W, Salah El Din M, Fouda M et al. (2001) Surgery for pulmonary aspergilloma in post-tuberculous vs. immuno-compromised patients. *Eur J Cardiothorac Surg* 20: 728-733.