

The Anatomical and Clinical Outcome of Conventional Macular Hole Surgery Associated with Serpigenous Choroiditis

Sivakami A Pai*, Afra Lootah and Manal Omran Taryam

Vitreo-Retinal Surgeon, Dubai Government Health Authority, Dubai

Abstract

Purpose: Serpigenous choroiditis is a chronic recurring condition that primarily involves the choroids and RPE, and Macular hole is a rare association. We here in report the management and outcome after conventional macular hole surgery.

Method: Case of a 58 year old Asian lady with serpigenous choroiditis and full thickness macula hole. She underwent complete ocular evaluation, Fundus fluorescein angiography, OCT before macular hole surgery.

Result: There was complete closer of the hole with improvement in vision from 5/60 to 6/36 following surgery.

Conclusion: Macular hole is one of the unusual associations with serpigenous choroiditis and conventional macular hole surgery can lead to successful closure of the macular hole.

Keywords: Serpigenous choroiditis; Macular hole; Vitrectomy; Posterior uveitis; Optical coherence tomography

Introduction

Full thickness macular holes are a rare association with serpigenous choroiditis. There are only few reports of macular hole with ocular inflammatory disorders. Maria et al have reported bilateral macular hole associated with serpigenous chroidits [1]. Sheu et al. have reported full thickness macular hole associated with behcets disease [2]. Posterior segment complications of ocular inflammation can lead to irreversible alteration with severe visual loss. We report the anatomical and visual outcome following conventional macular hole surgery associated with serpigenous choroiditis after control of ocular inflammation with systemic corticosteroids.

Materials and Method

Prospective interventional case report of a 58 year old Asian

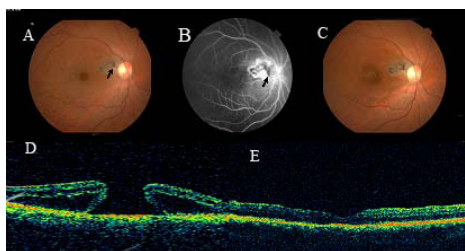


Figure 1: The color fundus picture, Optical coherence tomography (OCT) and Fluorescence angiogram (FA) pictures of the 58 year old Asian lady with serpigenous choroiditis with full thickness macular hole in the right eye (RE). She underwent vitrectomy with ILM peeling and C3 F8 injection after control of inflammation with systemic corticosteroids. **A.** Color fundus picture shows temporal peripapillary, grayish, helicoid lesion with pigmented borders. There is full thickness macular hole and vision of 5/60. **B.** FA frames shows central area of hyperfluorescence surrounded by patchy areas of hypofluorescence (Blocked by pigments), border of the lesion showed fuzzy leak. Macula showed central well circumscribed transmission defect with surrounding pooling of the dye in late frame and optic disc leak. **C.** Color fundus picture after 6 weeks after surgery shows closing of the macular hole with glial tissue proliferation in the area of macular hole. **D.** OCT image shows a full thickness macular hole, cystoid macular edema with surrounding retinal detachment. **E.** OCT image after 12 weeks of surgery shows complete closure of the macular hole with improvement of vision to 6/36.

lady who presented with decrease in vision, metamorphopsia and scotoma in the right eye since 3 months. She underwent complete ocular examination, Optical coherence tomography (OCT), Fundus fluorescein angiography (FA) and hematological tests.

Her vision at presentation was 5/60 in the right eye (RE). Anterior segment examination was unremarkable. Fundus examination showed grayish, helicoid peripapillary lesion with pigmented borders. Macula showed full thickness macular hole, (Figure 1-A). OCT confirmed full thickness macular hole, cystoid macular edema with surrounding retinal detachment, (Figure 1-B). FA showed central area of hyperfluorescence surrounded by patchy areas of hypofluorescence (Blocked by pigments), border of the lesion showed fuzzy leak. Macula showed central well circumscribed transmission defect and with surrounding pooling of the dye in late frame and optic disc leak (Figure 1-C). LE the vision was 6/18, fundus examination showed features of ampigenous choroiditis. She had no hematological abnormality. She was given systemic corticosteroids, which was slowly tapered over a period of 8 weeks. Then she underwent vitrectomy with ILM peeling and C₃F₈ (14%) temponade.

Results

There were signs of closure of the macular hole by 6 weeks of surgery, (Figure 1-D). By 12 weeks of surgery there was complete closure of the macular hole on OCT (Figure 1-E), with improvement of vision to 6/36. She underwent cataract surgery with intraocular lens implantation after 6 months and maintained the same vision even after 6 months follow up.

*Corresponding author: Sivakami A Pai, Vitreo-Retinal Surgeon, Dubai Government Health Authority, Dubai, E-mail: Sudhirshiv@yahoo.com

Received January 31, 2011; Accepted April 05, 2011; Published April 07, 2011

Citation: Pai SA, Lootah A, Taryam MO (2011) The Anatomical and Clinical Outcome of Conventional Macular Hole Surgery Associated with Serpigenous Choroiditis. J Clin Experiment Ophthalmol 2:153. doi:10.4172/2155-9570.1000153

Copyright: © 2011 Pai SA, et al. This is an open-access article distributed under the terms of the Creative Commons Attribution License, which permits unrestricted use, distribution, and reproduction in any medium, provided the original author and source are credited.

Discussion

Macular hole is one of the complications of posterior uveitis [1,2]. The newer diagnostic tools, fundus Autofluorescence, OCT and indocyanine green angiography plays a important role in the management of posterior uveitis. In particular fundus auto fluorescence is a non invasive, sensitive imaging technique for detecting damage of the RPE in acute episodes of Serpigenous chroiditis [3]. Long standing cystoid macular edema, inflammatory cellular membrane proliferations, Vitreo-macular traction forces caused by severe recurrent vitritis in combination with the retinochoroidal atrophy are the probable mechanisms of macular hole formation in chronic recurrent ocular inflammatory conditions [4]. Presence of cystoid macular edema, surrounding retinal detachment and tangential vitreous traction establishes rational for surgical treatment of macular holes [5]. In conventional surgery for idiopathic macular hole, with removal of tapered cortical vitreous, the edges of the hole comes together and healing takes place with proliferation of glial tissue.

In this case, patient had a chronic posterior uveitis with unilateral full thickness macular hole at presentation. Therefore, there was no

documentation of a preceding macular edema or Vitreo- macular traction membranes. Ocular inflammation was controlled by systemic corticosteroids before macular hole surgery and there was successful closure of the macular hole with improvement in vision. There are only few reports of closure of the macular hole associated with posterior uveitis, following conventional macular hole surgery with improvement in vision on Medline search [1,4]. Therefore, we would like to report this case.

References

1. Gregory ME, Bhatt U, Benskin S, Banerjee S (2009) Bilateral Full Thickness Macular Holes in Association With Serpiginous Choroiditis. *Ocul Immunol Inflamm* 17: 328-329.
2. Sheu SJ, Yang CA (2004) Macular hole in Behcet's disease. *Kaohsiung J Med Sci* 20: 558-562.
3. Piccolino FC, Grosso A and Savini E (2009) Fundus autofluorescence in serpiginous choroiditis. *Graefes Arch Clin Exp Ophthalmol* 2: 179-185.
4. Shukla D, Dhawan A (2010) Evolution and Management of a Post-Uveitis Macular Hole. *Ophthalmic Surg Lasers Imaging* 9:1-3.
5. Green WR (2006) The Macular Hole: Histopathologic Studies. *Arch Ophthalmol* 124: 317-321.

Submit your next manuscript and get advantages of OMICS Group submissions

Unique features:

- User friendly/feasible website-translation of your paper to 50 world's leading languages
- Audio Version of published paper
- Digital articles to share and explore

Special features:

- 100 Open Access Journals
- 10,000 editorial team
- 21 days rapid review process
- Quality and quick editorial, review and publication processing
- Indexing at PubMed (partial), Scopus, DOAJ, EBSCO, Index Copernicus and Google Scholar etc
- Sharing Option: Social Networking Enabled
- Authors, Reviewers and Editors rewarded with online Scientific Credits
- Better discount for your subsequent articles

Submit your manuscript at: www.editorialmanager.com/clinicalgroup

