

The Use of Amniotic Membrane in the Management of Strabismus Reoperation Cases

Betul Tugcu^{1*}, Firat Helvacioğlu², Erdal Yuzbasioglu² and Cere Gurez¹¹Operator Doctor, Department of Ophthalmology, Bakirkoy Dr.Sadi Konuk Education and Research Hospital, Istanbul, Turkey²Associate Professor, Department of Ophthalmology, Bakirkoy Dr.Sadi Konuk Education and Research Hospital, Istanbul, Turkey**Abstract****Objective:** To describe the use of amniotic membrane (AM) in reoperations to decrease scar formation and to improve ductions.**Design:** Prospective interventional case series.**Participants:** Four previously operated cases with restrictive strabismus.**Methods:** Objective clinical findings were recorded during both pre and post-operative periods. Excision of adhesions and scar tissue, repositioning of extraocular muscles and placement of AM between muscle, sclera and tenon tissue were performed.**Results:** Orthophoria with no duction deficits was achieved in 2 patients. One patient with fat adherence syndrome had orthophoria with -1 adduction deficit. Only one patient with congenital fibrosis syndrome had 25 PD of esotropia with abduction deficit (-2).**Conclusions:** We believe that AM placement between the extra ocular muscle, sclera and tenon tissue improves the ductions by inhibiting post-operative scar formation.**Keywords:** Amniotic membrane; Reoperation cases; Strabismus surgery**Introduction**

Reoperation may be expected in at least 5-10% of patients who undergo strabismus surgery, despite the most meticulous efforts to perform a careful preoperative evaluation and determine appropriate surgical strategy [1]. Common reoperation scenarios include under correction, overcorrection, slipped or lost muscles, restrictions after a prior ophthalmic surgical procedure and the development of a new surgical problem. Restrictions usually develop after excessive resections, intra conal fat violation or scar tissue formations which result in postoperative adhesions [2].

There are only a few reports in the literature on the use of amniotic membrane transplantation to treat restrictive strabismus. Yamada et al published a case report on the successful treatment of restrictive strabismus occurring after retinal detachment surgery, Sheha et al. [4] described wrapping the extraocular muscles with amniotic membrane in a case of consecutive exotropia, and Kersey and Vivian used amniotic membrane in conjunction with mitomycin C in 2 patients with complex strabismus surgery [3-5]. Strube et al. [6] reported a case series describing the use of amniotic membrane transplant to repair restrictive strabismus occurring after a variety of anterior segment, oculo plastic and retinal surgeries [6].

In our study, we used amniotic membrane (AM) to decrease scar formation in strabismus cases with ocular restrictions which had developed after a prior ophthalmic surgical procedure.

Methods

Patients with symptoms of restrictive strabismus which had resulted from previous strabismus surgery were identified in the general strabismus clinic over a period of 3 years. Patients were questioned about the type of deviations and previous surgeries. Objective clinical findings (visual acuity with Snellen visual acuity, angle of deviations

and degree of duction deficits) were recorded for both pre and post-operative periods. Krimsky test or alternate prism and cover test were used in the measurement of angle of deviation according to visual acuity and cooperation of the patient. To detect the restrictions, intra operative forced duction tests were performed several times in the surgery. Strabismus surgery which includes excision of adhesions and scar tissue, repositioning of extraocular muscles (EOM) (according to degree of deviations) and placement of AM between sclera, EOM and tenon tissue was performed. Fresh AM was obtained from the elective cesarean sections of the seronegative patients. After dissected from chorionic tissue, it was washed by sterile serum physiologic solution which involved gentamicin 50 µg/ml. Washed tissue was kept in the same solution for 30 minutes, before it was prepared for the surgery. Nearly 2 sheets of 8x6mm fresh AM were used for each patient. The first sheet was placed under the EOM and second one was placed over the EOM. The stromal side of AM facing towards the tenon's capsule was placed in order to decrease postoperative scar formation. Also conjunctival recession with covering of the bare sclera by AM (stromal side facing down) was performed in patients with characteristic signs of indentation. The AM was sutured separately to the episcleral bed and conjunctival edge with polyglactin 910 suture. All surgeries were performed under general anesthesia by the same surgeon (BT). Informed consent was obtained from patients or patients' guardian before the operations. The ethical committee of our research and education hospital approved the study.

***Corresponding author:** Betul Tugcu, Bakirkoy Research and Education Hospital, Istanbul, Turkey, Tel: 90 5324460681; E-mail: betultugcu@yahoo.com**Received** February 13, 2011; **Accepted** April 05, 2011; **Published** April 09, 2011**Citation:** Tugcu B, Helvacioğlu F, Yuzbasioglu E, Gurez C (2011) The Use of Amniotic Membrane in the Management of Strabismus Reoperation Cases. J Clin Experiment Ophthalmol 2:156. doi:10.4172/2155-9570.1000156**Copyright:** © 2011 Tugcu B, et al. This is an open-access article distributed under the terms of the Creative Commons Attribution License, which permits unrestricted use, distribution, and reproduction in any medium, provided the original author and source are credited.

Results

The mean follow-up period was 18 months (range 12 to 24 months). The clinical features of the patients were outlined in Table 1. Postoperatively all patients improved (Figure 1, Figure 2, Figure 3 and Figure 4). Orthophoria was achieved in 3 patients. Forced duction testing was positive preoperatively and negative at the end of the surgery in all cases. Only one patient with congenital fibrosis syndrome had 25 PD of esotropia with bilateral abduction deficit (-2). All patients had successful outcome after AM transplantation with complete reepithelization of the conjunctival defect. No scarring resulting in secondary restriction was identified in the area of AM transplantation (Figure 5 and Figure 6).

Case 1

She had 5 mm recession of left medial rectus (MR) in another center about 6 months before with no improvement in degree of esotropia. After excision adhesions and scar tissue, AM was placed and left MR recessed further 3 mm. Additionally conjunctival recession (6 mm) was made. One month later right MR recession (8 mm) and conjunctival recession (6mm) was performed.

Case 2

She had MR recession 6 mm, lateral rectus (LR) resection 8 mm, inferior oblique myectomy in right eye at the age of 13. Right exotropia developed after surgery. After excision of adhesions and scar tissue around LR muscle path, AM was placed and conjunctival recession (7 mm) was performed. Postoperatively she had 30 PD of exotropia with adduction deficit (-1). After 2 months we performed a second operation (right MR advancement (5mm), right MR resection (3 mm) with placement of AM between muscle, sclera and tenon tissue).

Case 3

She had birth trauma, mental retardation and alternating exotropia of 35 PD. We performed right LR recession 8 mm, right MR resection 5 mm. Post operatively she had esotropia with abduction deficit (-2) (Krimsky 20 PD). After 3 months we performed second operation, traction test was positive in abduction, right MR was recessed 5 mm and AM was placed.

Case 4

Explorative operation was planned for him since details about previous surgery was not known. In the operation traction test of the left eye was positive both in abduction and adduction and left MR was found 10 mm behind the limbus. Heavy scar tissue due to possible orbital fat tissue herniation resulted from his previous surgery was observed around the muscle. The fibrous scar tissue was excised and AM was placed. Conjunctival recession of 7 mm was performed.

Conclusions

Despite the best preoperative evaluation and surgical technique,

reoperation will continue to be a part of strabismus management. Strabismus reoperations aim to achieve stable alignment, full ocular rotations with no incomitance and good cosmetics with the fewest surgical procedures [7].

Mechanical restrictions to ocular rotations are primarily found at three anatomic sites. First, the conjunctiva may be foreshortened after long-standing deviations or inappropriate conjunctival closure from prior surgical procedures. A characteristic string or indentation sign is observed when the conjunctiva contributes to a restriction. Second the muscle restriction follows contracture or excessive resections. Third, the scar tissue formation may lead to a 'surgical leash' that restricts ocular rotations [8]. Intraoperative forced duction testing is very important in demonstrating the relief of restrictions [9]. In our study, forced duction testing was positive preoperatively and negative at the end of the surgery in all cases.

Various materials and pharmaceuticals have been used to decrease the occurrence of postoperative adhesion and scar formation [10-13]. However none of them are in use now because of their side effects and inconstant results. In experimental studies steroids and anti metabolites were used to decrease postoperative scar formation. However increase in the intraocular pressure, and increase in the risk of anterior segment ischemia were noted with their use [14-16].

AM transplantation has been used for multiple purposes in ophthalmic surgery. It's most often used in ocular surface reconstruction [17]. It has been shown to reduce stromal inflammation, fibrosis and immunogenicity in experimental models. In our country, fresh or cryo preserved AM could be used for ocular surgery. FDA's ruling that fresh AM is not permissible for clinical practices in the USA. Fresh AM is a cost-effective alternative (actually has no cost to patients) to cryo preserved AM. The preparation technique suggested by Kim and Tseng increased the bioavailability of cryopreserved AM [18,19]. The biological properties of these membranes are similar except the viability of the epithelial cells [20]. Cryo preserved AM has no viable cells therefore theoretically has less cytokines and growth factors. Due to the availability of several biological factors in AM, epithelialization and healing with reduced fibrosis are facilitated when transplanted on the ocular surface. The presence of inflammation-inhibiting chemokines in AM reduces neo vascularization and fibrosis during the healing process. It has been demonstrated that the matrix of the amniotic membrane, rather than viable amniotic cells, is responsible for these effects [20]. So cryopreserved AM which is a safer alternative to fresh AM when the risk of transmission of viral or prion diseases and the risk of causing an immunological reaction by the viable amnion epithelial cells considered, could be used in a same manner with similar outcomes. In a recent experimental controlled strabismus surgery study, AM was used under the superior rectus muscle of pigmented rabbits to prevent fibrosis and adhesion formation. According to their results, AM has antifibrotic effect and has an effective role in prevention of adhesion formation with possible physical barrier action [21]. Also

	AGE	VISUAL ACUITY	PREOP DEVIATION	POSTOP DEVIATION	PREOP DUCION DEFICIT	POSTOP DUCION DEFICIT	FOLLOW-UP TIME
PATIENT 1	18	10/10 RE 8/10 LE	75 PD ET	25 PD ET	-4 ABD	-2 ABD	24 MONTHS
PATIENT 2	20	5/100 RE 10/10 LE	45 PD XT	ORTHOTROPIA	-2 ADD	0	18 MONTHS
PATIENT 3	4	NA	20 PD ET	ORTHOTROPIA	-2 ABD	0	12 MONTHS
PATIENT 4	26	10/10 RE 5/100 LE	25 PD ET	ORTHOTROPIA	-2 ABD -1 ADD	-1 ADD	18 MONTHS

Table 1: Clinical features of 4 patients with restrictive strabismus.

a case report describing the use of AM to reduce adhesion formation in a patient with consecutive esotropia and limited ductions, showed possible benefits of this procedure [22].

In our study we used AM in 3 patients with conjunctival recession to cover the bare sclera in order to facilitate conjunctivalisation. All patients had successful outcome after AM transplantation with complete reepithelization of the conjunctival defect. No scarring resulted in secondary restriction was identified in the area of AM transplantation. Also no immunological reaction was observed postoperatively. Our surgical procedure was slightly different than the procedures used in previous studies [3-6]. Two sheets of AM under and over the EOM were sutured to sclera therefore both sheets of AM were stable after

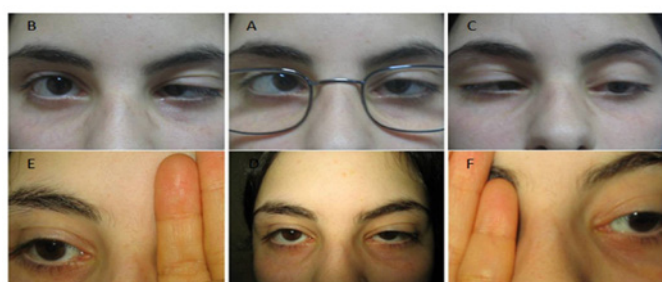


Figure 1: Early post-operative period of amniotic membrane transplantation. **A:** Pre-operative picture of patient 1 in primary position. **B:** Pre-operative picture of patient 1 showing right abduction deficit (-4). **Figure 1-C:** Pre-operative picture of patient 1 showing left abduction deficit (-4). **D:** Post-operative picture of patient 1 in primary position. **E:** Post-operative picture of patient 1 showing right abduction deficit (-2). **F:** Post-operative picture of patient 1 showing left abduction deficit (-2).

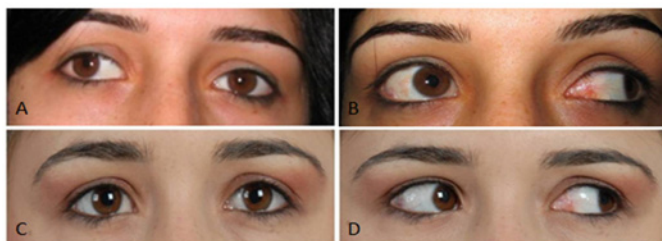


Figure 2: Late post-operative period of amniotic membrane transplantation. **A:** Pre-operative picture of patient 2 in primary position. **B:** Pre-operative picture of patient 2 showing right adduction deficit (-2). **C:** Post-operative picture of patient 2 in primary position. **D:** Post-operative picture of patient 2 showing no right adduction deficit.

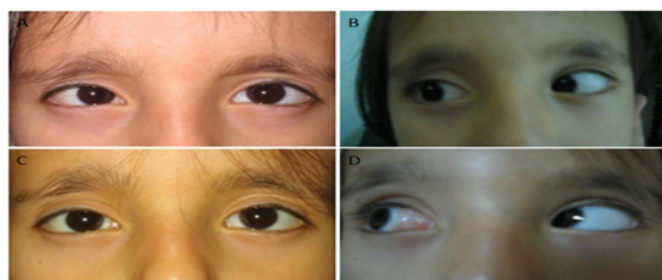

Figure 3: **A:** Pre-operative picture of patient 3 in primary position. **B:** Pre-operative picture of patient 3 showing right abduction deficit (-2). **C:** Post-operative picture of patient 3 in primary position. **D:** Post-operative picture of patient 3 showing no right abduction deficit.

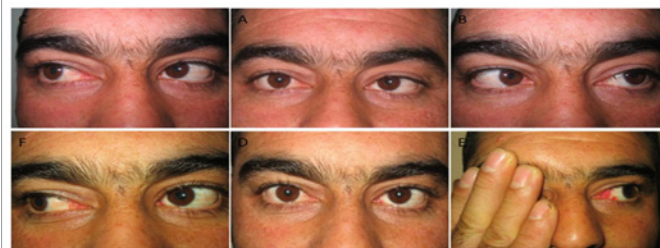

Figure 4: **A:** Pre-operative picture of patient 4 in primary position. **B:** Pre-operative picture of patient 4 showing left abduction deficit (-2). **C:** Pre-operative picture of patient 4 showing left adduction deficit (-1). **D:** Post-operative picture of patient 4 in primary position. **E:** Post-operative picture of patient 4 showing no left abduction deficit. **F:** Post-operative picture of patient 4 showing left adduction deficit (-1).

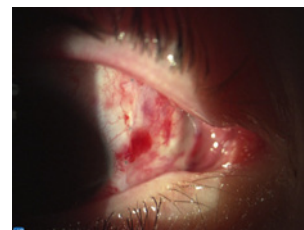

Figure 5:

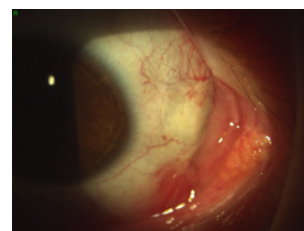


Figure 6:

the surgery. We believe this was a very important factor leading to improvements in duction deficits by inhibiting fibrosis and restrictions around the muscle. Stroma of AM has been found to suppress transforming growth factor β signaling and down regulate fibroblasts, thereby reducing inflammation and scarring [23]. For this reason, we placed stromal side of AM facing towards the tenon's capsule in order to decrease postoperative scar formation. Postoperatively ductions in all patients had improved.

Since, patients presented in this study had unique features; it is very difficult to conclude that good outcomes solely resulted from the use of AM. It is possible the outcomes would have been similar without AM. One of the potential limitations of the study is the lack of a control group. But when the unique features of these complicated cases were considered, it would be very difficult to make a study with a comparison group. This could also be the reason why the authors of the previous studies demonstrating the use of AM in complicated strabismus cases presented case reports or case series instead of control grouped studies [3-6]. The results of the previous experimental and clinical studies and results of our study suggest that there may be a role for AM in cases of restrictive strabismus. Further controlled clinical studies should be performed to show the real benefits of this procedure.

References

1. Helveston EM (1979) Reoperations in Strabismus. *Ophthalmol* 86: 1379-1388.
2. Wright KW (1986) The fat adherence syndrome and strabismus after retina surgery. *Ophthalmology* 93: 411-415.
3. Yamada M, Shinoda K, Hatakeyama A, Nishina S, Mashima Y (2001) Fat adherence syndrome after retinal surgery treated with amniotic membrane transplantation. *Am J Ophthalmol* 132: 280-282.
4. Sheha H, Casas V, Hayashida Y (2009) The use of amniotic membrane in reducing adhesions after strabismus surgery. *JAAPOS* 13: 99-101.
5. Kersey JP, Vivian AJ (2008) Mitomycin and amniotic membrane: a new method of reducing adhesions and fibrosis in strabismus surgery. *Strabismus* 16: 116-118.
6. Strube YN, Conte F, Faria C, Yiu S, Wright KW (2011) Amniotic Membrane Transplantation for Restrictive Strabismus. *Ophthalmology*.
7. Jampolsky A (1975) Strabismus reoperation techniques. *Trans Am Acad Ophthalmol Otolaryngol* 79: 704-717.
8. Rosenbaum-Santiago (1999) Clinical Strabismus Management Principles and Surgical Techniques: Strabismus Reoperation: Strategies and techniques, chapter 38.507-515.
9. Metz HS (1983) Restrictive factors in strabismus. *Surv Ophthalmol* 28: 71-83.
10. Sondhi N, Ellis FD, Hamed LM, Helveston EM (1987) Evaluation of an absorbable muscle sleeve to limit postoperative adhesions in strabismus surgery. *Ophthalmic Surg* 18: 441-443.
11. Elsas FJ, Gowda DC, Urry DW (1992) Synthetic polypeptide for strabismus surgery. *J Pediatr Ophthalmol Strabismus* 29: 284-286.
12. Fulga V, Koren R, Ezov N, Gal R, Nimrod A, Savir H (1996) Sodium hyaluronate as a tool in strabismus surgery in rabbits. *Ophthalmic Surg Lasers* 27: 228-233.
13. Ozkan SB, Kir E, Culhaci N, Dayanir V (2004) The effect of Seprafilm on adhesions in strabismus surgery – An experimental study. *J AAPOS* 8: 46-49.
14. De Carvalho LE, Alves MR, da Silva MA, Gaal Vadas MF (2007) Experimental strabismus surgery using triamcinolone: Outcomes and effects on inflammatory response. *Arq Bras Oftalmol* 70: 209-215.
15. Cruz OA (1996) Evaluation of Mitomycin to limit postoperative adhesions in strabismus surgery. *J Pediatr Ophthalmol Strabismus* 33: 89-92.
16. Mora JS, Sprunger DT, Helveston EM, Evan AP (1997) Intraoperative sponge 5-fluorouracil to reduce postoperative scarring in strabismus surgery. *J AAPOS* 1: 92-97.
17. Azuara-Blanco A, Pillai CT, Dua HS (1999) Amniotic membrane transplantation. *Br J Ophthalmol* 83: 399-402.
18. Kim JC, Tseng SCG (1995) Transplantation of preserved human amniotic membrane for surface reconstruction in severely damaged rabbit corneas. *Cornea* 14: 473-484.
19. Lee SH, Tseng SCG (1997) Amniotic membrane transplantation for persistent epithelial defects with ulceration. *Am J Ophthalmol* 123: 303-312.
20. Kruse FE, Jousen AM, Rohrschneider K, You L, Sinn B, et al. (2000) Cryopreserved human amniotic membrane for ocular surface reconstruction. *Graefes Arch Clin Exp Ophthalmol* 238: 68-75.
21. Demirel S, Atilla H, Okcu Heper A, Erkam N (2009) Effects of amniotic membrane on wound healing and adhesions in experimental strabismus surgery. *Eur J Ophthalmol* 19: 899-904.
22. Sheha H, Casas V, Hayashida Y (2009) The use of amniotic membrane in reducing adhesions after strabismus surgery. *J AAPOS* 13: 99-101.
23. Ghoi T, Tseng S (1990) In vivo demonstration of suppression of scarring and autologous blood-induced inflammation by intrastromal implantation of human amniotic membrane in rabbit corneas. *Invest Ophthalmol Vis Sci* 40: 5328.

Submit your next manuscript and get advantages of OMICS Group submissions

Unique features:

- User friendly/feasible website-translation of your paper to 50 world's leading languages
- Audio Version of published paper
- Digital articles to share and explore

Special features:

- 100 Open Access Journals
- 10,000 editorial team
- 21 days rapid review process
- Quality and quick editorial, review and publication processing
- Indexing at PubMed (partial), Scopus, DOAJ, EBSCO, Index Copernicus and Google Scholar etc
- Sharing Option: Social Networking Enabled
- Authors, Reviewers and Editors rewarded with online Scientific Credits
- Better discount for your subsequent articles

Submit your manuscript at: www.editorialmanager.com/clinicalgroup

