

Primary Conjunctival Tuberculosis-A Rare Presentation

Kafil Akhtar*, Murad Ahmad, Abdul Waris and Athar Ansari

Department of Pathology, Jawaharlal Nehru Medical College, Aligarh Muslim University, Aligarh, UP, India

*Corresponding author: Kafil Akhtar, Department of Pathology, Jawaharlal Nehru Medical College, Aligarh Muslim University, Aligarh, UP, India, Tel: 00919568467777; E-mail: drkafilakhtar@gmail.com

Received date: March 05, 2016; Accepted date: May 09, 2016; Published date: May 16, 2016

Copyright: © 2016 Akhtar K, et al. This is an open-access article distributed under the terms of the Creative Commons Attribution License, which permits unrestricted use, distribution, and reproduction in any medium, provided the original author and source are credited

Abstract

Tuberculosis is an infectious disease, commonly affecting the lungs. However, tuberculosis primarily affecting the conjunctiva is rare. Symptoms and signs of unilateral conjunctivitis may masquerade as primary conjunctival tuberculosis. In an endemic country like India, laterality, chronicity and non-resolution of symptoms with steroids are indications for pursuing a biopsy earlier than later. We report a case of 10 year old boy who presented with left eye discharge, redness with itching and a 1.5 x 1.0 cm palpebral growth for one month duration. Excision biopsy of the palpebral conjunctival lesion revealed necrotizing granulomatous inflammation suggestive of tuberculosis. Systemic examination showed no abnormality. He was started on anti-tubercular therapy. There was complete resolution of sign and symptoms with the initial treatment of 2 months duration.

Keywords: Conjunctiva; Tuberculosis; Histopathology

Introduction

Ocular tuberculosis is comparatively rare in patients with frank pulmonary tuberculosis. The incidence of manifest ocular involvement in TB Sanatoria patients is less than 0.1% [1]. It is usually seen in apparently healthy individuals who show evidence of an old or healed focus only. The mode of ocular involvement in tuberculosis may be direct organismal infection following a tuberculosis bacillaemia or an allergic (hypersensitivity) reaction to tubercular protein. Primary ocular tuberculosis (exogenous, air borne infection) is uncommon.

In India, although systemic tuberculosis is rampant, ocular involvement is a rarity. The most common ocular disease in tuberculous patients was phlycten [2]. The case being reported here had both epibulbar and intra-ocular lesions.

Case Summary

A young male, aged 30 years presented in the Ophthalmology Department with complaints of right sided headache, pain, watering and redness in the right eye for two months. It was associated with rapid deterioration of vision over the same period. He also noticed a gradually increasing reddish yellow mass in the medial aspect of the right eye for the same duration. For the last 6 weeks the patient also complained of intermittent moderate grade fever with weight loss with no history of cough. The General examination revealed an ill-looking pale, thin built young male with low grade pyrexia (100°F) without any lymphadenopathy. Systemic examination revealed scattered bilateral pulmonary rales.

On ocular examination, the right eye showed conjunctival and ciliary congestion with a single reddish yellow, soft, non-tender nodule on the medial aspect of the right palpebral conjunctiva. Examination of the anterior segment revealed presence of aqueous flare, no keratic precipitates or diffuse muddiness of the iris.

Hemogram was normal with raised ESR of 60 mm in 1st hour (Westergren). Chest radiograph showed no evidence of tuberculosis.

Mantoux test was negative. Sputum for acid fast bacillus revealed mycobacterium tuberculosis. Scraping from the centre of the lesion was positive for AFB on Ziehl Neelsen stain. Culture from the same lesion showed bacterial colonies. Excision biopsy was performed and microscopic examination of the growth showed necrotizing granulomatous inflammation characterized by epithelioid cells and langan's giant cells along with lymphocytes suggestive of tuberculosis (Figures 1 and 2). The patient was treated with Tab. Rifampicin +Isoniazid 450 mg, Tab. Ethambutol 500 mg and Inj. streptomycin sulphate 0.75 g daily. The patient showed clinical improvement after 2 months of anti-tubercular treatment. The histopathologic biopsy and the therapeutic response to anti-tubercular treatment led to confirmation of the diagnosis. No evidence of ocular toxicity was seen with the above medication.

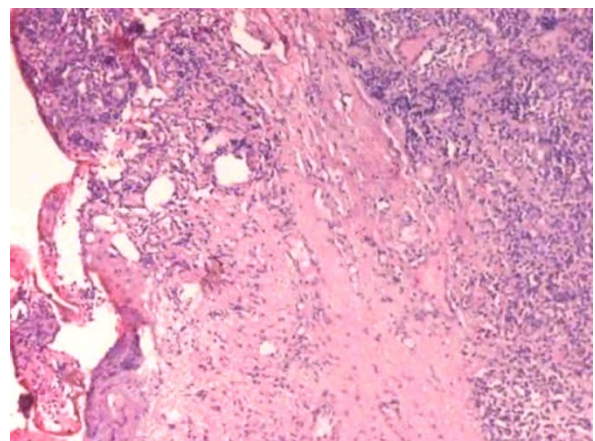


Figure 1: Microscopic examination of the palpebral growth shows necrotizing granulomatous inflammation characterized by epithelioid cells and langan's giant cells along with lymphocytes. (Haematoxylin and Eosin 100X).

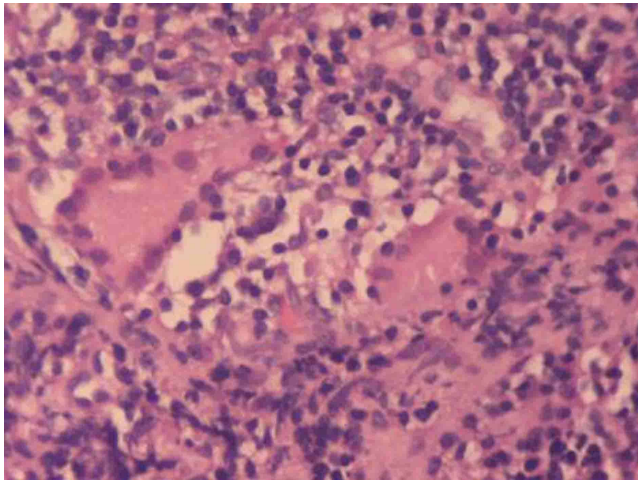


Figure 2: Necrotizing granulomatous inflammation characterized by epithelioid cells and Langhans' giant cells along with lymphocytes. (Haematoxylin and Eosin 400X).

Discussion

Proved cases of tuberculosis of conjunctiva are quite rare [3-5]. Conjunctival tuberculosis secondary to systemic involvement is of exceedingly rare occurrence since conjunctival involvement if at all, is most commonly associated with direct inoculation of organisms into the conjunctiva or is by contiguous spread [6,7].

Conjunctival tuberculosis can assume different forms like ulcerative, nodular, polypoidal and hypertrophic capillary type depending upon the mechanism of infection and perhaps also on the state of immunity or allergy of the patient. The formation of subconjunctival tuberculoma is characterised by coagulative necrosis and caseation as toxic reaction to *Mycobacterium tuberculosis* [8,9]. This form of manifestation is uncommon and likely to be confused with necrotising scleritis. In the present case, the diagnosis was confirmed by the demonstration and the culture of mycobacteria by standard Ziehl Neelsen procedure. Conjunctival lesion in this patient probably represented an endogenous infection during the stage of tuberculous bacillaemia.

The most striking characteristic of ocular tuberculosis is the marked pleomorphism of the lesions. The intraocular involvement in miliary tuberculosis is usually in the form of miliary tubercles or tuberculoma of the choroid [10]. In our case the intraocular involvement was atypical conglomerate tubercle in the palpebral conjunctiva with inflammation and necrosis into the surrounding tissues. An eye lost due to intraocular inflammation (Acute tuberculous endophthalmitis) without any clinical evidence of pulmonary tuberculosis was reported by Sorsby [4]. The histopathology of the lesion was confirmed to be *Mycobacterium tuberculosis*. The general condition of the patient unproved favourably with the anti-tubercular chemotherapy though the response was slow.

Conclusion

The case was unusual in that the endogenous infection caused palpebral growth in the conjunctiva. Detailed clinical assessment is imperative and often guides treatment in clinical practice. In areas endemic for infectious disease, like tuberculosis, the threshold for pursuing histopathologic biopsy should be adequate. This approach could be "eye saving" as definitive treatments are available.

References

1. WHO. Global tuberculosis control: A short update to the 2009 report.
2. Sollom AW (1967) Primary conjunctival tuberculosis. *Br J Ophthalmol* 51: 685-687.
3. Rao PN, Bhat KS (1967) Active systemic lesions in cases of suspected ocular tuberculosis. *J All Ind Ophthal Soc* 15: 175-180.
4. Sorsby A (1963) Ocular Tuberculosis. *Modern Ophthalmology*, London, Butter Worths 117: 456-467.
5. Archer D, Bird A (1967) Primary Tuberculosis of the Conjunctiva. *Br J Ophthalmol* 51: 679-684.
6. Rose JS, Arthur A, Raju R, Thomas M (2011) Primary Conjunctival Tuberculosis in a 14 Year Old Girl. *Ind J Tuberculosis* 58: 32-34.
7. Lamba PA, Srinivasan R (1983) Conjunctival tuberculosis of endogenous origin associated with miliary tuberculosis. *Indian J Ophthalmol* 31: 89-92.
8. Tulvatana W, Sansopha L, Pisarnkorskul P (2001) Primary conjunctival tuberculoma: A case report. *J Med Assoc Thai* 84: 127-130.
9. Jennings A, Bilous M, Asimakis P, Maloof AJ (2006) *Mycobacterium tuberculosis* presenting as chronic red eye. *Cornea* 25: 1118-1120.
10. Biswas J, Kumar SK, Rupauliha P, Misra S, Bharadwaj I, et al. (2002) Detection of *Mycobacterium tuberculosis* by nested Polymerase Chain Reaction in a case of subconjunctival tuberculosis. *Cornea* 21: 123-125.