

## Th1 Chemokine CXCL10 and Alopecia Areata: The Possible Target for the Treatment of Alopecia Areata

Taisuke Ito\*, Toshiharu Fujiyama and Yoshiki Tokura

Department of Dermatology, Hamamatsu University School of Medicine, Hamamatsu, 1-20-1 Handayama, Higashi-ku, Hamamatsu 431-1192, Japan

\*Corresponding author: Taisuke Ito, Department of Dermatology, Hamamatsu University School of Medicine, Hamamatsu, 1-20-1 Handayama, Higashi-ku, Hamamatsu 431-1192, Japan, Tel: +81 53 435 2303; Fax: +81 53 435 2368; E-mail: [itoutai@hama-med.ac.jp](mailto:itoutai@hama-med.ac.jp)

Received date: July 18, 2016; Accepted date: September 09, 2016; Published date: September 16, 2016

Copyright: © 2016 Ito T, et al. This is an open-access article distributed under the terms of the Creative Commons Attribution License, which permits unrestricted use, distribution, and reproduction in any medium, provided the original author and source are credited.

### Abstract

Alopecia areata (AA) is an organ-specific and cell-mediated autoimmune disease. Recent studies have suggested the most important effector cell of AA is NKG2D<sup>+</sup>CD8<sup>+</sup>T cells, and outer root sheath (ORS) cells highly express NKG2D ligands, such as MICA, in AA lesions. T lymphocytes densely surround lesional hair bulbs, which is histologically referred to as "swarm of bees". Immunohistochemical and real-time RT-PCR studies reveal that hair follicles of acute-phase AA expressed a high level of Th1-associated chemokine CXCL10. In the skin lesions of acute-phase AA, CXCR3<sup>+</sup>CD4<sup>+</sup> and CXCR3<sup>+</sup>CD8<sup>+</sup> T cells infiltrated in the juxta-follicular area. In chronic-phase AA, CXCR3<sup>+</sup>CD8<sup>+</sup> T cells dominated the infiltrate around hair bulbs, possibly contributing to the prolonged state of hair loss. Lymphocytes obtained from a lesional skin of acute-phase AA contained CXCR3<sup>+</sup>CD4<sup>+</sup> and CXCR3<sup>+</sup>CD8<sup>+</sup> T cells at higher percentages than those of PBMCs, suggesting preferential emigration from the blood. Furthermore, freshly isolated PBMCs from acute-phase AA patients had a strong velocity of chemotaxis toward CXCL10 with increased expression of F-actin. Antihistaminic drugs have been used in Japan, and these have possibility to down-regulate chemotactic activity in AA. Olopatadine shows suppressive effects of chemotactic activity in the AA patients' CD4<sup>+</sup> and CD8<sup>+</sup> T cells towards CXCL10 by reducing CXCR3 expression, F-actin polymerization, and Ca<sup>++</sup> influx. In conclusion, the increased production of CXCL10 from hair follicles induces preferential infiltrates of Th1 and Tc1 cells in the acute phase of AA, and Tc1 infiltration remains prolonged in the chronic phase. Therefore, inhibitory treatment of chemotactic activity might be novel target for the treatment of AA.

**Keywords:** Alopecia areata; Chemokine; Chemotaxis; Swarm of bees; T cell

### Introduction

Alopecia areata (AA) has recently been shown to be a tissue-specific autoimmune disease [1,2]. A T-cell-mediated immune reaction may induce hair loss based on autoimmune etiopathogenesis [3]. The hair follicle (HF) autoantigen is not quite completely identified, but melanocyte-related protein has been suggested as a strong candidate [4-6].

In the physiological condition, autoantigens generated by anagen HFs should be protected from recognition by autoreactive T cells. Therefore, anagen hair bulbs may maintain an immunoprivileged milieu at the proximal outer root sheath (ORS) and hair matrix by creating immunotolerated milieu, such as low or absent expression of major histocompatibility complex (MHC) class I, the substantial expression of immunosuppressants, and the rare distribution of immune cells [7-15]. However, as shown in Figure 1, if hair follicle immune privilege (HF-IP) is collapsed by stressors, autoantigens are revealed, resulting in an autoimmune reaction by NKG2D<sup>+</sup>CD8<sup>+</sup> autoreactive T cells that causes the unique pathological feature called "swarm of bees" in the acute phase of AA. Th1 cytokines, as represented by interferon (IFN)- $\gamma$ , are dominantly detected in AA lesions and may induce the collapse of HF-IP, including the up-regulation of MHC class I [16]. In addition to IFN- $\gamma$  IL-15 is also another key cytokine. IL-15 is over expressed in keratinocytes of AA lesions, and IL-15 activates and proliferates cytotoxic T cells [17]. JAK inhibitors, such as ruxolitinib, tofacitinib and baricitinib, may down-

regulate IFN- $\gamma$  and IL-15 expression that bring improvement of hair loss lesions in AA [17]. Recent idea of the pathogenesis of AA, especially between hair follicle keratinocyte and CD8<sup>+</sup> T cell is suggested in Figure 2.

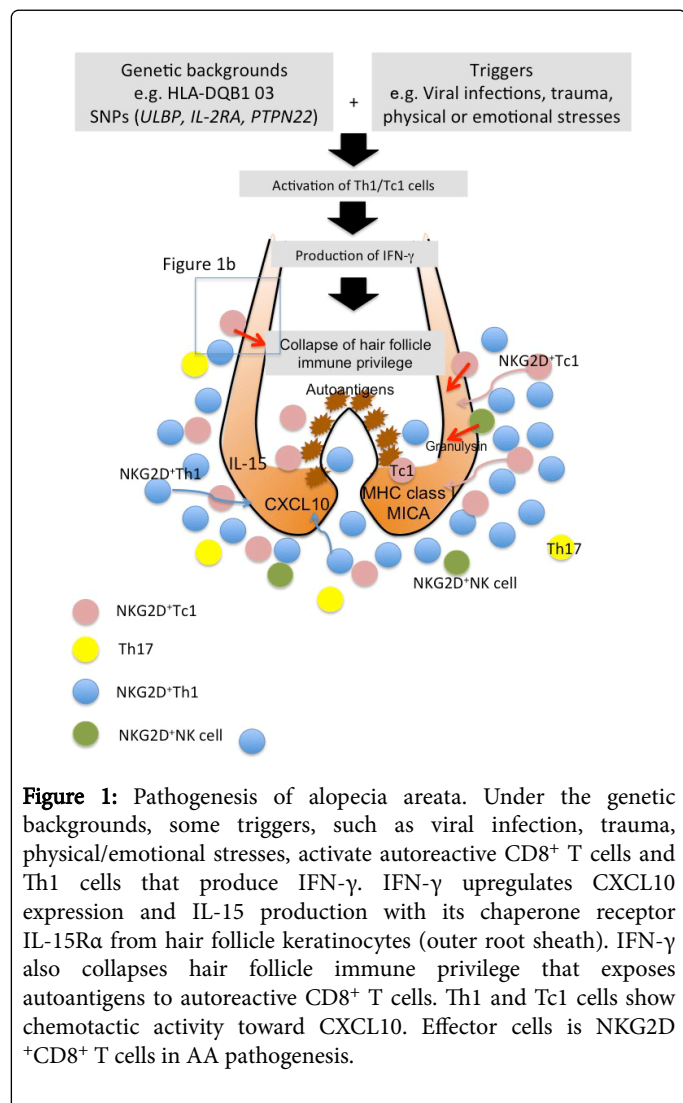
There have been several studies on the expression of chemokines and their receptors in AA lesions [18,19]. For example, IFN- $\gamma$ -inducible expression of Th1 chemokines, CXCL9/MIG and CXCL10/IP-10, were detected in the lesions of AA patients [18,20]. CXCL9 was elevated in human AA, and its level correlated with disease activity [21]. Transcriptional profiling was also demonstrated and CXCL10 was highly up-regulated in AA lesion compared to non-lesional skin [22].

CXCR3<sup>+</sup> Th1 and Tc1 cells may favorably infiltrate the sites that show high expression of Th1 chemokines, CXCL9/MIG and CXCL10/IP-10. Actually, we have already reported the dense infiltration of CXCR3<sup>+</sup>CD4<sup>+</sup> Th1 cells and CXCR3<sup>+</sup>CD8<sup>+</sup> Tc1 cells. Therefore, inhibition of chemotactic activity might be candidate for the novel treatment of AA.

### Expression of Th1/Tc1 chemokine CXCL10/IP-10 in AA lesion

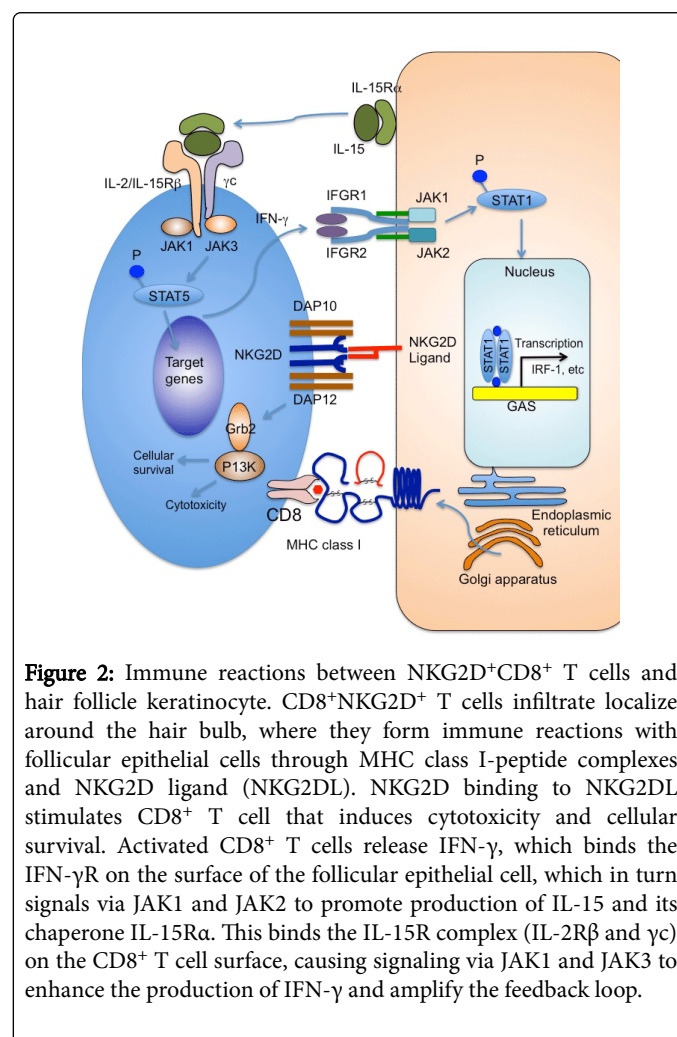
There have been several studies on the expression of chemokines and their receptors in AA lesions. In a mouse model, murine AA skin-grafted mice showed a marked increase of Th1/Tc1 chemokine, CXCL9 and CXCL10, as early as five weeks post-transplant before the development of AA [23]. It can be speculated that upregulation of Th1/Tc1 chemokine induces accumulation of Th1 and Tc1 cells around hair bulbs, so called "swarm of bees" [23]. In a study by Gilhar et al.,

biopsied human AA samples were grafted onto SCID mice that showed hair regrowth because the grafted skin escaped from autoimmune reactions. Subsequently, the patients' lesional T cells, which had been cultured with follicular homogenate, melanocyte peptides, or human melanoma cell homogenate, were injected into the grafted area [18] that resulted in recurrence of AA. The frequency of SCID mouse with CXCL10<sup>+</sup> AA lesions were significantly higher in T cell-injected (13/13) compared to non-injected (2/9) grafts ( $P < 0.002$ , two-sided Fisher's exact test). Other studies have also shown Th1 chemokines, CXCL9/MIG and CXCL10/IP-10, in the lesions of AA patients [19,20]. Our study also revealed that the CXCL10 immunoreactivity was found in the outer and inner root sheath epithelial cells, dermal papilla cells, and juxta-follicular interstitial cells, while normal HFs showed slight CXCL10 staining in the outer root sheath. By RT-PCR, mRNA expression of CXCL10 was observed in the lesional skin of acute-phase AA but not in a normal skin [24]. Upregulation of CXCL10 in AA lesions compared with non-lesional skin was also reported in other transcriptional profiling study [22]. Chemokines (CX3CL1, CXCL1, CCL5 and CXCL10) associated with cellular immunity were overexpressed in AA skin. CX3CL1 and CXCL10 are not only induced by IFN- $\gamma$ , but also act as an amplifier of polarized Th1 responses [25].



### Infiltration of Th1/Tc1 cells around hair bulb in AA lesion

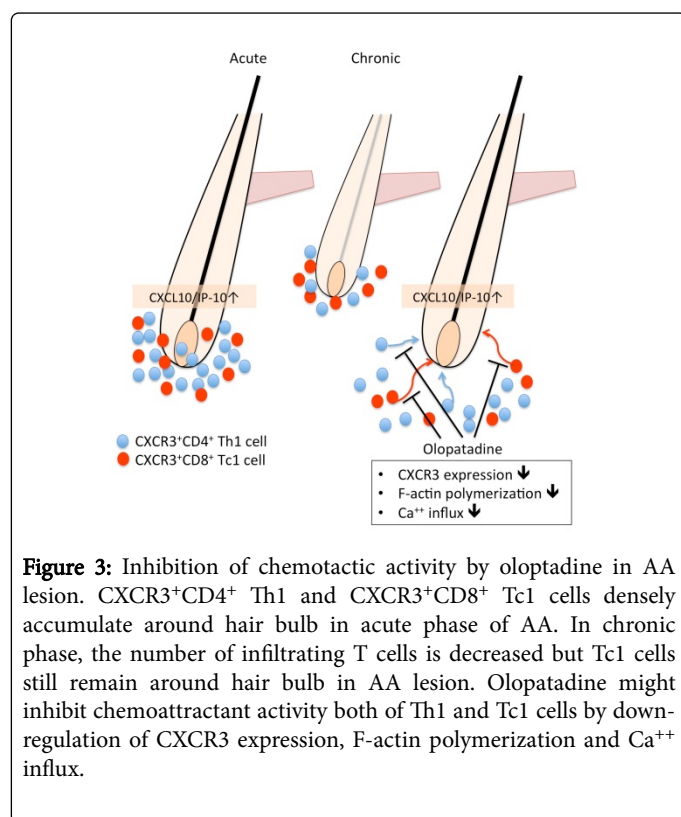
We have reported that CXCR3<sup>+</sup> T cells markedly infiltrated in and around the hair bulbs compared with CCR4<sup>+</sup> T cells in acute phase of AA. In the chronic phase of AA, CD4<sup>+</sup> T cells around the HFs were decreased in number while the infiltration of CD8<sup>+</sup> T cells remained constant. In this phase, the accumulation of CXCR3<sup>+</sup> T cells was denser than CCR4<sup>+</sup> T cells (Figure 1). The number of CXCR3<sup>+</sup>CD4<sup>+</sup> Th1 cells in PBMCs was significantly higher in acute phase AA patients than in chronic phase AA patients or healthy controls [24]. Another study showed dominant infiltration of CCR5<sup>+</sup> Th1 cells relative to CCR4<sup>+</sup>Th2 cells in the C3H/HeJ mouse model [26].



### Chemotactic activity and F-actin polymerization of Th1/Tc1 cells in AA

Interestingly, real-time horizontal chemotaxis assay showed that the chemotactic velocities of circulating CD4<sup>+</sup> and CD8<sup>+</sup> T cell towards CXCL10 in acute phase AA were higher than those in chronic phase AA and in healthy controls, suggesting that Th1 and Tc1 are activated in the peripheral blood of acute phase AA patients [24]. Time-lapse images of cell migration during chemotaxis were observed directly with an optically accessible horizontal chemotaxis apparatus EZ-TAXIScan (Effector Cell Institute, Kanagawa, Japan) via a CCD camera (GE Healthcare, Tokyo, Japan) as described previously (Figure 2)

[24,27]. The functional ability of circulating T cells to migrate toward chemokines was photo-documented by EZ-TAXIScan, and the chemoattracted extent of T cells was plotted and analyzed by Image J software. CD4<sup>+</sup> T cells were isolated from PBMCs of AA patients and healthy individuals and subjected to the chemotaxis assay. CD4<sup>+</sup> T cells from a patient with acute-phase AA migrated roughly straightly to the CXCL10 top chamber, while those from a normal control subject reached the CXCL10 chamber with wondering movement. The migration of AA patient's CD4<sup>+</sup> T cells to CCL17/TARC was not accelerated. The migration traces of CD4<sup>+</sup> and CD8<sup>+</sup> T cells are exhibited in the functions of time and distance, and the velocity levels were calculated in acute-phase AA patients, chronic phase AA patients, and normal control subjects (n=5/each). The velocity of CD4<sup>+</sup> T cells toward CXCL10 was significantly higher in acute-phase AA than in chronic-phase AA or control. Similarly, CD8<sup>+</sup> T cells of acute-phase AA effectively migrated to CXCL10 as compared to those of chronic-phase AA and healthy control. FACS analysis revealed that the expression of F-actin in CD4<sup>+</sup> T cells was elevated in acute-phase AA patients. The mean fluorescent intensity (MFI) of 3 acute-phase and 3 chronic-phase AA patients was higher than those of healthy control. Thus, the higher expression of F-actin may induce strong velocity of CXCR3<sup>+</sup> T cells to CXCL10 in acute-phase AA patients.



**Figure 3:** Inhibition of chemotactic activity by olopatadine in AA lesion. CXCR3<sup>+</sup>CD4<sup>+</sup> Th1 and CXCR3<sup>+</sup>CD8<sup>+</sup> Tc1 cells densely accumulate around hair bulb in acute phase of AA. In chronic phase, the number of infiltrating T cells is decreased but Tc1 cells still remain around hair bulb in AA lesion. Olopatadine might inhibit chemoattractant activity both of Th1 and Tc1 cells by down-regulation of CXCR3 expression, F-actin polymerization and Ca<sup>++</sup> influx.

### Inhibition of chemotactic activity by antihistaminic drug

Antihistaminic drugs have been widely used in the treatment of AA in Japan. Japanese guideline for AA recommends antihistaminic drug for the treatment of AA as C1 level [28]. For example, Antihistamine fexofenadine enhanced the efficacy of contact immunotherapy for extensive AA in patients with an atopic background [29]. In a murine study, AA was improved in mice by ebastine presumably by inhibiting T cell accumulation around the hair bulbs [30]. In the same paper,

authors show the successful hair regrowth achieved after 5-month by oral ebastine and topical corticosteroid treatment.

It is known that some antihistamines suppress keratinocyte production of chemokines such as CXCL10 [31], supporting their therapeutic efficacy for AA. For example, olopatadine suppressed the chemotactic activity of the AA patients' CD4<sup>+</sup> and CD8<sup>+</sup> T cells towards CXCL10 by reducing CXCR3 expression, F-actin polymerization, and Ca<sup>++</sup> influx. Antihistamines are known to suppress the production of chemokines [31,32]. In addition to the suppression of chemokine release, some of antihistamines, as represented by olopatadine, are capable of directly downmodulating the function of T cells to migrate toward chemokines (Figure 3) [24].

### Clinical availabilities for the treatment of AA

Present treatments of AA are actually same as a decade ago. U.S., British and Japanese guidelines of AA recommend several therapies including contact immunotherapy, local injection of corticosteroid, topical corticosteroid, oral corticosteroid, UV-irradiation including narrow-band UVB and eximer light, immunosuppressants, and minoxidil [28,33,34]. In these treatments, Japanese guideline strongly recommends contact immunotherapy and local injection of corticosteroid in the hair loss lesions as B level [28]. Although the mechanism of contact immunotherapy is still remained to be elucidated, Th1/Th2 cytokine balance might be affected as down-regulation of IFN- $\gamma$  and up-regulation of IL-4 [35]. Therefore, it can be speculated that the chemotactic activity of CXCR3<sup>+</sup>CD4<sup>+</sup> Th1 cells and CXCR3<sup>+</sup>CD8<sup>+</sup> Tc1 cells might be down-modulated by contact immunotherapy although there is no *in vivo/in vitro* evidence of suppressive effect in contact immunotherapy. High dose corticosteroid pulse therapy is also another possible treatment for acute phase AA [36,37]. This therapy might be not effective in chronic stage of AA, and should be applied on the patients suffering with AA within 6 months. Narrowband UVB or PUVA therapy is also alternative treatment for AA. However, there have been not enough data on UV-irradiation and chemotactic activity of T cells in AA although UVB irradiation of normal human skin favors the development of type-2 T-cells *in vivo* and in primary dermal cell cultures [38] and PUVA therapy may have suppressive effects on T cell migration *in vitro* [39].

### Frontal fibrosing alopecia and chemokines

Frontal fibrosing alopecia (FFA) is one of the cicatricial alopecia. This permanent hair loss disease is preferentially occurs at the front area of scalp, and it is sometimes needed to be distinguished with AA ophiasis which is characterized by the loss of hair in the shape of a wave at the circumference of the head [40]. Detailed pathogenesis of FFA is still unknown but recent study revealed that collapse of bulge immune privilege and inflammation-induced epithelial hair follicle stem cell death are key components in the progression of FFA [41]. As AA, accumulated T cells and hair follicle keratinocyte express CXCR3 and CXCL10, respectively that mean Th1/Tc1 tendency around hair follicle bulge area in FFA. Although topical and intradermal injection of corticosteroid have been used for the treatment of FFA, it is still very difficult to inhibit the progression to permanent hair loss. In addition, androgen might be associated with the establishment of FFA. Therefore, not only anti-inflammatory treatments but also anti-androgen therapies such as finasteride and dutasteride should be considered in the therapy of FFA [42]. Furthermore, recent studies suggest the contribution of epithelial-mesenchymal transition for the



pathogenesis of FFA [43]. Under these backgrounds, physicians should distinguish to handle the scarring and non-scarring alopecia.

## Summary and Future Clinical Perspectives

The pathogenesis of AA remains unclear but current studies strongly suggest a T cell-mediated autoimmune process, and effector cell is NKG2D<sup>+</sup>CD8<sup>+</sup> T cells. IFN- $\gamma$  and IL-15 are the key cytokines, and JAK inhibitors, such as ruxolitinib, tofacitinib and baricitinib, shows improvement of hair loss lesions in AA [17,44]. Even though tofacitinib and ruxolitinib are a promising novel treatment option, transient effect of JAK inhibitor has been reported [45]. The hallmark of pathological change in AA is the accumulation of lymphocytes around hair bulbs. Overexpression of the Th1 chemokine, CXCL10, induces the infiltration of CXCR3<sup>+</sup> Th1 cells around the hair bulbs in AA lesions. Therefore, the inhibition of chemotactic or cytokine activity could be novel therapies for AA. Our study has already shown that the antihistamine drug, olopatadine, downregulated T cell chemotaxis toward CXCL10 by reducing CXCR3 expression, F-actin polymerization and calcium influx in patients with AA [46]. Th1 chemokines and cytokines could be new target in solving the puzzle of the pathogenesis of AA.

## Conflict of Interest

The author declares that they have no conflict of interest.

## References

1. Lu W, Shapiro J, Yu M, Berekaitan A, Lo B, et al. (2006) Alopecia areata: pathogenesis and potential for therapy. *Expert Rev Mol Med* 8: 1-19.
2. Gilhar A, Kalish RS (2006) Alopecia areata: a tissue specific autoimmune disease of the hair follicle. *Autoimmun Rev* 5: 64-69.
3. Alkhalifah A, Alsantali A, Wang E, McElwee KJ, Shapiro J (2010) Alopecia areata update: part I. Clinical picture, histopathology, and pathogenesis. *J Am Acad Dermatol* 62: 177-188, quiz 189-90.
4. Paus R, Slominski A, Czarnetzki BM (1993) Is alopecia areata an autoimmune-response against melanogenesis-related proteins, exposed by abnormal MHC class I expression in the anagen hair bulb? *Yale J Biol Med* 66: 541-554.
5. Tobin DJ, Fenton DA, Kendall MD (1990) Ultrastructural observations on the hair bulb melanocytes and melanosomes in acute alopecia areata. *J Invest Dermatol* 94: 803-807.
6. Tobin DJ, Fenton DA, Kendall MD (1990) Ultrastructural study of exclamation-mark hair shafts in alopecia areata. *J Cutan Pathol* 17: 348-354.
7. Paus R, Nickoloff BJ, Ito T (2005) A 'hairy' privilege. *Trends Immunol* 26: 32-40.
8. Ito T, Ito N, Bettermann A, Tokura Y, Takigawa M, et al. (2004) Collapse and restoration of MHC class-I-dependent immune privilege: exploiting the human hair follicle as a model. *Am J Pathol* 164: 623-634.
9. Ito T, Ito N, Saato M, Hashizume H, Fukamizu H, et al. (2008) Maintenance of hair follicle immune privilege is linked to prevention of NK cell attack. *J Invest Dermatol* 128: 1196-1206.
10. Ito T, Takigawa M (2010) Immune privilege and alopecia areata. *Exp Rev Dermatol* 5: 141-148.
11. Bröcker EB, Echtenacht-Happle K, Hamm H, Happle R (1987) Abnormal expression of class I and class II major histocompatibility antigens in alopecia areata: modulation by topical immunotherapy. *J Invest Dermatol* 88: 564-568.
12. Paus R, Christoph T, Müller-Röver S (1999) Immunology of the hair follicle: a short journey into terra incognita. *J Invest Dermatol Symp Proc* 4: 226-234.
13. Welker P, Foitzik K, Bulfone-Paus S, Henz BM, Paus R (1997) Hair cycle-dependent changes in the gene expression and protein content of transforming factor beta 1 and beta 3 in murine skin. *Arch Dermatol Res* 289: 554-557.
14. Slominski A, Wortsman J, Mazurkiewicz JE, Matsuoka L, Dietrich J, et al. (1993) Detection of proopiomelanocortin-derived antigens in normal and pathologic human skin. *J Lab Clin Med* 122: 658-666.
15. Botchkarev VA, Botchkareva NV, Slominski A, Roloff B, Luger T, et al. (1999) Developmentally regulated expression of alpha-MSH and MC-1 receptor in C57BL/6 mouse skin suggests functions beyond pigmentation. *Ann N Y Acad Sci* 885: 433-439.
16. Arca E, Musabak U, Akar A, Erbil AH, Tastan HB (2004) Interferon-gamma in alopecia areata. *Eur J Dermatol* 14: 33-36.
17. Xing L, Dai Z, Jabbari A, Cerise JE, Higgins CA, et al. (2014) Alopecia areata is driven by cytotoxic T lymphocytes and is reversed by JAK inhibition. *Nat Med* 20: 1043-1049.
18. Gilhar A, Landau M, Assy B, Ullmann Y, Shalaginov R, et al. (2003) Transfer of alopecia areata in the human scalp graft/Prkdc(scid) (SCID) mouse system is characterized by a TH1 response. *Clin Immunol* 106: 181-187.
19. Benoit S, Toksoy A, Goebeler M, Gillitzer R (2003) Selective expression of chemokine monokine induced by interferon-gamma in alopecia areata. *J Invest Dermatol* 121: 933-935.
20. Gregoriou S, Papafragkaki D, Kontochristopoulos G, Rallis E, Kalogeromitros D, et al. (2010) Cytokines and other mediators in alopecia areata. *Mediators Inflamm* 2010: 928030.
21. Kuwano Y, Fujimoto M, Watanabe R, Ishiura N, Nakashima H, et al. (2007) Serum chemokine profiles in patients with alopecia areata. *Br J Dermatol* 157: 466-473.
22. Subramanya RD, Coda AB, Sinha AA (2010) Transcriptional profiling in alopecia areata defines immune and cell cycle control related genes within disease-specific signatures. *Genomics* 96: 146-153.
23. McPhee CG, Duncan FJ, Silva KA, King LE Jr, Hogenesch H, et al. (2012) Increased expression of Cxcr3 and its ligands, Cxcl9 and Cxcl10, during the development of alopecia areata in the mouse. *J Invest Dermatol* 132: 1736-1738.
24. Ito T, Hashizume H, Shimauchi T, Funakoshi A, Ito N, et al. (2013) CXCL10 produced from hair follicles induces Th1 and Tc1 cell infiltration in the acute phase of alopecia areata followed by sustained Tc1 accumulation in the chronic phase. *J Dermatol Sci* 69: 140-147.
25. Fratielli P, Sironi M, Bianchi G, D'Ambrosio D, Albanesi C, et al. (2001) Fractalkine (CX3CL1) as an amplification circuit of polarized Th1 responses. *J Clin Invest* 107: 1173-1181.
26. Nakamura M, Jo J, Tabata Y, Ishikawa O (2008) Controlled delivery of T-box21 small interfering RNA ameliorates autoimmune alopecia (Alopecia Areata) in a C3H/HeJ mouse model. *Am J Pathol* 172: 650-658.
27. Hashizume H, Seo N, Ito T, Takigawa M, Yagi H (2008) Promiscuous interaction between gold-specific T cells and APCs in gold allergy. *J Immunol* 181: 8096-8102.
28. Ito T (2012) Advances in the management of alopecia areata. *J Dermatol* 39: 11-17.
29. Inui S, Nakajima N, Toda N, Itami S (2009) Fexofenadine hydrochloride enhances the efficacy of contact immunotherapy for extensive alopecia areata: Retrospective analysis of 121 cases. *J Dermatol* 36: 323-327.
30. Ohyama M, Shimizu A, Tanaka K, Amagai M (2010) Experimental evaluation of ebastine, a second-generation anti-histamine, as a supportive medication for alopecia areata. *J Dermatol Sci* 58: 154-157.
31. Tokura Y, Kobayashi M, Kabashima K (2008) Epidermal chemokines and modulation by antihistamines, antibiotics and antifungals. *Exp Dermatol* 17: 81-90.
32. Sugita K, Kobayashi M, Mori T, Kabashima K, Nakamura M, et al. (2009) Antihistaminic drug olopatadine downmodulates CCL17/TARC production by keratinocytes and Langerhans cells. *J Dermatol* 36: 654-657.

33. Messenger AG, McKillop J, Farrant P, McDonagh AJ, Sladden M (2012) British Association of Dermatologists' guidelines for the management of alopecia areata 2012. *Br J Dermatol* 166: 916-926.
34. Olsen E, Hordinsky M, McDonald-Hull S, Price V, Roberts J, Shapiro J, Stenn K (1999) Alopecia areata investigational assessment guidelines. National Alopecia Areata Foundation. *J Am Acad Dermatol* 40: 242-246.
35. Hoffmann R, Wenzel E, Huth A, van der Steen P, Schäufele M, et al. (1994) Cytokine mRNA levels in Alopecia areata before and after treatment with the contact allergen diphenylcyclopropanone. *J Invest Dermatol* 103: 530-533.
36. Nakajima T, Inui S, Itami S (2007) Pulse corticosteroid therapy for alopecia areata: study of 139 patients. *Dermatology* 215: 320-324.
37. Yoshimasu T, Kanazawa N, Yamamoto Y, Furukawa F (2016) Multiple courses of pulse corticosteroid therapy for alopecia areata. *J Dermatol* 43: 1075-1077.
38. Di Nuzzo S, Sylva-Steenland RM, Koomen CW, Nakagawa S, van Breemen M, et al. (2002) UVB irradiation of normal human skin favors the development of type-2 T-cells in vivo and in primary dermal cell cultures. *Photochem Photobiol* 76: 301-309.
39. Okamoto H, Takigawa M, Horio T (1985) Alteration of lymphocyte functions by 8-methoxypsoralen and longwave ultraviolet radiation. I. Suppressive effects of PUVA on T-lymphocyte migration in vitro. *J Invest Dermatol* 84: 203-205.
40. Tziotzios C, Stefanato CM, Fenton DA, Simpson MA, McGrath JA (2016) Frontal fibrosing alopecia: reflections and hypotheses on etiology and pathogenesis. *Exp Dermatol*.
41. Harries MJ, Meyer K, Chaudhry I, Kloepper J, Poblet E, et al. (2013) Lichen planopilaris is characterized by immune privilege collapse of the hair follicle's epithelial stem cell niche. *J Pathol* 231: 236-247.
42. Georgala S, Katoulis AC, Befon A, Danopoulou I, Georgala C (2009) Treatment of postmenopausal frontal fibrosing alopecia with oral dutasteride. *J Am Acad Dermatol* 61: 157-158.
43. Nakamura M, Tokura Y (2010) Expression of Snail1 in the fibrotic dermis of postmenopausal frontal fibrosing alopecia: possible involvement of an epithelial-mesenchymal transition and a review of the Japanese patients. *Br J Dermatol* 162: 1152-1154.
44. Gupta AK, Carviel JL, Abramovits W (2016) Efficacy of tofacitinib in treatment of alopecia universalis in two patients. *J Eur Acad Dermatol Venereol* 30: 1373-1378.
45. Anzengruber F, Maul JT, Kamarachev J, Trüeb RM, French LE, et al. (2016) Transient Efficacy of Tofacitinib in Alopecia Areata Universalis. *Case Rep Dermatol* 8: 102-106.
46. Ito T, Fujiyama T, Hashizume H, Tokura Y (2013) Antihistaminic drug olopatadine downmodulates T cell chemotaxis toward CXCL10 by reducing CXCR3 expression, F-actin polymerization and calcium influx in patients with alopecia areata. *J Dermatol Sci* 72: 68-71.