

Severe Toxicity with Guanidine Thiocyanate Ingestion

Colin B Page^{1,2,3*}, Peter S Kruger^{1,4}, Goce Dimeski^{1,5} and James Walsham^{1,4}

¹School of Medicine, University of Queensland, Brisbane, Australia

²Clinical Toxicology Unit, Princess Alexandra Hospital, Brisbane, Australia

³Clinical Toxicology Research Group, University of Newcastle, Newcastle, Australia

⁴Intensive Care Unit, Princess Alexandra Hospital, Brisbane, Australia

⁵Department of Chemical Pathology, Pathology Queensland, Princess Alexandra Hospital, Brisbane, Australia

*Corresponding author: Colin B Page, School of Medicine, University of Queensland, Brisbane, Australia, Tel: 0011-64-0404044732; E-mail: cpage@bigpond.net.au

Received date: October 17, 2016; Accepted date: October 30, 2016; Published date: October 31, 2016

Copyright: © 2016 Page CB, et al. This is an open-access article distributed under the terms of the Creative Commons Attribution License, which permits unrestricted use, distribution, and reproduction in any medium, provided the original author and source are credited.

Abstract

Objective: To describe the toxicity of deliberate guanidine thiocyanate ingestion and its treatment including dialysis.

Case report: A 52-year-old male presented to hospital with abdominal pain after giving a history of ingesting bottled water. His initial vital signs and examination were normal. Soon after the patient became confused and agitated, necessitating intubation and ventilation for presumed encephalitis. His chloride was unmeasurable and the ionised calcium was low at 0.59 mmol/L (reference range [RR] 1.15-1.32 mmol/L). His pH and osmolar gap were normal. Analysis of the ingested water on two chemistry analysers gave discrepant chloride readings (129 mmol/L and 49 mmol/L) suggesting interference from a cross reacting analyte, which subsequently was proven to be thiocyanate with a concentration of 1485mg/L and 538mg/L in the bottled water and admission serum respectively (RR 0.1-4 mg/L). Dialysis in the form of continuous veno-venous haemodiafiltration (CVVHDF) was instituted based on this high level. Serial thiocyanate levels demonstrated zero order elimination kinetics pre dialysis and first order kinetics with a half-life of 5.4 h during dialysis. The patient made a full recovery and admitted to the addition of guanidine thiocyanate to the bottled water.

Discussion: Guanidine thiocyanate appears to cause an encephalopathic type presentation with discordant and/or error chloride readings and ionised hypocalcaemia. Dialysis could be considered in the management of its toxicity.

Keywords: Guanidine; Thiocyanate; Dialysis; Hypocalcaemia

Introduction

Guanidine thiocyanate is used commercially as a disinfectant and a general protein denaturant but its more common use is in the extraction of DNA and RNA in molecular biology. There are no reports of guanidine thiocyanate toxicity from oral ingestion. Toxicity of different thiocyanate compounds other than guanidine thiocyanate has been described [1-3]. Potassium thiocyanate was used over 50 years ago for the treatment of hypertension and its toxicity appears to cause a neurological disorder consisting of generalized weakness, delirium and a decrease level of consciousness. Reports of thiocyanate toxicity from nitroprusside use for hypertension in the setting of renal impairment/failure have also been reported as thiocyanate is renally cleared [2,3]. In a fatal deliberate ingestion of a herbicide which contained ammonium thiocyanate and aminotriazole, a 54 year old man presented with coma and cardiovascular collapse although the relative contributions of the two herbicides to the clinical toxicity is unknown [4].

Here we report the toxicity of a case of deliberate guanidine thiocyanate ingestion with serial levels and its treatment, including dialysis.

Case Report

A previously well 52-year-old male biochemist presented to a small urban non university hospital with a history of crampy abdominal pain, after giving a history of drinking bottled water the day before that he reported as tasting unusual. His initial vital signs were normal. However, whilst undergoing investigation of his abdominal pain, he became confused and agitated with a Glasgow Coma Score of 13 (eyes 4, verbal 4, motor 5). This required sedation, intubation, ventilation and subsequent transfer to a tertiary hospital intensive care unit for ongoing care. His provisional diagnosis prior to transfer was encephalitis. His observations were normal and the rest of his physical examination prior to intubation and ventilation was unremarkable. A computed tomography (CT) scan of his brain and abdomen were also normal. On an extended (includes electrolytes) bedside arterial blood gas (ABG) analyser he had an unmeasurable chloride (error reading), carboxyhaemoglobin of 11% (reference range [RR] <1.5% non-smokers), a low ionized calcium of 0.59 mmol/L (RR 1.15-1.32 mmol/L) with a normal pH of 7.36 (RR 7.35-7.45). His (laboratory) biochemistry showed a serum sodium of 140 mmol/L (RR 135-145), bicarbonate of 28 mmol/L (RR 22-32), chloride of 105 mmol/L (RR 100-110), anion gap of 7 (RR 4-13) with a normal serum total calcium of 2.18 mmol/L (RR 2.15-2.55) and an albumin of 40 g/L (RR 35-50). The remainder of his biochemistry including renal function, serum osmolality and osmolar gap were normal as were his haematological

investigations. A urine drug screen for amphetamines, marijuana, methadone, cocaine, opiates and benzodiazepines was also negative. His electrocardiogram had a heart rate of 60, a slightly prolonged QRS of 104 msec and a normal QT of 326 msec. He was managed initially with 70 mL of 6.8% calcium chloride (47.6 mmoles) given intravenously over 20 h, which increased his ionized calcium from 0.6 to 1.16 mmol/L in addition to supportive care. Based on the history of symptoms following the bottled water ingestion, an analysis of the water was undertaken, the details of which have been published elsewhere [5]. In brief the error in chloride reading on different laboratory chemistry analyzers suggested interference from a cross reacting analyte. Thiocyanate was considered along with the other causes and this was confirmed with a bottle water thiocyanate concentration of 1485 mg/L and a serum thiocyanate concentration on admission of 538 mg/L (RR 0.1-4.0 mg/L in non-smokers, 5-20 mg/L in smokers). Despite normal renal function, continuous veno-venous haemodiafiltration ([CVVHDF] blood flow rate 200 mL/min, dialysate 2 L/hour, filtrate 2 L/hour) was commenced based on this very high level and previously reported long half-life in patients with normal renal function of 2.7 days [6]. Fourteen serum concentrations were available (Figure 1).

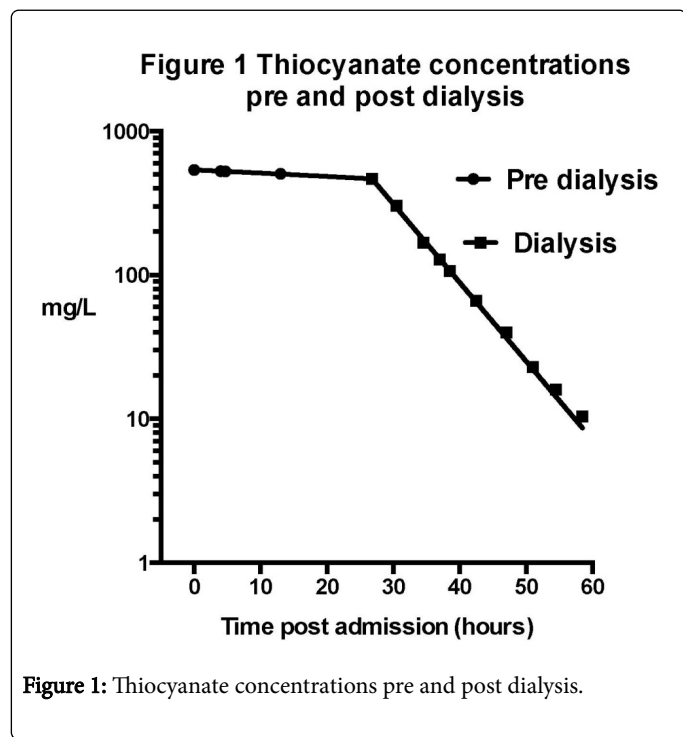


Figure 1: Thiocyanate concentrations pre and post dialysis.

Five pre dialysis serum concentrations demonstrated zero-order elimination kinetics (linear regression $r^2=0.99$ $p<0.0001$). Nine serum concentrations during dialysis demonstrated first-order kinetics with an elimination half-life of 5.4 hours (one phase decay). Dialysis continued for 35 h at which stage the thiocyanate level was 10.4 mg/L. His admission was complicated by a slow neurological recovery as well as pneumonia, however he was discharged well on day 12. Prior to discharge he admitted to the deliberate addition prior to presentation, of an unspecified amount of guanidine thiocyanate to the bottled water as a suicide attempt.

Discussion

We report a case of guanidine thiocyanate toxicity causing significant neurological toxicity, hypocalcaemia (ionized) and discordant and/or error chloride readings. There was a significant change in the clearance of thiocyanate with the commencement of dialysis, which demonstrates a possible role in the management of its toxicity.

Guanidine can enhance the release of acetylcholine by inhibiting voltage-gated potassium channels and has been used in the past for the treatment of neuromuscular disease [7], however there are no reports of its toxicity in overdose. In our patient, there were no clear symptoms or signs of acetylcholine toxicity suggesting that the toxicity seen was likely due to the thiocyanate.

More recent reports [2,3] of clinical thiocyanate toxicity are in the context of prolonged and/or high dose use of sodium nitroprusside often in association with renal impairment/failure. Cyanide is a product of nitroprusside metabolism, which is then metabolized to thiocyanate. Differentiating the relative contribution of the cyanide and thiocyanate to the toxicity described in these reports is difficult. Older reports [1,8-11] of thiocyanate toxicity from over 60 years ago when it was used as an antihypertensive agent are very similar to our patient suggesting that thiocyanate was the predominate substance involved in the toxicity seen in our patient.

Thiocyanate has some of the properties thought to be important for its suitability for dialysis. It has a small molecular weight (97 g/mol) and a low volume of distribution (0.25 L/kg) [6]. It is renally cleared and its endogenous clearance is long with a half-life of 2.7 days in healthy subjects and 9 days in renal insufficiency [6]. One previous case report details the effect of dialysis on thiocyanate clearance [4]. CVVHDF (prescription not reported) was instituted in a fatal case of ammonium thiocyanate and aminotriazole herbicide ingestion that had a thiocyanate level of 750 mg/L. Clearance prior to CVVHDF was unable to be calculated but a half-life of 10.9 h during dialysis is inferred from the reported levels. This is similar to our reported half-life of 5.4 h. The clinical impact of drug clearance and its relationship to patient recovery in our patient is not known. Despite the significant effect of dialysis on the thiocyanate levels, the patient's neurological recovery took much longer, although the clinical course was complicated by ventilator associated pneumonia.

The low ionized calcium seen in our patient has not been previously reported. The mechanism for this finding is not clear but one possible reason is that the thiocyanate being an anion was chelating calcium resulting in low ionised calcium. Contribution of the hypocalcaemia (ionized) to the overall clinical presentation is unclear. It is the ionized calcium that is physiologically active. Hypocalcaemia results in neurological and neuromuscular symptoms, which include fatigue, irritability and uncontrolled movements including seizures as well as hyperreflexia and tetany. Cardiovascular effects include a prolonged QT interval. Therefore a contribution from the low ionized calcium cannot be rule out.

The specific details of the chloride error measurement by thiocyanate interference and the elevated carboxyhaemoglobin have been discussed elsewhere [5]. This interference by thiocyanate can also result in discordant chloride measurement as well as chloride error. This was seen in the forementioned case of ammonium thiocyanate and aminotriazole herbicide ingestion where hyperchloremia of 141 mmol/L with a reverse anion gap of minus 19 was reported [4].

This is the first report of guanidine thiocyanate toxicity. Guanidine thiocyanate appears to cause neurological impairment suggestive of an encephalopathy. Ionised hypocalcaemia has not previously been reported and possibly contributes to the toxicity seen. Discordant or error readings in chloride measurement are consistent with thiocyanate interference. The clearance of thiocyanate with dialysis is significantly improved in comparison to innate clearance and although it is unproven that it alters the clinical outcome, it could be considered in cases of severe thiocyanate toxicity.

References

1. Russell WO, Stahl WC (1942) Fatal poisoning from potassium thiocyanate treatment of hypertension. *JAMA* 119: 1171-1181.
2. Nessim SJ, Richardson RMA (2006) Dialysis for thiocyanate intoxication: A case report and review of the literature. *ASAIO Journal* 52: 479-481.
3. Pahl MV, VAziri ND (1982) In-vivo and in-vitro hemodialysis studies of thiocyanate. *J Toxicol Clin Toxicol* 19: 965-974.
4. Legras A, Skrobala D, Furet Y, Kintz P, Forveille E, et al. (1996) Herbicide: Fatal ammonium thiocyanate and aminotriazole poisoning. *J Toxicol Clin Toxicol* 34: 441-446.
5. Dimeski G, Kruger P, Walsham J (2015) Unmeasurably high chloride: a surrogate marker of thiocyanate poisoning identification. *Clin Chem Lab Med* 53: e151-152.
6. Schulz V (1984) Clinical pharmacokinetics of nitroprusside, cyanide, thiosulphate and thiocyanate. *Clinical Pharmacokinetics* 9: 239-251.
7. Kalia J, Swartz KJ (2011) Elucidating the molecular basis of action of a classic drug: guanidine compounds as inhibitors of voltage-gated potassium channels. *Molecular Pharmacology* 80: 1085-1095.
8. Garvin CF (1939) The fatal toxic manifestations of the thiocyanates. *JAMA* 112: 1125-1127.
9. Gorman WF, Messinger E, Herman M (1949) Toxicity of thiocyanates used in treatment of hypertension. *Ann Intern Med* 30: 1054-1059.
10. Solomon J, Greenblatt M, Coon GP (1943) Toxic psychosis and death associated with potassium thiocyanate therapy. *N Engl J Med* 229: 241-243.
11. Waid MH, Lindberg HA, Barker MH (1939) The toxic manifestations of the thiocyanates. *JAMA* 112: 1120-1124.