

Hyponatremia-Finding the Cause

Farhan A*, Tanveer T, Mumtaz U, Raza MA and Shoaib M

Department of General Medicine, Pakistan Institute of Medical Sciences, Punjab, Pakistan

*Corresponding author: Ahmed Farhan, FCPS, Department of General Medicine, Pakistan Institute of Medical Sciences, Punjab, Islamabad, Pakistan, Tel: +923329853522; E-mail: lewal992@gmail.com

Received date: October 05, 2016; Accepted date: October 25, 2016; Published date: October 27, 2016

Copyright: © 2016 Farhan A, et al. This is an open-access article distributed under the terms of the Creative Commons Attribution License, which permits unrestricted use, distribution, and reproduction in any medium, provided the original author and source are credited.

Abstract

Hyponatremia is a very common finding in elderly and hospitalized patients. Finding its cause is where one has to scratch his head. This case emphasizes how a common occurrence (hyponatremia) can be a manifestation of an underlying rare diagnosis- hypopituitarism.

This case is about a seventy years old female presenting with altered state of mentation. Her systemic examination was completely normal except for generalized hypertonemia and a Glasgow coma scale of seven. Laboratory investigations revealed hyponatremia with normal chemistry and normal blood complete picture. CT brain and cerebrospinal fluid analysis was also unremarkable. When she was found resistant to treatment (free water restriction and hypertonic saline), she was further investigated and finally diagnosed as a case of hypopituitarism.

Keywords: Hyponatremia; Hypopituitarism; SIADH (Syndrome of inappropriate diuretic hormone)

Introduction

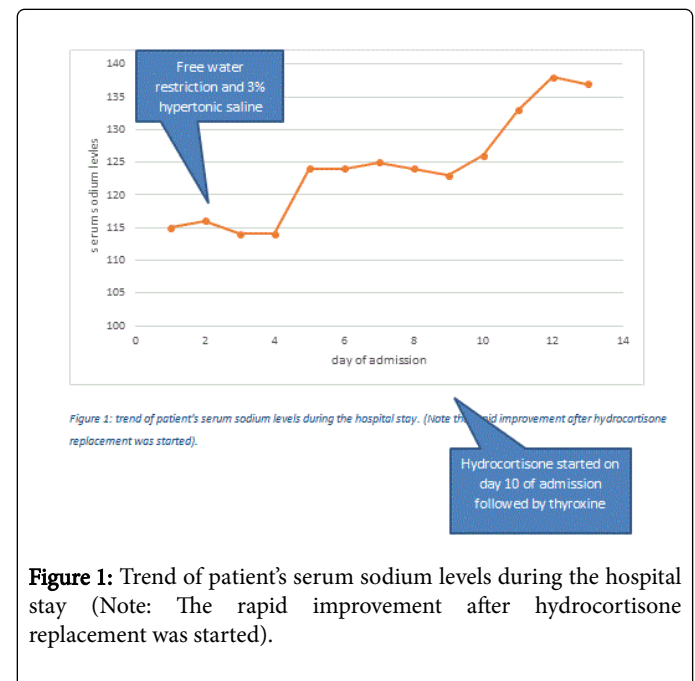
Hyponatremia is a very common presentation in the medical wards especially in the elderly hospitalized patients (upto 60% of patients with a serum sodium levels of <135 mEq/L) [1] and has been associated with increase in mortality rates [2]. Finding the cause of hyponatremia can be extremely difficult at times. Patients with hyponatremia can present with a variety of symptoms ranging from nonspecific lethargy, fatigue, nausea and cognitive impairment to life threatening seizures and coma.

The diagnosis of hypopituitarism is in itself a difficult diagnosis especially in the elderly and when the presentation is only with hyponatremia, the diagnosis becomes even more difficult. This case highlights how hyponatremia lead to the diagnosis of panhypopituitarism – a common electrolyte imbalance leading to a rare diagnosis.

Case report

Seventy years old female was admitted in our medical ward with history of progressive drowsiness over the past two weeks. There was no history of fever, fits or focal weakness. She was perfectly alright two weeks back and had no history of any kind of medication use in the recent past. Her systemic review was also unremarkable. On examination she was drowsy with a GCS of 7/15. General physical examination was normal except for mild pedal edema. There were no signs of meningeal irritation, pupils were equal and reactive to light. She had generalized hypertonemia, but she was moving all four limbs and plantars were bilaterally downgoing. Her systemic examination was unremarkable. Her initial investigations revealed normal chemistry and complete blood picture except for severe hyponatremia and raised creatine phosphokinase levels. Her CT brain and CSF routine examination was completely normal. Serum osmolality was low (240

mmol/l). Her urinary osmolality and urinary sodium was 278.5 mmol/l and 37.1 mEq/l respectively. Initial impression of Syndrome of Inappropriate Diuretic Hormone (SIADH) was made because patient had euvolemic hypo-osmolar hyponatremia with high urine osmolality and high urinary sodium levels. Since the patient was euvolemic and did not have any symptoms or signs suggestive of hypoadrenalism or hypothyroidism so only serum TSH was sent as a screening test and patient was started on water restriction and hypertonic saline. Her sodium levels remained around 123 meq/L (Figure 1) and drowsy state did not improve.



Serum TSH came out to be normal (0.76 uIU/ml, Normal: 0.4-4.9 uIU/ml). When patient was not responding to treatment, her complete

thyroid profile was requested. S.TSH was low normal and Free T3 and Free T4 were low (S.TSH: 1.1 uIU/ml, Normal: 0.4-4.5 uIU/ml, FT3: 1.5 pg/ml, Normal: 1.7-3.7 pg/ml; FT4: 0.5 ng/dl, Normal: 0.7-1.5 ng/dl). Impression of central hypothyroidism was made and 08:00 Am morning cortisol was ordered which came out to be low {3.4 µg/dl (6.2-19.4)}. Subsequent hormones (LH and FSH) were also low {LH: 0.403 (7.7-58.5 mIU/ml), FSH: 1.19 (25.8-134.8 mIU/ml)}. MRI brain was requested and the diagnosis of empty sella was finally made (Figure 2). With appropriate hormonal replacement, her serum sodium improved to 138 meq/L and GCS improved to 15/15. She was discharged on oral prednisolone and thyroxine.

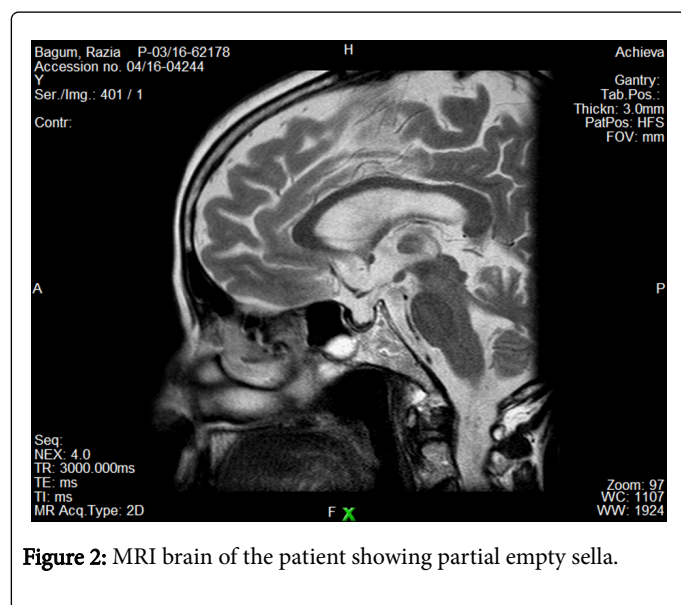


Figure 2: MRI brain of the patient showing partial empty sella.

Discussion

Hyponatremia is a common electrolyte abnormality and an independent risk factor for mortality in hospitalized patients [2]. Despite its strong association with mortality and cognitive decline, hyponatremia is often neglected by clinicians [3]. Hyponatremia can result from free water retention in response to sodium losses from the body as in gastroenteritis, antidiuretic hormone in response to ineffective circulatory volume as in cirrhosis and heart failure and vasopressin activity in conditions like malignancies, infections and stress. Hyponatremia is not a diagnosis but a manifestation of an underlying disorder and therefore search for an underlying cause should be one of the major goals.

Our patient had severe hyponatremia and altered mental status and despite free water restriction and 3% hypertonic saline infusion she was not responding. The reason was that the underlying condition was not taken care of. Investigations of our patients were suggestive of SIADH. The diagnostic criteria of SIADH emphasizes the absence of any alternate cause for hyponatremia [4]. As a part of workup for SIADH her serum TSH was sent but came out to be normal. Normal TSH can be found in sick euthyroid state as well as central hypothyroidism. A low free T4 favored central hypothyroidism. Differentiating SIADH from central hypocortisolism can be very difficult as the clinical and biochemical features are the same [5]. Primary and secondary adrenal insufficiency can both present with hyponatremia. A normovolemic state, normal blood pressure, no pigmentation, and normal serum potassium all favour central

hypocortisolism. Hyponatremia can be the only finding present in both primary and secondary hypocortisolism. Lastly gonadotrophins in a postmenopausal women should be raised which were also low after which we proceeded to MRI of the brain and pituitary fossa in specific which revealed a partial empty sella.

Empty sella is the nonvisualization of pituitary gland in the fossa secondary to herniation of the suprasellar cistern. Prevalence in autopsies is reported to be as high as 6-20%. In a study by zahur et al, hypopituitarism was found in 67% and 14% of patients with total and partial empty sella respectively [6]. Empty sella is classified as partial empty sella and total empty sella on the basis of MRI. When less than 50% of the fossa is filled with cerebrospinal fluid and pituitary gland thickness is greater than 3 mm, it is partial empty sella while total empty sella is when more than 50% of the fossa is occupied by cerebrospinal fluid and pituitary thickness is less than 2 mm. In a series of patients with normovolemic hyponatremia, 20% of the patients were found to have hypopituitarism mostly due to empty sella [7].

After appropriate hormonal replacement, patient conscious level and sodium levels improved and was finally discharged.

Lessons to Learn in this Case Are

- Patient should be investigated for the underlying cause of hyponatremia and treated as hyponatremia is associated with improvement in mortality rates [8].
- A normal TSH levels should not be regarded as normal if central hypothyroidism is suspected
- Incontrast to primary adrenal insufficiency, patients with central hypocortisolism are not volume depleted, do not have hyperpigmentation, have normal potassium levels and normal blood pressure
- Patients should be investigated for hypothyroidism and hypocortisolism before labelling SIADH.

Conclusion

Hyponatremia can be the only presentation in elderly patients with hypopituitarism. Unless proper hormonal replacement is instituted, hyponatremia in these patients is usually resistant to free water restriction and hypertonic saline.

Consent

Written informed consent was obtained from the patient for publication of this Case report and any accompanying images.

References

1. Upadhyay A, Jaber BL, Madias NE (2009) Epidemiology of hyponatremia. *Semin Nephrol* 29: 227-238.
2. Liamis G, Rodenburg EM, Hofman A, Zietse R, Stricker BH, et al. (2013) Electrolyte disorders in community subjects: prevalence and risk factors. *Am J Med* 126: 256-263.
3. Hoorn EJ, Lindemans J, Zietse R (2006) Development of severe hyponatremia in hospitalized patients: treatment-related risk factors and inadequate management. *Nephrol Dial Transplant* 21: 70-76.
4. Ellison DH, Berl T (2007) Clinical practice. The syndrome of inappropriate antidiuresis. *N Engl J Med* 356: 2064-2072.
5. Chanson P (2003) Severe hyponatremia as a frequent revealing sign of hypopituitarism after 60 years of age. *Eur J Endocrinol* 149: 177-178.

-
6. Zuhur SS, Kuzu I, Ozturk FY, Uysal E, Altuntas Y (2013) Anterior pituitary hormone deficiency in subjects with total and partial primary empty sella: do all cases need endocrinological evaluation? *Turk neurosurg* 24: 374-379.
 7. Diederich S, Franzen NF, Bähr V, Oelkers W (2003) Severe hyponatremia due to hypopituitarism with adrenal insufficiency: report on 28 cases. *Eur J Endocrinol* 149: 177-178.
 8. Corona G, Giuliani C, Parenti G, Norello D, Verbalis JG, et al. (2013) Moderate Hyponatremia Is Associated with Increased Risk of Mortality: Evidence from a Meta-Analysis. *PLoS ONE* 8: e80451.