

High Altitude Retinal Hemorrhage

Maria Agustina Borrone¹ and Rodrigo Martin Torres^{2*}

¹Diagnóstico Ocular, Ciudad Autónoma de Buenos Aires, Argentina

²Torres Rodrigo Martín, Centro de Ojos Dr. Lódolo, Paraná, Entre Ríos, Argentina

*Corresponding author: Rodrigo Martin Torres, Centro de Ojos Dr. Lódolo, Paraná, Entre Ríos, Argentina, Tel: 543434683588; Fax: 3434683588; E-mail: romator7@gmail.com

Received date: December 16, 2016; Accepted date: February 1, 2017; Published date: February 3, 2017

Copyright: ©2017 Borrone MA, et al. This is an open-access article distributed under the terms of the Creative Commons Attribution License, which permits unrestricted use, distribution, and reproduction in any medium, provided the original author and source are credited.

Abstract

Objective: sudden atmospheric pressure changes can generate vascular modifications in the retina. We present a clinical case of retinal hemorrhage related to high altitude and propose to revise its pathophysiology.

Methods: A case presentation with review of literature.

Results: 36 year old Male patient came to our institute with sudden diminished vision in the right eye associated with loss of consciousness while climbing a mountain. In the ophthalmological examination, we could appreciate in the right eye a macular hemorrhage and in both eyes few diffuse hemorrhages in mild periphery. The patient lost follow-up and return after 1 year for a check-up. He had spontaneous resolution of all hemorrhages.

Conclusion: the acute mountain sickness affects mostly not climatized people. Changes in atmospheric pressure generate reduction of the partial pressure of oxygen in the blood. This can lead to vascular changes in the retina. This change may not appear if there is a proper climatization while climbing a mountain. The presence of high altitude retinopathy alerts about cerebral oedema related to high altitude.

Purpose

First retinal hemorrhages related with high altitude were detected in 1968 in Mount Logan in Canada [1]. Their relation with high altitude, were first described in 1970 by Frayser et al. and first optic disc changes associated with high altitude were described by Singh et al. [1,2].

The mountain sickness syndrome includes “acute mountain syndrome” (AMS), “high altitude retinal hemorrhage” (HARH) and the severe forms “high-altitude pulmonary oedema” (HAPE) and cerebral oedema (HACE) [2]. These diseases are different facets of failure to acclimatize at high altitude [3,4]. These conditions are associated with the rapid ascent to above 3000 m.

Till date, many lesions in the eyes have been detected in relation with high altitude such as corneal edema, tear film alterations, pupil defects, changes in the IOP [5,6] but there’s no clear relation between them and the severe forms of mountain sickness [7]. The purpose of this article is to present a case of spontaneous resolution of this disease.

Case Report

A 36-year-old man came to the institute in January 2013 with chief complaints of diminished vision in the right eye after an episode of loss of consciousness while climbing a mountain 10 days ago, (no data is

recorded about meters climbed). He refers he was taken to emergency and recovery after 5 days in the hospital. He refers he didn’t need to be taken to intensive care unit. By the time he arrived to the hospital, blood pressure and vital signs were within normal limits and brain and pulmonary disease were ruled out there. He noted while being at the hospital that he saw a red spot in the right eye and after returning to his hometown he decided to consult with an ophthalmologist and control clinically with a physician as being told.

On examination, he presented an UCVA of 20/100 the right eye and 20/20 in the left eye. IOP was within normal limits. External examination was normal. In the right eye fundus examination, we found a macular hemorrhage, CDR (Cup Disc Ratio) 0.2:1, two small diffuse paramacular hemorrhages were also found and the retina was attached, the exam in the left eye showed a few diffuse hemorrhages in both vascular arcades. The lesions were recorded by an Optical Coherence Tomography (OCT) image of both eyes (Figure 1).

The patient lost follow up and return to the institute a year later in January 2014. At that moment his UCVA was 20/20 in both eyes. The rest of the exam was within normal limits including IOP. The posterior segment OCT showed a complete resolution of the hemorrhages in both eyes and no evidence of any scar or intraretinal lesion were seen as shown in Figure 2.

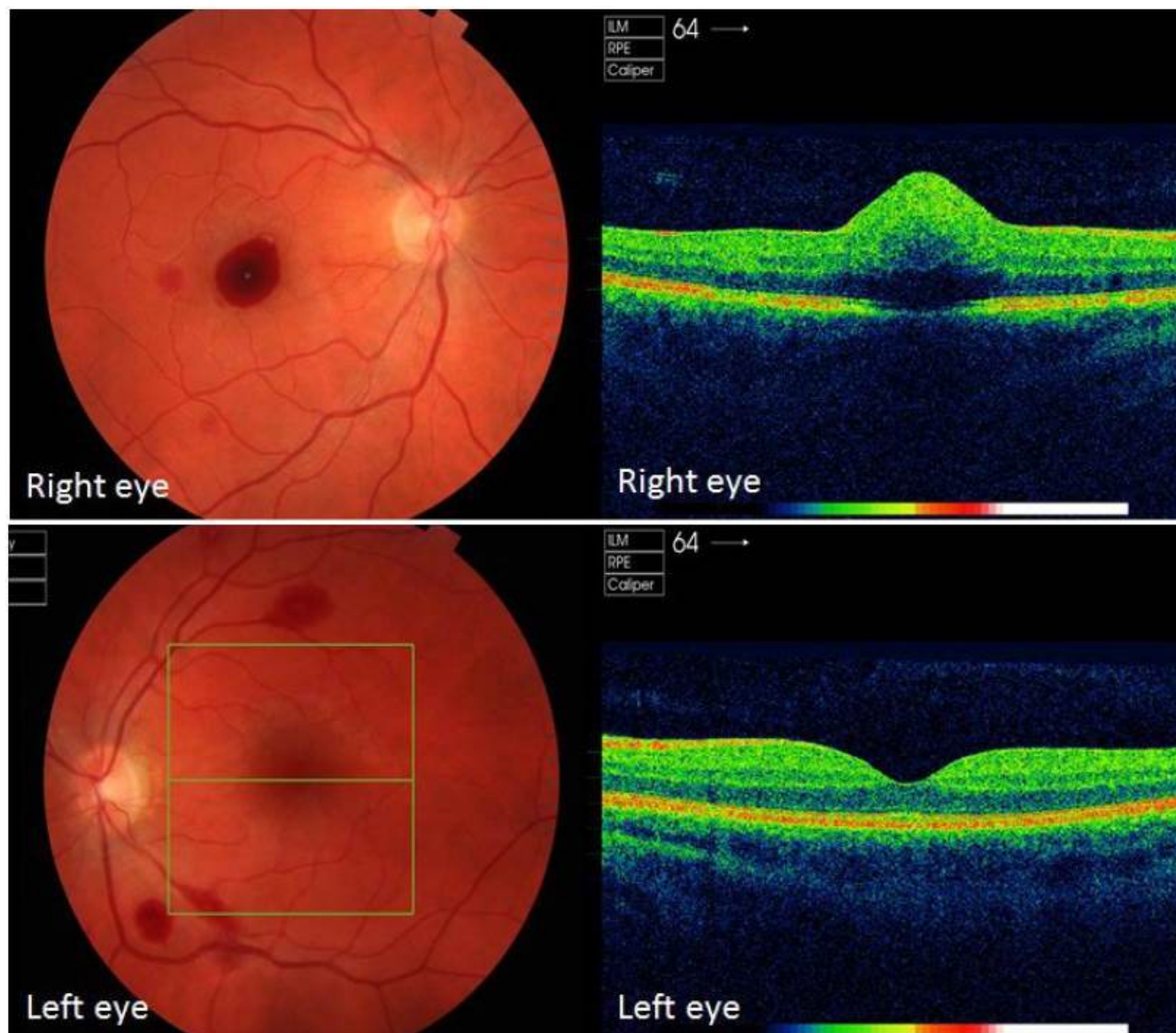


Figure 1: Lesions in right and left eye recorded by optical coherence tomography.

Conclusions

While climbing a mountain and the increase of the altitude, there is a reduction in the atmospheric pressure leading to a reduction in the pressure of O₂ (Atmosphere O₂ pressure=Atmospheric pressure × % O₂ in the atmosphere). This lead to a reduction in the blood partial pressure of oxygen causing hypoxia if there is no time for acclimatization. This hypoxia generates a reduction in the levels of oxygen that go to the different tissues and cells [8]. To compensate this, the body reacts with tachycardia, hyperventilation, hypocapnia and metabolic. It is extremely important to know the rate of ascent suggested for each pick. A few reports mention that over 3000 mts only 300 mts should be climbed per day [9,10].

Changes on the posterior pole are produced by physiological changes and pathological ones. The physiological changes are due to acclimatization, and are mainly vasodilation and tortuosity. The pathological changes are due to hypoxia. This is thought to be the producer of tissue edema causing optic disc edema as the swollen of the disc in HACE is not related to elevation of the intracranial pressure (ICP). Hypoxia may be the cause of vessel filtration in the periphery of the retina [11]. Also this may be the causative agent of damage of the wall cells of the vessels leading to the production of hemorrhages [11]. Daniel Barthelmes et al. mentioned that higher hematocrit, may contribute to the damage of the endothelial cells [12].

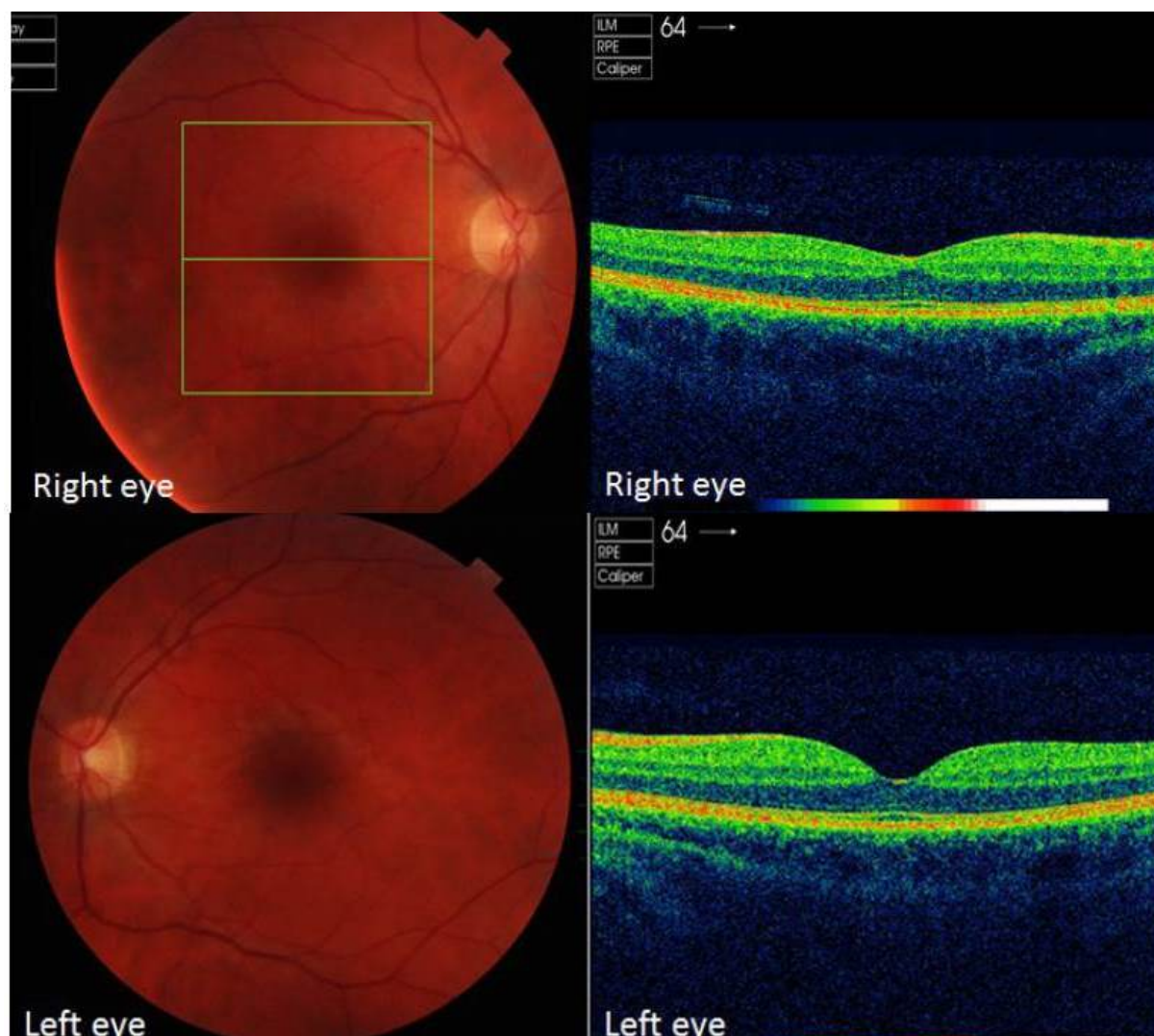


Figure 2: Posterior segment OCT showing a complete resolution of the hemorrhages in both eyes and no evidence of any scar or intraretinal lesion.

Cerebral outflow limitation capacity may cause headache and it is suggested that this could be the cause of the retinal venous diameter increase [11]. Advanced technology used to detect hemorrhages in the retina helped to show that there is no correlation between HARH and AMS or HACE [13]. It is known that optic disc swollen related to high altitude exposure may have different origin if it is not related to increased intracranial pressure [11]. Although there can be a few associations between retinal disorders and HACE, everything is questionable. As mentioned in the update by Willmann et al. the retinal vein engorgement as indicator of outflow limitation must be assessed [11].

To conclude the pathophysiology of HARH remain still obscure and even the retina and the optic nerve are closely related to the brain and cranial structures there is no clear relation between HARH and HACE or even HAPE. Prevention to avoid lesions is mandatory even though retinal lesions could resolve spontaneously. Most of the posterior pole lesions resolve spontaneously in a few days or weeks, but a few of them

can leave sequelae such as scotomas of visual field [7]. More research need to be done to rule out the relation between retinal and cerebral lesions to avoid severe and irreversible problems.

References

1. Frayser R, Houston CS, Bryan AC, Rennie ID, Gray G (1970) Retinal hemorrhage at high altitude. *N Engl J Med* 282: 1183-1184.
2. Singh I, Khanna PK, Srivastava MC, Lal M, Roy SB, et al. (1969) Acute mountain sickness. *N Engl J Med* 280: 175-184.
3. Hussey HH (1975) Editorial: High altitude retinal haemorrhage. *JAMA* 23: 1271.
4. Clarke C, Duff J (1976) Mountain sickness, retinal haemorrhages, and acclimatisation on Mount Everest in 1975. *Br Med J* 2: 495-497.
5. Karakucuk S, Mujdeci M, Baskol G, Arda H, Gumus, K et al. (2012) Changes in central corneal thickness, intraocular pressure, and oxidation/antioxidation parameters at high altitude. *Aviat Space Environ Med* 83: 1044-1048.

-
6. Willmann G, Schatz A, Fischer MD, Schommer K, Zrenner E, et al. (2014) Exposure to high altitude alters tear film osmolarity and breakup time. *High Alt Med Biol* 15: 203-207.
 7. Wiedman M (1975) High altitude retinal hemorrhage. *Arch Ophthalmol* 93: 401-403.
 8. Imray C, Wright A, Subudhi A, Roach R (2010) Acute mountain sickness: pathophysiology, prevention, and treatment. *Prog Cardiovasc Dis* 52: 467-484.
 9. Peacock AJ (1998) ABC of oxygen: oxygen at high altitude. *BMJ* 317: 1063-1066.
 10. Davis PR, Pattinson KT, Mason NP, Richards P, Hillebrandt D. (2005) High altitude illness. *J R Army Med Corps* 151: 243-9.
 11. Willmann G, Gekeler F, Schommer K, Bärtsch P (2014) Update on high altitude cerebral edema including recent work on the eye. *High Alt Med Biol* 15: 112-122.
 12. Barthelmes D, Bosch MM, Merz TM, Petrig BL, Truffer F, et al. (2011) Delayed appearance of high altitude retinal hemorrhages. *PLoS One* 6: e11532.
 13. Bosch MM, Barthelmes D, Landau K (2012) High altitude retinal hemorrhages--an update. *High Alt Med Biol* 13: 240-244.