



Pedal Melanotic Schwannoma: A Case Report

Glenn Woodley*, Mark Micciche and Dana Klush

Geisinger Community Medical Center, Scranton, USA

Abstract

Background: Melanotic or melanocytic schwannoma is a rare variant of a schwannoma. It is composed of melanin-producing cells with the ultra-structural features of Schwann cells along with the cytoplasmic deposition of melanin. The occurrence of a melanotic schwannoma is particularly rare in the foot. Regardless of anatomic location, they are considered to be benign soft tissue masses.

Case description: A 78 year old Caucasian female presented to a physician's office with complaints of onychomycosis. Incidentally, it was noted that the patient had large a mass on the plantar aspect of her right foot. She denied any complaints regarding the mass. The mass had been present for approximately one year and was slowly increasing in size. An MRI revealed a heterogeneous macrolobulated mass measuring 3.0 × 8.3 × 5.3 cm and could not rule out malignancy. A surgical biopsy was then performed.

Conclusion: Melanotic schwannomas have the ability to mirror malignancy, both on physical exam and on advanced imaging modalities. A biopsy procedure provides a definitive diagnosis and contributes to the definitive treatment plan.

Introduction

Schwannomas are solitary, slow-growing, and encapsulated benign soft tissue neoplasms composed of differentiated neoplastic Schwann cells [1]. These soft tissue tumors are thought to arise sporadically [2]. A melanotic or melanocytic, schwannoma is a rare variant of a schwannoma that typically involves spinal nerve roots [1,2]. However, it can present at other anatomic locations. Melanotic schwannomas share particular ultra-structural features of Schwann cells. These features include a well-developed basal lamina, plentiful pinocytic vesicles and interdigitating cytoplasmic processes [3]. The most common location of a melanotic schwannomas is either the posterior spinal nerve roots or the paraspinal sympathetic chain [1,4]. Please see Table 1 for a comparison of a schwannoma and a melanotic schwannoma.

This rare pigmented nerve sheath tumor was first described in 1932 by Millar [4]. Macroscopically, it appears brown or black due to the presence of pigmented melanin [4]. Microscopically, it shows characteristics of uncommon variants of nerve sheath tumors with melanocytic differentiation [4]. It is believed that melanotic schwannomas have the ability to synthesize melanin potentially because both Schwann cells and melanocytes are derived from migrating neural crest cells [1]. Following resection of this tumor, local recurrence is rare [5]. Complete resection of this tumor is recommended to prevent recurrence.

Case Report

A 78 year old Caucasian female presented to a physician's office with a complaint of onychomycosis. Incidentally, she was examined

and found to have a mass on the plantar aspect of her right foot. She denied pain or other complaints regarding the mass. The mass had been present for approximately one year. It did not prompt the patient to seek medical attention. The mass was minimally painful, and did not inhibit her activities of daily living. The mass had been very slowly increasing in size. Noninvasive imaging of this mass included plain radiographs, followed by Magnetic Resonance Imaging. The x-rays showed an increase in soft tissue density and volume at the plantar aspect of the right forefoot and midfoot with no bone involvement (Figures 1-3).

Magnetic Resonance Imaging revealed a heterogeneous macrolobulated mass measuring 3.0 × 8.3 × 5.3 cm. Malignancy was not ruled out (Figures 4-6). Neither osseous changes nor periosteal reactions were noted on the MRI.

A surgical biopsy procedure was then performed. During this procedure, a fibrous, brown-colored, smooth mass was identified. When a portion of this mass was excised, it exuded a moderate amount of brown, granular discharge. Two portions of the mass, from two separate locations, and its discharge, were sent as specimens for pathologic analysis. The pathology results revealed the mass to be a benign melanotic schwannoma.

During the post-operative course, the patient developed an infection at the surgical site. This infection was treated with incision, drainage and debridement. The patient was treated with antibiotics orally and the mass was subsequently removed in total during a follow-up procedure. Fluid from the mass removal was sent as specimen and ultimately revealed no malignant cells.

The patient then developed a non-healing wound at the surgical

	Schwannoma	Melanotic Schwannoma
Classification	Benign (Majority)	Benign
Common Location	Peripheral Nervous System	Nerve Roots and Paraspinal Chain
Pedal Occurrence	Rare	Exceedingly Rare
Melanin	None	Cytoplasmic
Cytoplasmic Processes	Interdigitating	Interdigitating
Basal Lamina	Well Developed	Well Developed
Pinocytic Vesicles	Plentiful	Plentiful

Table 1: Comparison of schwannoma to melanotic schwannoma.

*Corresponding author: Glenn Woodley, Geisinger Community Medical Center, Scranton, USA, Tel: (570) 703-8000; E-mail: gwoodley@geisinger.edu

Received June 28, 2017; Accepted August 07, 2017; Published August 15, 2017

Citation: Woodley G, Micciche M, Klush D (2017) Pedal Melanotic Schwannoma: A Case Report. J Tumor Res 3: 126.

Copyright: © 2017 Woodley G, et al. This is an open-access article distributed under the terms of the Creative Commons Attribution License, which permits unrestricted use, distribution, and reproduction in any medium, provided the original author and source are credited.

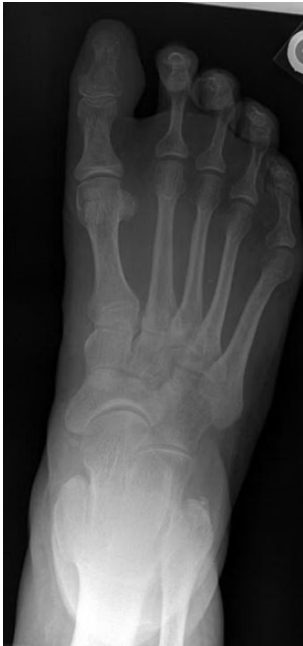

Figure 1: X-ray DP view right foot.

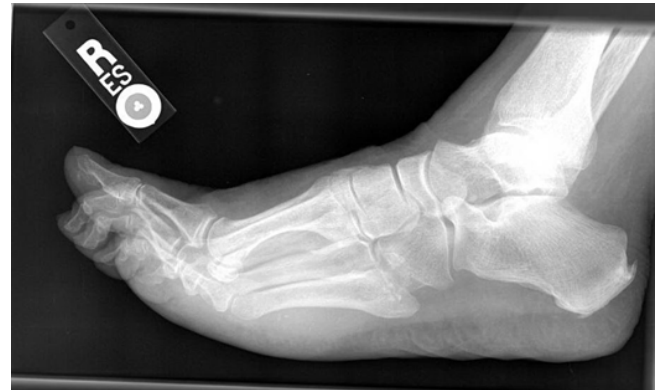

Figure 3: X-ray lateral view right foot.

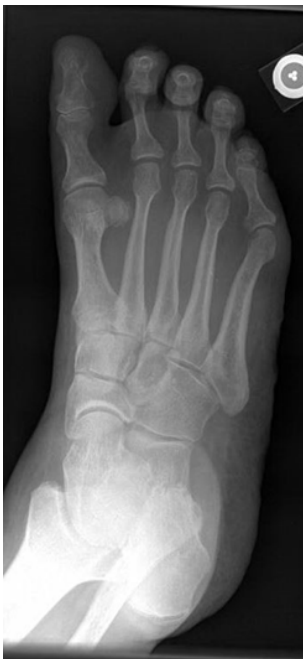

Figure 2: X-ray oblique view right foot.

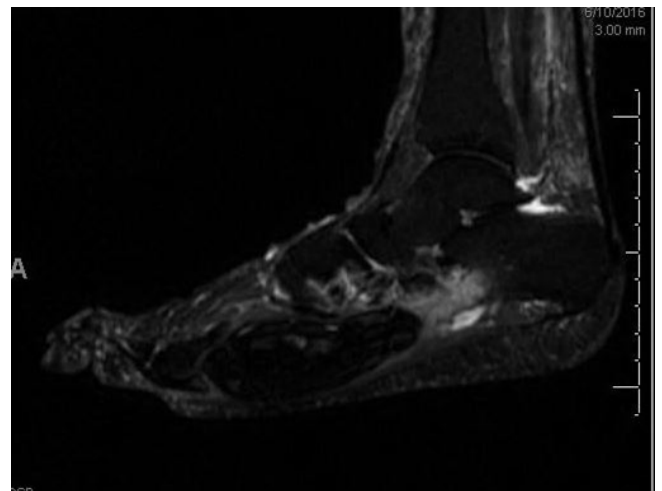


Figure 4: MRI sagittal view right foot.

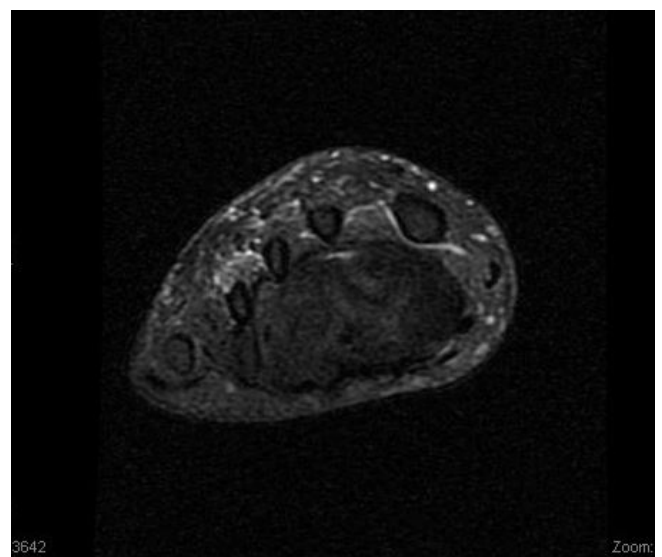


Figure 5: MRI coronal view right foot.

site. An additional surgical procedure, wound excision and rotational flap closure and local wound care healed the wound within four months of the initial surgical procedure. At her subsequent appointments, the patient did not report any issues or additional complications following the removal of the pedal melanotic schwannoma.

Discussion

Melanotic schwannomas are a distinguished entity from

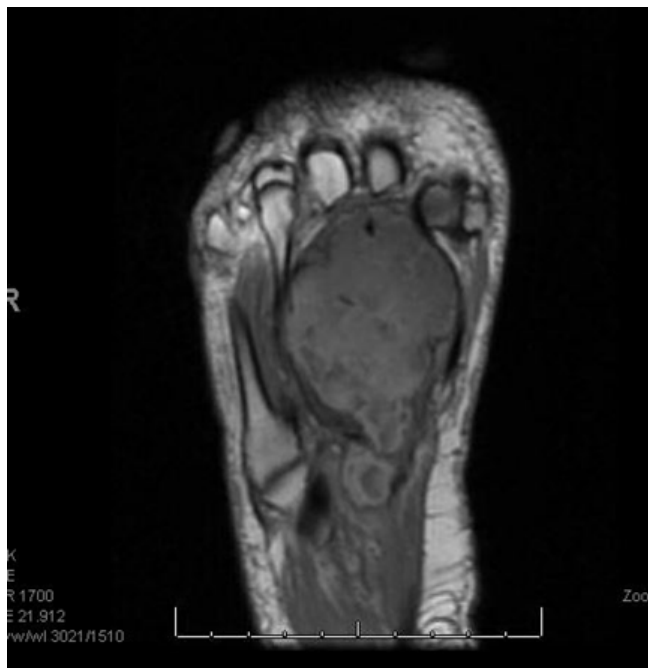

Figure 6: MRI axial view right foot.

conventional schwannomas. The gray-brown pigment occasionally seen in conventional schwannoma represents lipofuscin opposed to true melanin [1]. Although nerve roots and the paraspinal sympathetic chain are the most frequent locations of melanotic schwannomas, they may present at various anatomic locations [1,2]. However, their presence in the foot is extremely rare with very few cases published in the literature. The appearance of this tumor on clinical exam and

on surgical evaluation may mirror a malignant lesion. Wide excision of a melanotic schwannoma is recommended to prevent growth and reoccurrence of the lesion.

Conclusion

Melanotic schwannoma is a benign rare variant of a conventional schwannoma that has the ultrastructural features of Schwann cells. Additionally, it is composed of melanin-producing cells. Comparable to a schwannoma, it is a slow-growing space occupying lesion. The presence of this tumor is exceedingly rare in the foot. An x-ray of the mass is a first line imaging study. It can reveal if there is any osseous involvement associated with the mass. An advanced imaging study, such as an MRI, is needed to reveal the extent and characteristics of the mass. These characteristics aid with diagnosis of the lesion. However, imaging studies performed on a melanotic schwannoma may be inconclusive and can mirror malignant masses. The ideal diagnosis for this tumor includes biopsy, if advanced imaging studies are inconclusive. If advanced imaging studies are conclusive or after the results of the biopsy return, complete wide excision of the tumor is recommended for treatment.

References

1. Er U, Kazanci A, Eyriparmak T, Yigitkanli K, Senveli E (2007) Melanotic schwannoma. J Neurosci.
2. Khoo M, Pressney I, Hargunani R, Tirabosco R (2015) Melanotic schwannoma: An 11 year case series. Skeletal Radiol.
3. Webb JN (1982) The ultrastructure of a melanotic schwannoma of the skin. J Pathol 137: 25-36.
4. Kaehler K, Russo P, Katenkamp D, Kreuzsch T (2008) Melanocytic schwannoma of the cutaneous and subcutaneous tissues: Three cases and a review of the literature. Melanoma Res 18.
5. Zhang HY, Yang GH, Chen HJ, Wei B, Ke Q (2005) Clinicopathological, immunohistochemical and ultrastructural study of 13 cases of melanotic schwannoma. Chin Med J 118: 1451-1461.