

Brain Activations in fMRI induced by Color Stimulation in Patients with Normotensive Glaucoma

Jan Lešták^{1,2,3*}, Jaroslav Tintěra¹, Lukáš Ettler¹, Zuzana Svatá¹ and Pavel Rozsival³

¹JL Clinic, V Hůrkách 1296/10, Prague, Czech Republic

²Faculty of Biomedical Engineering, Czech Technical University, Prague, Czech Republic

³Faculty of Medicine in Hradec Králové, Charles University, Prague, Czech Republic

Abstract

Objective: The aim was to find, whether the activations in fMRI induced by black-white and yellow-blue stimulation in patients with normotensive glaucoma will be similar to those in patients with hypertensive glaucoma.

Methods and subjects: The authors examined eight patients with various stages of normotensive glaucoma using functional magnetic resonance imaging (fMRI). The group was compared to a group of eight healthy persons. Measurements were performed on the Philips Achieva 3T TX MR system using the BOLD method. Optical stimulation was provided by black-white and yellow-blue checkered patterns alternated with their negatives with a frequency of 2 Hz. Each measurement consisted of a sequence with five 30-second periods of active phase and five resting periods of the same length. The obtained data were processed by SPM 8 software and general linear model (GLM). The difference in the number of activated voxels when using the black-white (BW) or yellow-blue (YB) stimulations was tested by a t-test. Statistical maps of BW>YB and BW<YB differences of patients and controls were thresholded at the uncorrected threshold of $p=0.001$ and the number of voxels statistically compared by a t-test.

Results: The mean value of the difference in the number of activated voxels when using the BW vs. YB stimulation was only 6% for the patients and 2% for the controls. Both the BW>YB and the BW<YB differences between the control group and the patients did not differ significantly: 318 voxels ($p=0.098$) and 23 voxels ($p=0.799$) respectively.

Conclusion: The authors demonstrated that in the patients with normotensive glaucoma there are no corresponding functional changes in the cerebral cortex. Similarly to healthy individuals, the authors did not find differences in activation using BW and YB stimulation. Normotensive glaucoma pathogenetically behaves in a different way compared to hypertensive glaucoma.

Keywords: Color vision; Normotensive glaucoma; Visual cortex; fMRI

Introduction

At present, there is no doubt that the major damaging factor in the hypertensive glaucoma is the intraocular pressure. The degree of damage to the retinal ganglion cells and their axons also depends on the pressure level. It is different in the normotensive glaucoma, where it is rather vascular and other components that contribute to the progression of the disease.

In relation to our previous studies about the difference between the hypertensive and normotensive glaucoma (where we proved not only a different defect in the visual pathway by means of electrophysiological tests, but the difference in the visual cortex activation in fMRI as well), we tried to find possible difference in color perception in normotensive glaucoma compared to hypertensive one [1-3].

There are not many published papers dealing with the color perception defect in normotensive glaucoma [4-7]. We are lacking studies dealing with the fMRI and color stimuli in normotensive glaucoma in literature.

Patients and Methods

The group consisted of 8 patients with the normotensive glaucoma (6 women aged 53–70 and 2 men aged 40 and 52 years).

Criteria for inclusion into the group: normal visual acuity (with eventual correction), bilateral disease, various stages of changes in ocular fields (pattern defect 1.12-12.65). Other causes of changes in ocular fields and on the optic disc were excluded.

The results were compared with a control group of eight healthy subjects (3 women aged 23–46 and 5 men aged 23–65 years).

Ophthalmologic Examinations

A comprehensive ophthalmologic examination that confirmed the diagnosis of normotensive glaucoma (ophthalmoscopy, perimetry, GDx, PERG, PVEP) was completed by the Lanthony 15-Hue desaturated color vision test and pseudoisochromatic Ishihara's test for color blindness.

Functional MRI Imaging

All the measurements of functional MR imaging (fMRI) were performed on the MR system Philips Achieva TX SERIES with a magnetic field strength of 3 Tesla. A standard 8-channel SENSE head RF coil was used for scanning. Optical stimulation for fMRI was performed with a commercially available ESys (In Vivo) stimulus system.

*Corresponding author: Jan Lestak, MD, PhD, JL Clinic, V Hurkach 1296/10, 158 00 Prague 5, Czech Republic, E-mail: lestak@seznam.cz

Received July 02, 2012; Accepted October 20, 2012; Published October 27, 2012

Citation: Lešták J, Tintěra J, Ettler L, Svatá Z, Rozsival P (2012) Brain Activations in fMRI induced by Color Stimulation in Patients with Normotensive Glaucoma. J Clin Exp Ophthalmol 3:250. doi:10.4172/2155-9570.1000250

Copyright: © 2012 Lešták J, et al. This is an open-access article distributed under the terms of the Creative Commons Attribution License, which permits unrestricted use, distribution, and reproduction in any medium, provided the original author and source are credited.

The measured volume consisted of 39 contiguous slices with thickness of 2 mm, and the size of the measured voxel (spatial resolution) was 2×2×2 mm (FOV=208×208 mm, matrix 104×104, reconstruction matrix 128×128, SENSE factor of 1.8). Two fMRI measurements were performed for each examination with different types of optical stimulation: In the active phase of the first measurement, the subjects were exposed to alternations of black-white (BW) checkerboard pattern (Figure 1a), while yellow-blue (YB) checkerboard pattern alternations were used in the second measurement (Figure 1b). This alternation was in the form of color inversion at a frequency of 2 Hz. During the resting phase, the subjects were shown a static cross hair placed in the middle of the visual field. Each measurement consisted of a sequence with five 30-second periods of active phase (10 dynamic scans) and five resting periods of the same length. Therefore, each measurement consisted of a total of 100 dynamic scans and lasted 5 minutes.

The fMRI evaluation was performed in SPM8 software. During the pre-process, the data were corrected for motion (realignment) and time shift of the slices (slice timing) followed by smoothing using Gaussian filter with FWHM of 6×6×6 mm, and finally normalized into the MNI_152 space. A general linear model with canonical HRF (hemodynamic response function) applied to the stimulation periods was used for statistical evaluation of all subjects. Individual statistical maps were thresholded at the level of p=0.05 with FWE correction and the minimum cluster size of 10 voxels. The statistical maps of BW>YB and YB>BW differences (two-sample t-test) were thresholded at the level of p=0.001, without correction, and the minimum cluster size of 10 voxels.

Group statistics were performed using the paired and unpaired t-test with an uncorrected threshold at p=0.005 and the minimum number of uninterrupted voxels of 60 (8 subjects in each group).

Results

The entire numbers of activated voxels in both hemispheres are shown for all subjects in table 1. Values in columns BW and YB are calculated from functional maps with threshold of p=0.05 with FWE correction, and values in columns BW>BY and YB>BW are calculated from differential maps using uncorrected p=0.001. Average number of activated voxels during BW stimulation was 7 626 (std=2 948) in NTG patients and 7 462 (std=4 515) in the control group; the extent of activation did not differ statistically. When activated by YB checkerboard, the activation range decreased on average to 5 650 (std=2 154) in NTG and to 6 353 (std=2 148) in healthy controls. An average difference between BW and YB in the patient group was 6% and in the control group 2%. However, numbers of voxels in the differential maps did not differ significantly between both the groups—either for BW>YB (318 voxels, p=0.098) nor for YB>BW (23 voxels, p=0.799) (Table 1 and Figure 2).

The examination of color perception by means of Lanthony’s 15 Hue test did not show the defect of color perception in any patient with normotensive glaucoma. During the test with Ishihara’s pseudoisochromatic plates for color blindness we found the fault in resolution of number 74 in patient’s No. 3 and 7.

Discussion

In the experimentally induced hypertensive glaucoma the pathology of both the parvo-, magno- and coniocellular pathways is known [8]. All these pathways are more or less affected. Ganglion cells in the retina are the last ones that encode the color signal. In our previous work we demonstrated that particularly ganglion cells of the




Figure 1: Shows the stimulation by black-white (BW) checked pattern (a) and yellow-blue (YB) checked pattern (b). During the stimulation, the checked pattern was alternated with its inversion at a frequency of 2 Hz.

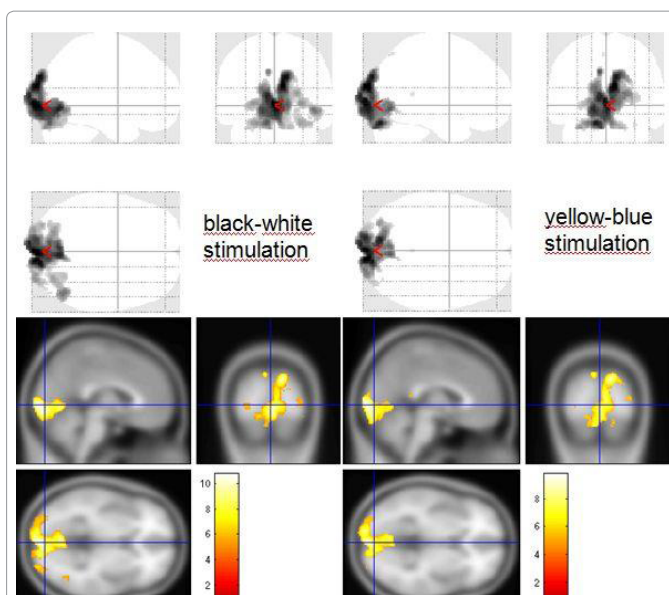


Figure 2: Shows comparison of BW (left column) and YB (right column) stimulation in patient number 6 (in table 1).

Subject	BW	YB	BW>YB	YB>BW	2(BW-YB) (BW+YB)	2(YB-BW) (BW+YB)
Patient 1	10730	8046	1400	0	15%	0%
Patient 2	8732	5767	760	0	10%	0%
Patient 3	10375	5300	610	0	8%	0%
Patient 4	10160	8050	390	0	4%	0%
Patient 5	3732	3200	0	0	0%	0%
Patient 6	5560	4670	0	430	0%	8%
Patient 7	3587	2506	180	0	6%	0%
Patient 8	8130	7650	220	150	3%	2%
Control 1	3800	3200	0	0	0%	0%
Control 2	8300	6600	39	0	1%	0%
Control 3	3900	5800	170	110	4%	2%
Control 4	17700	10600	550	0	4%	0%
Control 5	6900	6900	12	35	0%	1%
Control 6	7750	4550	46	0	1%	0%
Control 7	7150	6980	8	39	0%	1%
Control 8	4200	6200	190	580	4%	11%

Table 1: Shows the range of activations represented by the number of statistically significant voxels during stimulation by the black-white (BW) and yellow-blue (YB) checked patterns. The next two columns show the statistically significant differences between BW and YB stimulations, again expressed by the number of voxels (with tested hypothesis being BW>YB and YB>BW resp.). The last two columns show the percentage difference in the number of activated voxels of the statistical difference.

retina in normotensive glaucoma are relatively spared [2]. In another study, unlike to hypertensive glaucoma, we have not observed any fMRI activity changes in visual area of cerebral cortex [9]. Therefore we have not assumed that there will be a difference in the activity of cerebral cortex at the fMRI examination for BW and YB stimulation in the normotensive glaucoma

There are only few published papers about the examination of color vision perception in normotensive glaucoma. Lachenmayer and Drance investigated the visual functions in hypertensive and normotensive glaucoma cases [5]. They found that hypertensive glaucoma (intra-ocular pressure ≥ 30 mmHg) show highly statistically significant correlations between the low- and high-frequency end of the foveal temporal contrast sensitivity function and foveal and parafoveal blue-on-yellow-sensitivity and the global field indices, whereas in the normal tension glaucoma subgroup no significant correlations were found. The results of the present study support the idea that there are two different mechanisms of glaucomatous damage, one-which is pressure-dependent and one which may be pressure-independent. The pressure-dependent mechanism is responsible for deficits of central or paracentral function which are correlated to overall visual field damage.

Budde et al. [4] examined the color vision perception by means of Farnsworth Munsell100 Hue test and found no difference between hypertensive and normotensive glaucoma.

Polish authors [6] found color vision defect in 57% of eyes with glaucoma (both hypertensive and normotensive one). They also found positive correlation between color vision defect and changes in fields of vision.

Yamagami et al. [10] demonstrated that in normotensive glaucoma, the incidence of blue-yellow abnormalities in the visual field examination was in only 11%, compared with 52% of hypertensive open angle glaucoma, while the mean deviation was the same for both. It is evident from this brief overview that the color vision test results are not unambiguous in normotensive glaucoma.

We used the Lanthony's desaturated 15 Hue test to examine the color vision in our patients. In none of them the color vision defect was confirmed. During the test with Ishihara's pseudoisochromatic plates for color blindness we found the fault in resolution of number 74 in patient's No. 3 and 7.

We know that these tests do not give such results as the anomaloscopy examination. That was not even the purpose of our work. We wanted to demonstrate that the visual cortex in normotensive glaucoma behaves in a different way than in hypertensive glaucoma. We chose for the tests a group of patients with various changes in the field of vision to avoid a potential error in possible color perception defect (pattern defect 1.12-12.65).

Papers dealing with functional magnetic resonance imaging in glaucoma are only a few [11,12]. The authors of both the papers have proved changes in the visual cortex in human glaucoma.

In our previous study [1] we confirmed in patients with various changes in the visual field not only an impairment of the central nervous system (CNS) in hypertensive glaucoma but progress of functional changes in the visual cortex in response to the changes in the ocular fields as well. Information of the use of color stimulation for the fMRI examination is not available in any literature. We used

yellow-blue matrix to stimulate channels processing color stimuli, and the BOLD results compared with black-white structured stimulation (Figure 1).

Blue and yellow colors were chosen deliberately. All the three opponent colors are included (red-green, by mixing of which yellow and yellow-blue colors arise).

In our previous paper we demonstrated in hypertensive glaucoma that the impairment of the visual cortex is greater at stimulation by YB than by BW [3].

Our results show that the visual cortex in normotensive glaucoma behaves similarly like after black-white patterns stimulation. Both these pieces of information show the difference between the defects in normotensive glaucoma and hypertensive glaucoma.

Conclusion

The authors have proved that with advancement of normotensive glaucoma disease, no functional changes in the cerebral visual cortex occur. Even the color stimulation during fMRI has not revealed different changes from the control group. The activity of the visual cortex is in hypertensive glaucoma different from the normotensive one, and this is valid at both BW and YB stimulations.

References

1. Lešták J, Tintera J, Kyncl M, Svatá Z, Obenberger J, et al. (2011) Changes in the Visual Cortex in Patients with High-Tension Glaucoma. *J Clin Exp Ophthalmol*. S4: 002.
2. Lestak J, Nutterova E, Pitrova S, Krejцова H, Bartosova L, et al. (2012) High Tension Versus Normal Tension Glaucoma. A Comparison of Structural and Functional Examinations. *J Clin Exp Ophthalmol*. S5: 006.
3. Lešták J, Tintera J, Kyncl M, Nutterová E, Rozsiva P (2012) Colour Vision Defect in Patients with High-Tension Glaucoma. *J Clin Exp Ophthalmol*.
4. Budde WM, Jünemann A, Korth M (1996) Color axis evaluation of the Farnsworth Munsell 100-hue test in primary open-angle glaucoma and normal-pressure glaucoma. *Graefes Arch Clin Exp Ophthalmol* 234: S180-S186.
5. Lachenmayr BJ, Drance SM (1992) Central function and visual field damage in glaucoma. *Int Ophthalmol* 16: 203-209.
6. Misiuk-Hojlo M, Nizankowska MH, Regiec P, Raczynska K (2004) Clinical advantages of colorimetric exploration in the early diagnosis of glaucomatous neuropathy. *J Fr Ophtalmol* 27: 891-896.
7. Regiec P, Nizankowska MH (1997) Evaluation of acquired color vision defects by means of the two equation method in primary open-angle glaucoma with normal pressure and in patients from the risk group. *Klin Oczna* 99: 245-248.
8. Yücel YH, Zhang Q, Weinreb RN, Kaufman PL, Gupta N (2003) Effects of retinal ganglion cell loss on magno-, parvo-, koniocellular pathways in the lateral geniculate nucleus and visual cortex in glaucoma. *Prog Retin Eye Res* 22: 465-481.
9. Lešták J, Tintera J, Ettler L et al. (2012) Changes in the Visual Cortex in Patients with Normotensive Glaucoma. *J Clin Exp Ophthalmol*. S4: 008.
10. Yamagami J, Koseki N, Araie M (1995) Color vision deficit in normal-tension glaucoma eyes. *Jpn J Ophthalmol* 39: 384-389.
11. Duncan RO, Sample PA, Weinreb RN, Bowd C, Zangwill LM (2007) Retinotopic organization of primary visual cortex in glaucoma: Comparing fMRI measurements of cortical function with visual field loss. *Prog Retin Eye Res* 26: 38-56.
12. Qing G, Zhang S, Wang B, Wang N (2010) Functional MRI signal changes in primary visual cortex corresponding to the central normal visual field of patients with primary open-angle glaucoma. *Invest Ophthalmol Vis Sci* 51: 4627-4634.