

Atrial Fibrillation Due to Bee Sting

Salih Sahinkus^{1*}, Sinan Demirel¹, Altug Ösken², Huseyin Gunduz¹ and Ramazan Akdemir¹

¹Department of Cardiology, Sakarya University, Serdivan, Turkey

²Siyami Ersek Education and Research Hospital, Istanbul, Turkey

*Corresponding author: Salih Sahinkus, Department of Cardiology, Sakarya University, Serdivan, Turkey, Tel: +90 5064713599; E-mail: drsalihahinkus@gmail.com

Received date: June 28, 2017; Accepted date: August 24, 2017; Published date: August 31, 2017

Copyright: © 2017 Sahinkus S, et al. This is an open-access article distributed under the terms of the Creative Commons Attribution License, which permits unrestricted use, distribution, and reproduction in any medium, provided the original author and source are credited.

Abstract

Atrial fibrillation (AF) is a tachyarrhythmia that may result from many causes such as hypertension, heart failure, valvular diseases, atherosclerosis, aging and obesity. Anaphylactic reactions as resulting after a bee sting is a very rare etiology of AF. Bee venom components such as melitin, dopamin and norepinephrine activates some vascular and inflammatory events that resulting problems in the electrical system of the heart. We report a case of a patient with new onset AF after a bee sting, who had no cardiovascular disease and cardiac symptoms before.

Keywords: Hypotension; Electrocardiography; Arrhythmias; Dopamine

Introduction

Bee sting can cause anaphylactic reactions. As a result of this, cardiovascular, neurological and nephrological systems can be affected from the poisoning. Resulting problems about cardiovascular system are Kounis syndrome, bradyarrhythmias, tachyarrhythmias, hypotension and sudden cardiac death. AF is arrhythmia that endothelial, vascular, ion channel, extracellular matrix pathologies and sympathetic hyperinnervation are involved in the pathophysiology. Bee venom may lead to atrial fibrillation by these pathophysiological pathways, especially with dopamine and norepinephrine components. AF increases risk of death by two times and risk of stroke by five times, especially in the elderly patients.

Case Report

A 55 year-old male patient admitted to the emergency ward at the hospital with complaints of tachycardia and syncope after a bee sting an hour ago. He was a smoker and he did not have any significant past medical history like hypertension, diabetes mellitus or atherosclerosis. His blood pressure was 80/60 mmHg, his heart rate was 104 bpm and the pulse was irregular. Diffuse urticarial rash and transpiration were identified. Heart sounds were arrhythmic and heart murmurs were not realized. Neurological and respiratory systems examinations were normal. His electrocardiography (ECG) represented AF (Figure 1). As the patient did not have known arrhythmia in the beginning and complaints started after a bee sting, anti-anaphylactic treatment rather than antiarrhythmic treatment seemed appropriate. After that intravenous pheniramine 45.5 mg and prednisolone 60 mg were administered to the patient in the emergency department. Nearly one hour later his blood pressure was increased up to 120/75 mmHg and sinus rhythm was carried out (Figure 2). No pathological findings were found in the blood samples. His arrhythmia was straightened spontaneously after anti-allergic treatment without anti-arrhythmic treatment.

He was interned to the cardiology clinic. There was no symptom during follow-up at the clinic. There was not any pathological sign in his transthoracic echocardiography.

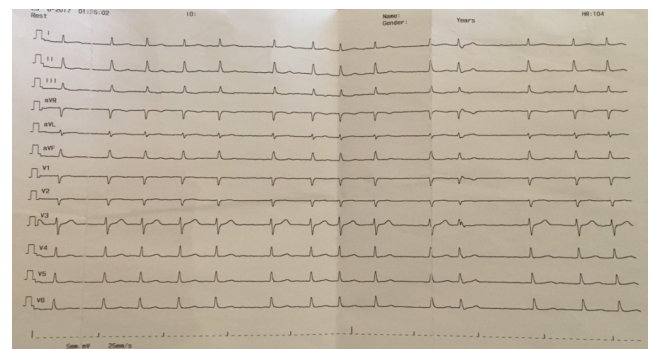


Figure 1: ECG represent AF (irregular R-R intervals and no distinct P waves) after bee sting.

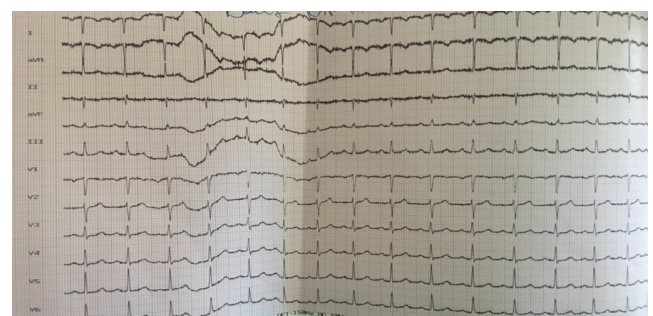


Figure 2: Sinus rhythm ECG post-antiallergic treatment (regular P-P, P-R, R-R intervals).

He had no arrhythmia on the 24-h holter monitoring. It was thought that the arrhythmic pattern that the patient had experienced in these clinical findings was secondary to the anaphylactic reaction.

We cannot prove it but there is no other clinical data that will lead to this situation. And as a result, he was discharged without any symptom or clinical evidence. No cardiac symptoms and signs were detected, especially palpitation, in the cardiology outpatient clinic follow-up.

Discussion

Bee stings can cause severe allergic reactions. Hypotension, arrhythmias, myocardial infarction can occur due to the contents of the bee venom such as; melitin, dopamine, norepinephrine, apamin, histamine, phospholipase A2, thromboxanes and leukotriens [1,2]. Association between dopamine and new onset AF was reported before [3]. Previously reported that, kidney injury, acute ischemic stroke and multiorgan dysfunctions ensued from poisoning effects of the bee venom [1,4]. Heart blocks and myocardial infarctions have reported due to the bee sting but as in our case AF is a very rare complication of the bee sting [2].

AF is a arrhythmia that one of the major common cause of the stroke, heart failure and sudden death. Also hospitalization, cognitive decline and vascular dementia prevalence were increased and left ventricular function, quality of life were reduced in the patients with AF [5]. By the downregulation of the Ca²⁺ inward current and upregulation of inward rectifier K⁺ currents, AF provokes a shortening of the atrial refractory period and AF cycle length. Enhanced spontaneous Ca²⁺ release events and triggered activity, thus causing ectopy and resulting as AF [6]. Norepinephrine and dopamine may provoke AF by these ion channel changes and Ca²⁺ instability. There are three treatment strategies in the AF; rate control, rhythm control

and anticoagulation. Patients who are in atrial fibrillation less than 48 hours, can be safely cardioverted.

Conclusion

Bee sting can be a serious problem for the bitten patient and it can cause severe systemic complications. Not only urticaria but also cardiological and neurological problems such as arrhythmias, myocardial infarction, cardiogenic shock and sudden cardiac death can be occurring. The patient who have bitten by bees, have to be evaluated and examined systematically.

References

1. Silva GDB, Vasconcelos AG, Rocha AMT (2017) Acute kidney injury complicating bee stings- a review. *Rev Inst Med Trop Sao Paulo* 59: 25.
2. Kahraman F, Ozaydin M, Varol E (2014) Acute stent thrombosis and/or atrial fibrillation occurring after bee sting. *Blood Koagulation and Fibrinolysis* 25: 387-388.
3. Argaliou M, Motta P, Khandwala F, Samuel S, Koch CG, et al. (2015) Renal dose dopamine is associated with the risk of new-onset atrial fibrillation after cardiac surgery. *Crit Care Med* 33: 1327-1332.
4. Guzel M, Akar H, Erenler AK (2016) Acute ischemic stroke and severe multiorgan dysfunction due to multiple bee stings. *Turkish Turk J Emerg Med* 16: 126-128
5. ESC Guidelines for the management of atrial fibrillation (2016).
6. Voigt N, Heijman J, Wang Q, Chiang DY, Li N, et al. (2014) Cellular and molecular mechanisms of atrial arrhythmogenesis in patients with paroxysmal atrial fibrillation. *Circulation* 129: 145-156.