

## A Study on Ovarian Dermoid in Adolescents and Young Women

Annie Racheal EV\*

Department of Molecular Biology, Jahangirnagar University, Dhaka, Bangladesh

### ABSTRACT

A dermoid cyst is a sac like growth that is present at birth. It contains structures such as hair, skin glands fluid, teeth etc. Dermoid cyst grows slowly. Dermoid cyst usually occurs on the face, inside the skull, lower back and in the ovaries. Proper management of dermoid cyst should be done after it is been diagnosed otherwise it may challenge the sexual development and fertility.

**Keywords:** Dermoid cyst; Ovarian dermoid; Skin glands fluid; Fertility

### INTRODUCTION

Dermoid cyst commonly known as Mature Cystic Teratomas (MCTs) are commonly found in women between age 20 and 40 years. Dermoid cysts are benign (not cancer) and tend to grow slowly. Dermoid cyst are a type of germ cell tumor [1]. The exact reason of dermoid cyst in young women population is unknown, and it is diagnosed accidentally because pelvic imaging is not routinely performed in these groups. Dermoid cysts are asymptomatic and in many case it will not affect the menstrual cycle. Dermoid cysts are considered to be congenital, but not all of them are diagnosed at birth only about 40% of dermoid cysts are diagnosed at birth [2]. while about 60% of the dermoid cyst is diagnosed during the later period of life. The cause of the congenital developmental anomaly has yet to be determined. Dermoid cyst occurs when skin become trapped during the fetal development [3]. A dermoid cyst is an enclosed sac near the surface of the skin that forms during a baby's development in the uterus [4]. Dermoid cyst contains glands that produce sweat

and skin oil. The glands continue to produce these substances, causing cyst to grow. Even though dermoid cysts are harmless malignant transformation on occur. Ovarian torsion rupture and spillage of sebaceous contents bowel obstruction on occur rarely.

### CASE PRESENTATION

The case taken for the analysis was of a 27 year's old unmarried girl who was diagnosed with hypo echoic lesion measuring  $9.8 \times 8.1$  with solid compounds measuring  $5.5 \text{ cm} \times 3.7 \text{ cm}$ . There was no evidence of increased vascularity MRI examination revealed left ovarian cystic lesion showing possible adhesion with posterior wall of uterus and right ovary, left ovary not seen separately correlate with biomarkers. MRI also revealed a history of dilated tubular structure with possible adhesion with left ovarian cystic lesion likely to be hemato salpinx (Figures 1 and 2).

**Correspondence to:** Annie Racheal EV, Department of Molecular Biology, Jahangirnagar University, Dhaka, Bangladesh, Tel: 7025795841; E-mail: rachealcyril20@gmail.com

**Received:** 01-Apr-2022, Manuscript No. GOCR-22-18559; **Editor assigned:** 03-Apr-2022, PreQC No. GOCR-22-18559 (PQ); **Reviewed:** 16-Apr-2022, QC No. GOCR-22-18559; **Revised:** 20-Apr-2022, Manuscript No. GOCR-22-18559 (R); **Published:** 28-Apr-2022, DOI: 10.35248/2161-0932.22.12.598

**Citation:** Racheal AEV (2022) A Study on Ovarian Dermoid in Adolescents and Young Women. Gynecol Obstet. 12:598.

**Copyright:** © 2022 Racheal AEV. This is an open-access article distributed under the terms of the Creative Commons Attribution License, which permits unrestricted use, distribution, and reproduction in any medium, provided the original author and source are credited.

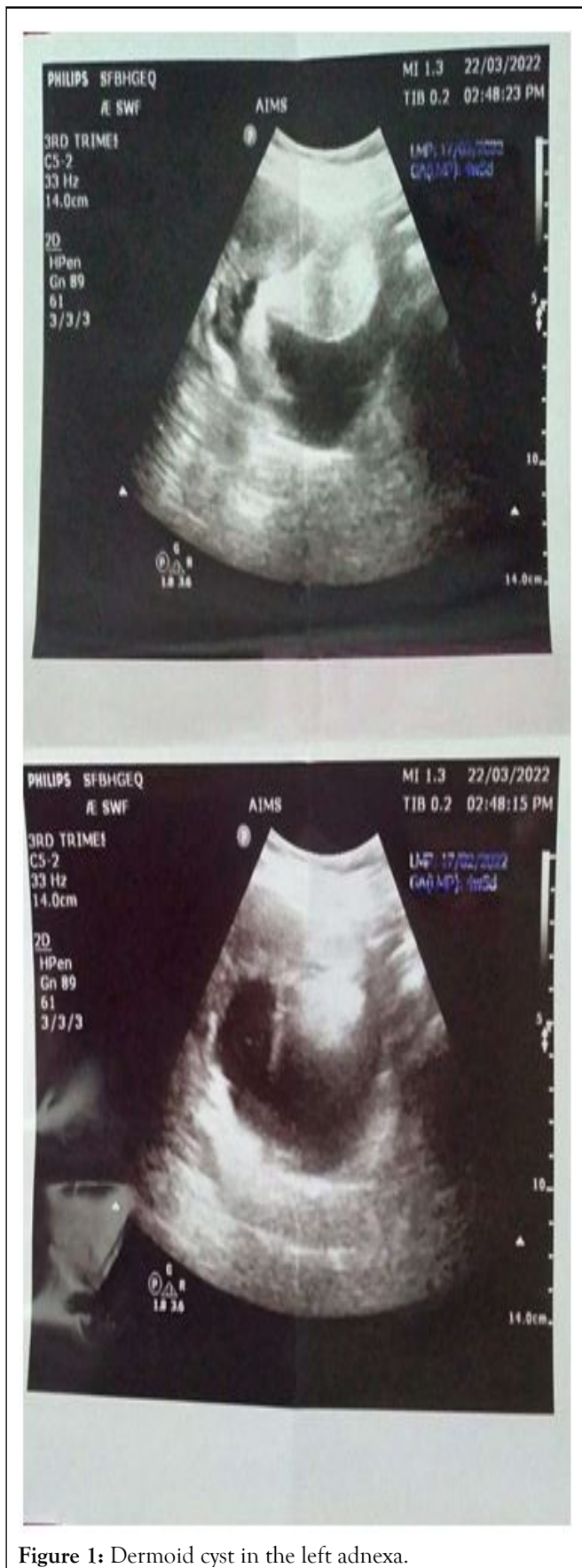


Figure 1: Dermoid cyst in the left adnexa.

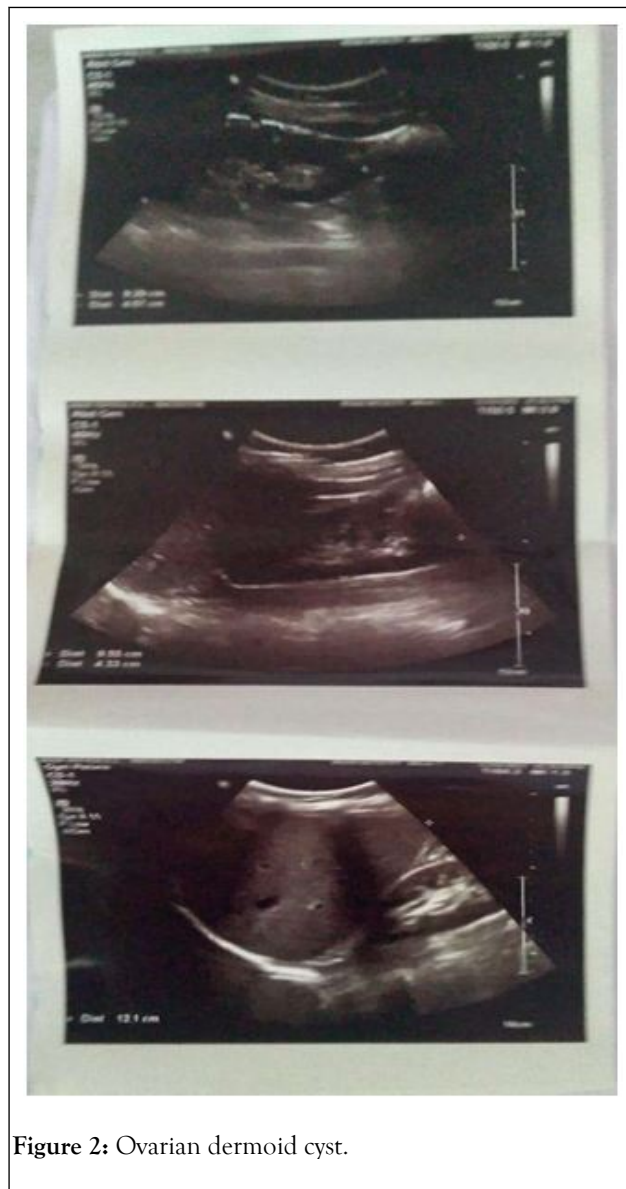

Figure 2: Ovarian dermoid cyst.

### Treatment management

Dermoid cyst usually tend to grow slowly, the presence of a small asymptomatic dermoid cyst may not necessitate immediate excision as it can be stable for years [5]. However complete surgical excision without disruption of the cyst wall by an experienced surgeon is necessary in order to avoid complications. An additional advantage of surgical excision is possibility of obtaining a histological pathology. In order to diagnose a malignancy. Another benefit of early removal of dermoid cyst is to reduce risk of recurrence [6]. For small dermoid cyst endoscopic surgery can be dependent, in cases of a large dermoid cyst laparotomy or laparoscopy is required [7].

### Complications

Even though dermoid cyst is usually harmless untreated dermoid cysts over time may cause complications, especially if they grow, complication can include:

- Damage to nearby tissues and cells.

- Infection.
- Rupture of the cyst.
- Twisting of the ovaries (ovarian torsion).
- Probability of malignancy in dermoid cyst is the most common solid type tumor and the most common ovarian mass occurs at young age. Mature cystic teratomas with malignant degeneration occur. When somatic malignant transformation happens.

### Dermoid cyst management

**Laparotomy:** Laparotomy is usually recommended to the patients with above 10 centimeters tumor size if there is evidence of solid components in the tumor mass and a suspicion of malignancy laparotomy is recommended.

**Bilateral cyst:** It is important in women older than 40 years to send specimens to the frozen section in case of suspicious sonographic findings and high tumor markers. Laproscopy procedure for exteriorization of a dermoid cyst. One method of retrieval of a dermoid cyst is *via* the umbilical port under the bag contents of a low mass cyst can be extracted by suction and traction by forceps [8]. Removal of the cyst through lateral ports or an extended incision might increase post-operative time and take more recovery time.

### Selection of oophorectomy or cystectomy

Cystectomy is considered as dermoid cyst surgery of choice instead of oophorectomy. It has been indicted that each 1 mm<sup>2</sup> of ovarian surface includes about 35 primordial follicles in women in the age range of 11-34 years cystectomy is the first choice in the case of children and younger women. However oophorectomy is the standard procedure in post-menopausal women.

Oophorectomy is recommended as treatment when there are multiple dermoid cysts in the ovary, large dermoid cyst resulting in less ovarian tissue for conservation closeness to menopause in the patient [10-13].

However ovarian tissues be more preserved in cystectomy in young women and children preservation of ovarian tissues is important for fertility and future sexual development.

The techniques listed below are suggested for maximum preservation of ovarian tissue [14-18].

- A combination of hydro dissection and blunt dissection by laparoscopy instead of the traditional stripping technique.
- The mesial side of ovary is the point of connection of fimbria to ovary. Studies have revealed mesial side incision to better preserve ovarian function.

Summarized advantages of mesial side ovarian incision are as follows:

- Second, thin band like echo in the cyst (dermoid mesh) which represents floating hair inside the cyst.
- Third, tip of the iceberg sign resulting from acoustic shadowing of the sebum on hair content of the cyst; and
- Fourth, fat-fluid level.

- Negative color doppler sonography, indicating low velocity and high resistance.
- Small sized dermoid cyst has been considered in most studies below 6 centimeters as small. There is less torsion in a smaller sized cyst in comparison with a large cyst; there is also lower rate of malignancy and lower growth rate.
- Slow growth rate annually is less than 2 centimeters. Every year about 1.5 mm to 1.7 mm growth rate is possible. The growth rate is close to zero in post menopause. In women of reproductive age, there is higher growth rate, probably due to the effect of hormones on sebaceous glands.
- Negative tumor markers.
- Asymptomatic condition.
- Children (in prepubertal stage) and adolescents due to sexual development and fertility preservation goals, follow up in strongly considered.
- Pregnancy.

### CONCLUSION

Medical co-morbidity with high probability of operative complications. There is a lack of data based evidence to formulate guidelines for intervention or expectant management. Risk of malignancy is below 1%. There is logical comparison between conservative management of myoma with below 1% malignancy rate and expectant management of dermoid cysts.

### REFERENCES

1. Rahma A, Mardiyana L, Farzish D. Malignant struma ovarii: Case report of an unusual ovarian tumor with CT imaging. *Radiol Case Rep.* 2022;17(5):1705-1708.
2. Krohn KA. Sonographic evaluation of serous cystadenofibroma with evidence of intermittent torsion. *J Diagn Med Sonogr.* 2021;37(3):283-289.
3. Stefan P, Lupean R, Mihu CM, Lebovici A, Oancea Md, Hiru L, et al. Ultrasonography In the diagnosis of adnexal lesions: The role of texture analysis. *Diagnostics.* 2021;11(5):812.
4. Zheng X, Lyu G, Shen X, Hu M. Ultrasound characteristics of cystadenofibromas. *Ultrasound Q.* 2021;37(4):49-356.
5. Virgilio B, Blasis LD, Sladkevicius P, Maro F, Zannoni GF, Arciuolo D, et al. Imaging in gynecological disease (16): Clinical and ultrasound characteristics of serous cystadenofibromas in adnexa. *Ultrasound Obstet Gynecol.* 2019; 54(6):823-830.
6. Tritsch TIE, Yoon E, Monteagudo A, Ciaffarano J, Brandson C, Mittal KR, et al. Ultrasound and histopathologic correlation of ovarian cystadenofibromas: Diagnostic value of the "shadow sign". *J Ultrasound Med.* 2019;38(11):2973-2978.
7. Baheti AD, Lewis CE, Hippee DS, Malley RB, Wang CL. Imaging characterization of adnexal lesions: Do CT findings correlate with US. *Abdom Radiol.* 2018;43(7):1764-1771.
8. Shin HJ, Ah K, Back-hui Kim, Lee JK, Park YS, Lee J, et al. Benign enhancing components of mature ovarian teratoma: Magnetic resonance imaging features and pathologic correlation. *Clin Imaging.* 2016;40(6):1156-1161.

9. Mansour S, Wessam R, Raafat M. Daiffusion-weighted magnetic resonance imaging in the assessment of ovarian masses with suspicious features: Strengths and challenges. *Egypt J Radiol Nucl Med.* 2015;46(4):1279-1289.
10. Forstner R, Meissnitzer T, Meissnitzer M. Benign lesions that mimic cancer: Ovarian. *Cancer Imaging.* 2015;15:S1.
11. Mansour SM, Saraya S, El-faissal Y. Semi-quantitative contrast-enhanced MR analysis of indeterminate ovarian rumours: When to say malignancy. *Br J Radiol.* 2015;88(1053):20150099.
12. Huang DQ. Classic mature cystic teratoma of the ovary in a 17 year-old adolescent girl. *Ultrasound Quarterly.* 2015;31(3):230-231.
13. Coudray AJ, Jacquemier J, Mahjoub RV, Delarbre B, Thomassin-Piana J. Why is macroscopy essential to understand and analyze ovarian tumors?. *Imagery of the Woman.* 2015;25(2):122-149.
14. Acharya UR, Vinitha Sree S, Kulshreshtha S, Molinari F, Koh JEW, Saba L, et al. GyneScan: An improved online paradigm for screening of ovarian cancer via tissue characterization. *Technol Cancer Res Treat.* 2014;13(6):529-539.
15. Goldstein SR, Monteagudo I, Monda S, Popiolek D. Cystadenofibromas: Can transvaginal ultrasound appearance reduce some surgical interventions. *J Clin Ultrasound.* 2015;43(6):393-396.
16. Shaaban AM, Rezvani M, Elsayes KM, Baskin H, Mourad A, Foster BR, et al. Ovarian malignant germ cell tumors: Cellular classification and clinical and imaging features. *Radiographics.* 2014;34(3):777-801.
17. Cox KL, Baumgarten D, Mittal P. MR findings in cystic ovarian tumors. *Contemp Diagn Radiol.* 2014;37(6):1-5.
18. Tsuboyama T, Tatsumi M, Onishi H, Nakamoto A, Kim T, Hori M, et al. Assessment of combination of contrast-enhanced magnetic resonance imaging and positron emission tomography/computed tomography for evaluation of ovarian masses. *Invest Radiol.* 2014;49(8):524-31.